This is a digital copy of a book that was preserved for generations on library shelves before it was carefully scanned by Google as part of a project to make the world's books discoverable online.

It has survived long enough for the copyright to expire and the book to enter the public domain. A public domain book is one that was never subject to copyright or whose legal copyright term has expired. Whether a book is in the public domain may vary country to country. Public domain books are our gateways to the past, representing a wealth of history, culture and knowledge that's often difficult to discover.

Marks, notations and other marginalia present in the original volume will appear in this file - a reminder of this book's long journey from the publisher to a library and finally to you.

Usage guidelines

Google is proud to partner with libraries to digitize public domain materials and make them widely accessible. Public domain books belong to the public and we are merely their custodians. Nevertheless, this work is expensive, so in order to keep providing this resource, we have taken steps to prevent abuse by commercial parties, including placing technical restrictions on automated querying.

We also ask that you:

+ *Make non-commercial use of the files* We designed Google Book Search for use by individuals, and we request that you use these files for personal, non-commercial purposes.

+ *Refrain from automated querying* Do not send automated queries of any sort to Google's system: If you are conducting research on machine translation, optical character recognition or other areas where access to a large amount of text is helpful, please contact us. We encourage the use of public domain materials for these purposes and may be able to help.

+ *Maintain attribution* The Google "watermark" you see on each file is essential for informing people about this project and helping them find additional materials through Google Book Search. Please do not remove it.

+ *Keep it legal* Whatever your use, remember that you are responsible for ensuring that what you are doing is legal. Do not assume that just because we believe a book is in the public domain for users in the United States, that the work is also in the public domain for users in other countries. Whether a book is still in copyright varies from country to country, and we can't offer guidance on whether any specific use of any specific book is allowed. Please do not assume that a book's appearance in Google Book Search means it can be used in any manner anywhere in the world. Copyright infringement liability can be quite severe.

About Google Book Search

Google's mission is to organize the world's information and to make it universally accessible and useful. Google Book Search helps readers discover the world's books while helping authors and publishers reach new audiences. You can search through the full text of this book on the web at `http://books.google.com/`

No.

BOSTON
MEDICAL LIBRARY
ASSOCIATION,
19 BOYLSTON PLACE.

TRANSACTIONS

OF

THE CLINICAL SOCIETY.

VOL. XXVI.

TRANSACTIONS

OF

THE CLINICAL SOCIETY

OF

LONDON.

VOLUME THE TWENTY-SIXTH.

BOSTON MEDICAL LIBRARY ASS'N.
NOV 15 1893

LONDON:

LONGMANS, GREEN, AND CO.

1893.

CATALOGUED.
J. F. B.
11.15.1893

PRINTED BY ADLARD AND SON,
BARTHOLOMEW CLOSE, E.C., AND 20, HANOVER SQUARE, W.

NOTICE.

THE present Volume comprises the Proceedings of the Society during its Twenty-sixth Session, October, 1892, to May, 1893.

The Council think it proper to state that the authors of the several communications are alone responsible for the statements, reasonings, and opinions contained in their respective papers.

20, HANOVER SQUARE, W.;
August, 1893.

CONTENTS.

PAGE

NOTICE FROM THE COUNCIL v

LIST OF ILLUSTRATIONS . . . . . xv, xvi

LIST OF OFFICERS AND MEMBERS OF THE COUNCIL DURING 1892 xvii

LIST OF PRESIDENTS OF THE SOCIETY FROM ITS FORMATION . xviii

LIST OF HONORARY MEMBERS OF THE SOCIETY . . xix, xx

LIST OF MEMBERS OF THE SOCIETY xxi

REPORT OF THE COUNCIL xlv

BALANCE SHEET xlvii

COMMUNICATIONS:—

I. A CASE OF INTESTINAL OBSTRUCTION ACCOMPANIED BY THROMBUS IN THE ABDOMINAL AORTA EXTENDING DOWN THE ILIAC VESSELS. By W. H. BROWN 1

II. A CASE OF EXTENSIVE NÆVUS OF THE PERITONEUM. By W. ARBUTHNOT LANE, M.S. . 5

III. A CASE OF TRAUMATIC ANEURYSM OF THE EXTERNAL ILIAC ARTERY IN A BOY SIX YEARS OF AGE. By H. H. CLUTTON 7

PAGE

IV. A case of Cicatricial Stricture of Œsophagus: œsophagotomy for removal of impacted Symonds' tube: complete division of stricture: no recurrence two years after operation. By Frederic Eve . . 11

V. Two cases illustrative of an operation of Complete Erasion of the Ankle-joint. By W. Arbuthnot Lane, M.S. . . . 15

VI. The conditions seen at an operation for Ventral Hernia, five and a half years after laparotomy for tubercular peritonitis. By R. Lawford Knaggs, M.C. . 18

VII. A case of Hyperplastic (obliterating) Phlebitis or Phlebo-sclerosis affecting the larger veins. By H. Handford, M.D. 20

VIII. A case of Nephrolithotomy: large calculus. By Donald D. Day (introduced by Howard Marsh) 24

IX. A case of Double Empyema: simultaneous drainage of the pleural cavities: recovery. By J. Walter Carr, M.D. . . 29

X. A case of Pancreatic Cyst; exploratory laparotomy: enucleation impracticable: death from shock. By J. W. Hulke, F.R.S. 36

XI. Excision of a Cancerous Stricture of the Small Intestine, from a case of complete obstruction of seventeen days' duration. By Arthur Roper, M.D., and W. Arbuthnot Lane, M.S. 40

PAGE

XII. A case of Subacute Œdema of Lung occurring above a diminishing pleural effusion. By James Calvert, M.D. 43

XIII. A case of Axial Rotation of a Wandering Spleen: splenectomy: recovery. By J. Bland Sutton 46

XIV. A case of Hemiplegia in Typhoid Fever associated with Aphasia: hæmorrhage from the bowels and purpura. By Francis Hawkins, M.B. 50

XV. A case of Rhinolith. By F. de Havilland Hall, M.D. 60

XVI. A case of Inherited Gout, with production of tophi at an early age. By Sir Dyce Duckworth 68

XVII. A case of Uratic Deposit in the Conjunctival Membrane. By T. D. Pryce (introduced by Sir Dyce Duckworth) . . . 70

XVIII. Cases of Abscess beneath the Diaphragm in connection with Perforating Gastric Ulcer. By F. G. Penrose, M.D., and Lee Dickinson, M.B. 72

XIX. A case illustrating a more effectual method of removing a Cancerous Breast, Lymphatics, and Glands. By W. Arbuthnot Lane, M.S. 85

XX. On the relative merits of a vertical and of a transverse incision in Supra-pubic Cystotomy. With Cases. By Robert William Parker 88

PAGE

XXI. Subserous Uterine Hæmatocele, in a girl of eleven years, simulating acute inflammation of the vermiform appendix. Laparotomy. Recovery. By Arthur E. Barker 97

XXII. A case of Lipoma of the Broad Ligament. By Frederick Treves 101

XXIII. A case of Diaphragmatic Hernia, in which Death was caused by Vomiting. By C. D. B. Hale, M.D., and J. F. Goodhart, M.D. 105

XXIV. Two cases of Generalised Vaccinia. By T. Colcott Fox, M.B. 108

XXV. A case of Generalised Vaccinia. By T. D. Acland, M.D., and C. H. Fisher, M.D. . 114

XXVI. Cases illustrating a new Operation for Dorsal Dislocation of the Head of the Femur and some points in the Surgery of the Hip-joint. By W. Arbuthnot Lane, M.S. 118

XXVII. Sequel to a case of Excision of the Head of the Femur and Erasion of the Hip-joint through the anterior incision, and with immediate and permanent closure of the wound. By Charles Barrett Lockwood . 125

XXVIII. A note on the prognosis in cases of Sacro-iliac Disease. By G. H. Makins . . 127

XXIX. Lympho-sarcoma of Tonsil: removal by external incision, with preliminary ligature of the external carotid artery. By Raymond Johnson, M.B., B.S. . . . 136

PAGE

XXX. Intestinal Obstruction of six weeks' duration: inguinal colotomy: removal of malignant growth from the inguinal incision: recovery. By Herbert Allingham 140

XXXI. Two exceptional cases of Peripheral Neuritis, one septicæmic, the other due to lead, and presenting unilateral facial paralysis and other rare symptoms. By W. Hale White, M.D. 143

XXXII. Infusion (or Transfusion) of normal Saline Solution in severe Shock. By A. W. Mayo Robson 154

XXXIII. Gastro-enterostomy for Cancer of Pyloric end of Stomach. By Herbert Allingham . 158

XXXIV. A Sequel to some cases showing Hereditary Enlargement of the Spleen. By Claude Wilson, M.D., and Douglas Stanley, M.B. . 163

XXXV. A Case of Psoas Abscesses, fatal through Renal Complications. By F. Lucas Benham, M.D. 172

XXXVI. On a bloodless method of removing the Tongue. By Christopher Heath . . 177

XXXVII. A case of Perforating Gastric Ulcer treated by abdominal section. By W. Lee Dickinson, M.D., and Warrington Haward 179

XXXVIII. A case of Pulmonary Abscess communicating with the Posterior Mediastinum. By Alexander Morison, M.D. 189

PAGE

XXXIX. A CASE OF EXCISION OF THE CÆCUM, IN WHICH TWO ENDS OF THE DIVIDED BOWEL WERE SUCCESSFULLY UNITED BY A CONTINUOUS SILK SUTURE. By W. BRUCE CLARKE . . . 200

XL. CASE OF PSEUDO-BULBAR PARALYSIS, PROBABLY DUE TO A LESION IN EACH CEREBRAL HEMISPHERE. By G. NEWTON PITT . . . 204

XLI. INTESTINAL OBSTRUCTION FROM GALL-STONE. By ROBERT NAIRN (introduced by the PRESIDENT) 211

XLII. A CASE OF ULCERATIVE COLITIS TREATED BY INGUINAL COLOTOMY AND LOCAL TREATMENT OF THE ULCERATED SURFACES, WITH SUBSEQUENT CLOSURE OF THE ARTIFICIAL ANUS. By MAYO ROBSON 213

XLIII. TWO CASES OF CHRONIC ALBUMINURIA, ONE OF TWENTY-FIVE YEARS AND THE OTHER OF FORTY-THREE YEARS' DURATION: REMARKS ON CHRONIC ALBUMINURIA. By FRANCIS HAWKINS, M.B. . 216

LIVING SPECIMENS—DESCRIBED BY CARD:

I. A CASE OF MACROCHEILIA SUCCESSFULLY TREATED BY ELECTROLYSIS. By W. ARBUTHNOT LANE 223

II. A CASE OF FRACTURE OF PATELLA TREATED BY BARKER'S METHOD: BONY UNION. By HERBERT W. PAGE 224

III. A CASE OF CONGENITAL DEFICIENCY OF CHEST WALL. By JOHN ABERCROMBIE, M.D. . . 225

IV. A CASE OF SINUS IN LEFT LOIN COMMUNICATING WITH AN ABSCESS CAVITY IN THE POSTERIOR MEDIASTINUM. By WALTER G. SPENCER, M.D. 226

PAGE

V. A case of Extensive Fracture of right upper Maxilla. By Storer Bennett . . . 226

VI. A case of Rhythmical Rocking Movements in a child. By W. B. Hadden, M.D. . . 227

VII. A case of Rhythmical Movements of the lower Limbs in a child. By W. B. Hadden, M.D. 228

VIII. A case of Loose Body in the Elbow-joint, probably the separated capitellar epiphysis of the Humerus. By L. A. Dunn . 228

IX. A case of Myxœdema, treated with raw thyroid glands and fresh thyroid extract, in which severe constitutional symptoms developed under treatment. By W. Pasteur, M.D. 230

X. A case of Myxœdema in a Male, treated by dried thyroid extract given by the mouth. By Arthur T. Davies, M.D. 234

XI. A case of Myxœdema treated by giving the dried thyroid extract by the mouth. By Arthur T. Davies, M.D. 236

XII. A case of Myxœdema treated with the fried thyroids of sheep. By James Calvert, M.D. 237

XIII. Extroversion of Meckel's Diverticulum. By William H. Battle 237

XIV. Dermatological case for diagnosis. By A. H. Weiss Clemow, M.D. 239

XV. Syphilitic Stenosis of Larynx treated by excision of one vocal cord. By Ewen C. Stabb 239

PAGE

XVI. Case of Partial Excision of Larynx for Myxochondroma: patient wears an artificial larynx without reed and speaks well. By J. W. Bond 240

XVII. Rheumatic Inflammation of Sheaths of Tendons and of Finger-joints. By F. R. Walters, M.D. 241

XVIII. Case of Total Ablation of Scapula for Sarcoma. Patient shown thirty-one days after operation. By C. H. Golding-Bird . 242

XIX. A Case of Nævus involving the whole of the right side. By J. Fletcher Little, M.B. 243

Valedictory Address. By Sir Dyce Duckworth, M.D., LL.D. 247

Appendix to Dr. Newton Pitt's Paper on Pseudo-bulbar Paralysis, giving the post-mortem appearances 250

INDEX 255

LIST OF ILLUSTRATIONS.

PLATES.

PAGE

I. PHOTO-TYPOGRAPH. A CASE OF NEPHROLITHOTOMY: LARGE CALCULUS. MR. DONALD D. DAY . . . 26

II. CHROMO-LITHOGRAPH. A CASE OF GENERALISED VACCINIA. DR. T. D. ACLAND AND DR. C. H. FISHER 114

III. CHROMO-LITHOGRAPH. A CASE OF NÆVUS INVOLVING THE WHOLE OF THE RIGHT SIDE. DR. J. FLETCHER LITTLE 244

WOODCUTS.

PAGE

FIGS. 1, 2. OPERATION FOR DORSAL DISLOCATION OF HEAD OF FEMUR. W. ARBUTHNOT LANE, M.S. . . 124

FIGS. 3—5. RARE PERIPHERAL NEURITIS. W. HALE WHITE, M.D. . . . . 149—151

FIG. 6. BLOODLESS METHOD OF REMOVING THE TONGUE. CHRISTOPHER HEATH 177

FIGS. 7, 8. PERFORATING GASTRIC ULCER. W. LEE DICKINSON, M.B., AND WARRINGTON HAWARD . . 179

FIGS. 9—12. PULMONARY ABSCESS COMMUNICATING WITH THE POSTERIOR MEDIASTINUM. ALEXANDER MORISON, M.D. . . . . 191—198

FIGS. 13, 14. MYXŒDEMA. W. PASTEUR, M.D. . 230, 231

FIG. 15. NÆVUS. J. FLETCHER LITTLE, M.B. . . . 244

CLINICAL SOCIETY OF LONDON.

OFFICERS AND COUNCIL

ELECTED AT

THE GENERAL MEETING, MAY 26, 1893.

PRESIDENT.

JOHN WHITAKER HULKE, F.R.S.

VICE-PRESIDENTS.

H. CHARLTON BASTIAN, M.D., F.R.S.
ALFRED B. DUFFIN, M.D.
SIR GEORGE BUCHANAN, M.D., F.R.S.
J. G. GLOVER, M.D.
JOHN LANGTON.
ROBERT WILLIAM PARKER.

TREASURER.

WILLIAM MILLER ORD, M.D.

COUNCIL.

THOMAS BARLOW, M.D.
W. H. DAY, M.D.
HENRY HANDFORD, M.D.
DONALD WILLIAM C. HOOD, M.D.
T. RIDGE JONES, M.D.
H. MONTAGUE MURRAY, M.D.
A. T. MYERS, M.D.
WILLIAM PASTEUR, M.D.
SIDNEY PHILLIPS, M.D.
DAWSON WILLIAMS, M.D.
FREDERICK ROBERTS, M.D.
WILLIAM ANDERSON.
WILLIAM HENRY BENNETT.
ANTHONY A. BOWLBY.
GEORGE BUCKSTON BROWNE.
W. ARBUTHNOT LANE, M.S.
G. H. MAKINS.
BERNARD PITTS, M.C.
A. W. MAYO ROBSON.
FREDERICK TREVES.

HONORARY SECRETARIES.

WILLIAM HALE WHITE, M.D. (June 1893).
A. PEARCE GOULD, M.S.

TRUSTEES.

CHRISTOPHER HEATH.
WILLIAM MILLER ORD, M.D.
J. BURDON SANDERSON, M.D., F.R.S.

PRESIDENTS OF THE SOCIETY

(*From its Formation*).

ELECTED

1867 SIR THOMAS WATSON, BART., M.D., D.C.L., LL.D., F.R.S.

1869 SIR JAMES PAGET, BART., D.C.L., LL.D., F.R.S.

1871 SIR WILLIAM WITHEY GULL, BART., M.D., D.C.L., F.R.S.

1873 SIR PRESCOTT GARDNER HEWETT, BART., F.R.S.

1875 SIR WILLIAM JENNER, BART., M.D., K.G.C.B., D.C.L., F.R.S.

1877 GEORGE WILLIAM CALLENDER, F.R.S.

1879 EDWARD HEADLAM GREENHOW, M.D., F.R.S.

1881 SIR JOSEPH LISTER, BART., D.C.L., LL.D., F.R.S.

1883 SIR ANDREW CLARK, BART., M.D., LL.D., F.R.S.

1885 THOMAS BRYANT.

1887 WILLIAM HENRY BROADBENT, M.D.

1889 CHRISTOPHER HEATH.

1891 SIR DYCE DUCKWORTH, M.D., LL.D.

1893 JOHN WHITAKER HULKE, F.R.S.

HONORARY MEMBERS.

ELECTED

1881 PAGET, SIR JAMES, Bart., D.C.L., LL.D., F.R.S., 5, Park Place, W. (V.-P. 1867–8.) (P. 1869–70.)

1885 SIMON, SIR JOHN, K.C.B., D.C.L., LL.D., F.R.S., 40, Kensington Square, S.W.

1889 GAIRDNER, WILLIAM TENNANT, M.D., LL.D., St. Vincent Street, Glasgow.

1889 JENNER, SIR WILLIAM, Bart., M.D., K.G.C.B., D.C.L., LL.D., F.R.S., Greenwood, Bishop's Waltham, Hants. (P. 1875–6.)

1889 LISTER, SIR JOSEPH, Bart., D.C.L., LL.D., F.R.S., 12, Park Crescent, N.W. (P. 1881–2.)

FOREIGN HONORARY MEMBERS.

ELECTED

1881 BILLINGS, JOHN S., M.D., D.C.L.Oxon., Brevet Lieut.-Col. and Surgeon U.S. Army; Librarian, Surgeon-General's Office, Washington.

1874 BILLROTH, THEODOR, M.D., Professor of Surgery in the University of Vienna.

1881 VON ESMARCH, FRIEDRICH, M.D., Professor of Surgery and Director of the Surgical Clinique in the University of Kiel.

1881 MAZZONI, COSTANZO, Professor of Surgery at the Royal University of Rome, and Surgeon to the Hospital of San Giacomo at Rome.

1889 MITCHELL, S. WEIR, M.D., Professor of Medicine in the University of Philadelphia.

1881 OLLIER, LEOPOLD, M.D., Honorary Surgeon to the Hôtel Dieu of Lyons.

1881 PASTEUR, L., Member of the Institute (Academy of Sciences) of Paris.

1881 VERNEUIL, ARISTIDE, Member of the Institute of Paris.

1874 VON ZIEMSSEN, H., M.D., Professor of Clinical Medicine at Munich.

*** *Members are requested to inform the Secretaries of any Corrections when necessary.*

LIST OF MEMBERS.

(O.M.) *Original Member.*
(P.) *President.*
(V.P.) *Vice-President.*
(T.) *Treasurer.*
(S.) *Secretary.*
(C.) *Member of Council.*

Members who have compounded for their Subscriptions are marked thus (*). *Non-Resident Members who have paid the Composition Fee for the 'Transactions' are marked thus* (†). *The figures succeeding the word* Trans. *show the number of Papers contributed to the 'Transactions.'* C.S. *refers to the Specimens exhibited by Card.*

ELECTED

1893 ABBOTT, FRANCIS CHARLES, M.B., B.S., St. Thomas's Hospital, S.E.
1879 ABERCROMBIE, JOHN, M.D., 23, Upper Wimpole Street, W. (C. 1890–2.) *C.S.* 3.
O.M. ACLAND, Sir HENRY WENTWORTH, Bart., M.D., K.C.B., LL.D., F.R.S., Broad Street, Oxford. (V.P. 1868–70.)
1889 ACLAND, THEODORE DYKE, M.D., 74, Brook Street, W. *Trans.* 1.
1883 ADAMS, WILLIAM COODE, M.B., 1, Eton Avenue, South Hampstead, N.W.
1888 ADDINSELL, AUGUSTUS W., M.B., C.M., 30, Ashburn Place, South Kensington, S.W.
1884 ADENEY, EDWIN LEONARD, M.D., 3, Sion Terrace, Mount Sion, Tunbridge Wells.
1883 ALLCHIN, WILLIAM HENRY, M.B., 5, Chandos Street, W.
1885 ALLINGHAM, HERBERT WILLIAM, 25, Grosvenor Street, W. *Trans.* 6.
1871 ALTHAUS, JULIUS, M.D., 48, Harley Street, W. (C. 1879–81.) *Trans.* 5, *C.S.* 1.
1888 ANDERSON, JOHN, M.D., 9, Harley Street, W.
1868 ANDERSON, JOHN FORD, M.D., 41, Belsize Park, N.W.
1883 ANDERSON, WILLIAM, 2, Harley Street, W. (C. 1891–3.) *Trans.* 5.
O.M. *ANDREW, JAMES, M.D., Sunnycote, Emery Down, Lyndhurst, Hants. (C. 1872–4, V.P. 1885–6.) *Trans.* 1.
1887 ARKLE, CHARLES, M.D., 66, Wimpole Street, W. *Trans.* 2, *C.S.* 2.
1885 ARMSTRONG, HENRY GEORGE, Heathcote, Crowthorne, Berkshire.
1888 ARMSTRONG, HUGH, Aylestone Hill, Hereford.
O.M. ARNOTT, HENRY. (C. 1871–5.) *Trans.* 3.
1880 *BAKER, HENRY FRANCIS, 2, Mandeville Place, Manchester Square, W. *C.S.* 1.

ELECTED

1883 BALLANCE, CHARLES ALFRED, M.B., M.S., 106, Harley Street, W. *Trans.* 1, *C.S.* 2.

1888 BANHAM, HENRY FRENCH, M.D., Sidmouth House, Reading.

1868 BANTOCK, GEORGE GRANVILLE, M.D., 12, Granville Place, W.

1876 BARKER, ARTHUR E. J., 87, Harley Street, W. (C. 1883–5.) *Trans.* 10, *C.S.* 6.

1882 BARKER, FREDERICK CHARLES, M.D., Surgeon-Major, Bombay Medical Service, India.

1875 BARLOW, THOMAS, M.D., 10, Wimpole Street, W.C. (C. 1880–2, 1891–3, S. 1888–90.) *Trans.* 10, *C.S.* 5.

1888 BARRS, A. G., M.D., 22, Park Place, Leeds.

1888 BARTON, EDWIN A., 35, Cheniston Gardens, Kensington, W.

1891 BARTON, J. KINGSTON, 2, Courtfield Road, S.W.

O.M. BARWELL, RICHARD, 55, Wimpole Street, W. (C. 1872–5, V.P. 1877–9.) *Trans.* 18, *C.S.* 2.

O.M. BASTIAN, HENRY CHARLTON, M.D., F.R.S., 8A, Manchester Square, W. (C. 1876–8, V.P. 1891–3.) *Trans.* 7.

1888 BATTERHAM, JOHN WILLIAMS, M.B., B.S., Bank House, Grand Parade, St. Leonard's.

1886 BATTLE, WILLIAM HENRY, 2, Mansfield Street, W. *Trans.* 2, *C.S.* 5.

1868 BAÜMLER, CHRISTIAN G. H., M.D., University of Erlangen. *Trans.* 4.

1880 *BEEVOR, CHARLES EDWARD, M.D., 33, Harley Street, W. (C. 1890–1.) *C.S.* 2.

1884 BENHAM, F. LUCAS, M.D., 93, Elizabeth Street, Eaton Square, S.W. *Trans.* 1.

1883 BENHAM, ROBERT FITZROY, Abercorn House, Castletown Road, West Kensington, W.

1885 BENNETT, A. HUGHES, M.D., 76, Wimpole Street, W. *Trans.* 2.

1878 BENNETT, STORER, 17, George Street, Hanover Square, W. *C.S.* 1.

1874 BENNETT, WILLIAM HENRY, 1, Chesterfield Street, W. (C. 1889, 1892–3, S. 1890–1.) *Trans.* 4, *C.S.* 3.

1889 BENTLEY, ARTHUR J. M., M.D., Mena House, Pyramids, Cairo, Egypt.

1882 BERRY, FREDERICK HAYCRAFT, M.B., Watford, Herts.

1885 BERRY, JAMES, 60, Welbeck Street, W.

1889 BIDWELL, LEONARD ARTHUR, 54, Harley Street, W.

1890 BINDLEY, ROBERT ALFRED, 35, Highbury Hill, N.

1882 BINDLEY, PHILIP HENRY, M.B., Branksome Road, St. Leonards-on-Sea.

1879 BINDON, WM. JOHN VERREKER, M.D.

1886 BISS, CECIL YATES, M.D., 135, Harley Street, W. *Trans.* 1.

1889 BISSHOPP, FRANCIS ROBERT BRYANT, M.A., M.B., B.S., Belle Vue, Mount Pleasant, Tunbridge Wells.

1881 BLACK, JAMES, Hillside, Hermitage Road, Norwood.

1892 BLAXALL, FRANK RICHARDSON, M.D., Rendlesham, Hornsey Lane, N.

1893 BOND, J. W., M.D., 26, Harley Street, W. *C.S.* 1.

1888 BOSTOCK, ROBERT ASHTON, 73, Onslow Gardens, Brompton.

ELECTED

1883 BOWLBY, ANTHONY A., 24, Manchester Square, W. (C. 1891–3.) *Trans.* 2, *C.S.* 2.

1883 †BOWLES, ROBERT LEAMON, M.D., 16, Upper Brook Street, W. (C. 1890–1.)

1889 BOYD, STANLEY, M.B., 134, Harley Street, W. *Trans.* 1, *C.S.* 3.

1890 BRADFORD, JOHN ROSE, M.D., 52, Upper Berkeley Street, W.

1878 BRIDGES, ROBERT, M.B., M.A., The Manor House, Yattendon, Berkshire. *Trans.* 1.

1868 BRIGHT, GEORGE CHARLES, M.D., Cannes, Alpes Maritimes, France.

1868 BRIGHT, JOHN MEABURN, M.D., Forest Hill, S.E.

O.M. BRISTOWE, JOHN S., M.D., F.R.S., 13, Old Burlington Street, W. (C. 1869–70, V.P. 1879–80.) *Trans.* 5.

O.M. BROADBENT, Sir WILLIAM HENRY, Bart., M.D., 84, Brook Street, W. (C. 1871–3, V.P. 1881–3, P. 1887–8.) *Trans.* 17.

1887 BROCK, J. H. E., M.D., B.S., 115, Adelaide Road, N.W.

O.M. BRODHURST, BERNARD EDWARD, 20, Grosvenor Street, W. *Trans.* 2, *C.S.* 1.

1890 BROWN, WALTER HENRY, 19, Queen Street, Leeds. *Trans.* 2.

1876 BROWNE, GEORGE BUCKSTON, 80, Wimpole Street, W. (C. 1891–3.) *Trans.* 3.

1893 BROWNE, JAMES WILLIAM, M.B., 7, Norland Place, Holland Park, W.

1887 BROWNE, OSWALD AUCHINLECK, M.A., M.B., 43, Bedford Square, W.C.

1883 BRUCE, JOHN MITCHELL, M.D., 70, Harley Street, W.

O.M. BRYANT, THOMAS, 65, Grosvenor Street, W. (C. 1872, V.P. 1876–7, P. 1885–6.) *Trans.* 8.

O.M. BUCHANAN, SIR GEORGE, M.D., LL.D. Ed., F.R.S., 27, Woburn Square, W.C. (C. 1877, V.P. 1892–3.)

1890 BUCKLAND, FRANCIS O., B.A., M.B., C.M., 6, Lower Sloane Street, S.W. *Trans.* 1.

1891 BURGHARD, FREDERIC FRANCOIS, M.D., M.S., 46, Weymouth Street, W.

1881 BURNET, ROBERT WILLIAM, M.D., 6, Upp. Wimpole Street, W. *Trans.* 1.

1879 BURTON, WILLIAM EDWARD, 24, Wimpole Street, W.

1887 BUTLER-SMYTHE, ALBERT CHARLES, 76, Brook Street, W. *Trans.* 1.

1881 BUTLIN, HENRY TRENTHAM, 82, Harley Street, W. (C. 1887–9.) *Trans.* 7.

1871 BUTT, WILLIAM F.

1884 BUXTON, DUDLEY WILMOT, M.D., B.S., 82, Mortimer Street, W. (9, Portland Place, W.).

O.M. BUZZARD, THOMAS, M.D., 74, Grosvenor Street, W. (S. 1870–2, C. 1873–6, V.P. 1880–1.) *Trans.* 14, *C.S.* 1.

1891 CADDY, ARNOLD, 2/2, Harington Street, Calcutta.

1886 CAHILL, JOHN, 12, Seville Street, Lowndes Square, S.W.

1890 CALVERT, JAMES, M.D., 36, Queen Anne Street, W. *Trans.* 1, *C.S.* 1.

1893 CAMPBELL, HARRY, M.D., 20, Devonshire Street, W.

ELECTED

1891 CANNEY, H. E. LEIGH, M.B., 122, Brompton Road, S.W.
1891 CARLESS, ALBERT, M.S., M.B., 10, Welbeck Street, W.
1890 CARR, JOHN WALTER, M.D., 40, Bloomsbury Square, W.C. *Trans.* 1, *C.S.* 1.
1889 CARTER, WILLIAM ALEXANDER, M.D., M.Ch., Surgeon-Major, Grenadier Guards' Hospital, Rochester Row, S.W.
1869 CARTER, ROBERT BRUDENELL, 27, Queen Anne Street, W. (C. 1873–6, V.P. 1879–81.) *Trans.* 8.
1885 CATON, RICHARD, M.D., 86, Rodney Street, Liverpool. *Trans.* 2.
1868 CAVAFY, JOHN, M.D., 2, Upper Berkeley Street, W. (C. 1881–3.) *Trans.* 4.
O.M. CAYLEY, WILLIAM, M.D., 27, Wimpole Street, W. (C. 1874–5, S. 1876–8, C. 1879–80, V.P. 1885–6.) *Trans.* 7, *C.S.* 1.
1890 CHAPMAN, CHARLES WILLIAM, M.D., 21, Weymouth Street, W.
1884 CHAPMAN, PAUL M., M.D., 1, St. John Street, Hereford. *C.S.* 1.
1885 CHEYNE, W. WATSON, M.B., C.M., 75, Harley Street, W. *C.S.* 1.
1873 CHISHOLM, EDWIN, M.D., Abergeldie, Ashfield, near Sydney, New South Wales.
O.M. CHURCH, WILLIAM SELBY, M.D., 130, Harley Street, W. (C. 1874–6.)
1873 CHURTON, THOMAS, M.D., 35, Park Square, Leeds. (C. 1889–91.) *Trans.* 3.
O.M. CLAPTON, EDWARD, M.D., 22, St. Thomas's Street, Southwark, S.E. (C. 1872–4.) *Trans.* 1.
O.M. CLARK, Sir ANDREW, Bart., M.D., LL.D., F.R.S., 16, Cavendish Square, W. (C. 1876–8, V.P. 1880–2, P. 1883–4.) *Trans.* 2.
1874 CLARK, ANDREW, 71, Harley Street, W. *Trans.* 1.
1887 CLARK, FRANCIS WILLIAM, The Dispensary, Newcastle-on-Tyne.
1885 †CLARKE, J. MICHELL, M.B., 28, Pembroke Road, Clifton, Bristol.
1885 CLARKE, WILLIAM BRUCE, M.B., 46, Harley Street, W. *Trans.* 2, *C.S.* 1.
1877 †CLAY, ROBERT HOGARTH, M.D., 4, Windsor Villas, Plymouth.
1887 CLEMOW, ARTHUR HENRY WEISS, M.D., C.M., 1, Comeragh Road, W. *C.S.* 1.
1877 *CLUTTON, HENRY HUGH, M.A., 2, Portland Place, W. (C. 1885–7.) *Trans.* 10, *C.S.* 2.
1893 COLE, ROBERT HENRY, M.B., Moorcroft, Hillingdon, Middlesex.
1882 COLLIER, HERBERT, M.D., The Grange, Gorleston, Great Yarmouth, Norfolk.
1882 COLQUHOUN, DANIEL, M.D., Dunedin, New Zealand.
1872 COOKE, THOMAS, 40, Brunswick Square, W.C.
1868 COOPER, FRANK W.
1880 COTTLE, WYNDHAM, M.D., 3, Savile Row, W.
1892 COTTERELL, EDWARD, 5, Halkin Street West, S.W.
O.M. COUPER, JOHN, 80, Grosvenor Street, W. (C. 1874.)
1875 COUPLAND, SIDNEY, M.D. (C.), 16, Queen Anne Street, W. (S. 1882–4, C. 1885–7.) *Trans.* 5, *C.S.* 2.

ELECTED

1886 COUSINS, JOHN WARD, M.D., Riversdale, Kent Road, Southsea. *Trans.* 1.

1882 COXWELL, C. F., M.B. *Trans.* 2.

1879 CRIPPS, WILLIAM HARRISON, 2, Stratford Place, W. (C. 1886–8.) *Trans.* 3.

1872 CRITCHETT, ANDERSON, 21, Harley Street, W.

1877 CROCKER, HENRY RADCLIFFE, M.D., 121, Harley Street, W. (C. 1884–5.) *Trans.* 14.

O.M. CROFT, JOHN, 3, Mansfield Street, W. (C. 1870–2, V.P. 1882–4.) *Trans.* 12.

1890 CROWLE, THOMAS HENRY RICKARD, 3, Campden Hill Road, W.

1893 CURTIS, HENRY JONES, M.D., B.S., University College Hospital, W.C.

1872 DALBY, Sir WILLIAM BARTLETT, M.B., 18, Savile Row, W. (C. 1879–81.) *Trans.* 4.

1882 DALLAWAY, J. W. DENNIS, 5, Duchess Street, W.

1891 DARDENNE, HENRI, M.B., French Hospital, Shaftesbury Avenue, W.C.

1886 DAVIES, ARTHUR T., M.D., 23, Finsbury Square, E.C. *C.S.* 10.

1879 DAVIES-COLLEY, J. NEVILLE C., M.B., M.C., 36, Harley Street, W. (C. 1885–6.) *Trans.* 7, *C.S.* 1.

1879 †DAVY, HENRY, M.D., 29, Southernhay, Exeter.

1868 DAY, WILLIAM HENRY, M.D., 10, Manchester Square, W. (C. 1892–3.) *Trans.* 5.

1889 DEAN, HENRY PERCY, 84, Wimpole Street, W.

1879 †DENNIS, FREDERIC S., M.D., 542, Madison Avenue, New York, U.S.

1875 DENT, CLINTON T., 61, Brook Street, W. (C. 1884–6.) *Trans.* 2.

O.M. DICKINSON, WILLIAM HOWSHIP, M.D., 9, Chesterfield Street, W. (C. 1874–5, V.P. 1888–9.) *Trans.* 2.

1891 DICKINSON, WILLIAM LEE, M.B., 9, Chesterfield Street, W. *Trans.* 3.

1871 DIVER, EBENEZER, M.D., Kenley, Caterham Valley, Surrey. (C. 1890–2.)

O.M. DOWN, JOHN LANGDON H., M.D., 81, Harley Street, W. (C. 1870–2.) *Trans.* 1.

1868 DRAGE, CHARLES, M.D., Hatfield, Herts.

1879 DREWITT, F. G. DAWTREY, M.D., 2, Manchester Square, W. (C. 1886–8.) *Trans.* 2.

O.M. DUCKWORTH, Sir DYCE, M.D., LL.D. (*President*), 11, Grafton Street, Bond Street, W. (C. 1875–7, V.P. 1887–8, P. 1891–2.) *Trans.* 18, *C.S.* 5.

O.M. DUFFIN, ALFRED B., M.D., 18, Devonshire Street, W. (C. 1872–4, V.P. 1891–3.) *Trans.* 6.

1884 DUKE, EDGAR, 30, Pevensey Road, St. Leonard's-on-Sea.

1869 DUKE, OLLIVER THOMAS, M.B., Surgeon, Bengal Army, India.

1889 DUNCAN, JOHN, M.D., St. Petersburg.

1889 DUNN, LOUIS ALBERT, M.S., 10, St. Thomas's Street, S.E. *C.S.* 1.

ELECTED

O.M. DURHAM, ARTHUR EDWARD, 82, Brook Street, W. (C. 1867–9, V.P. 1884–5.) *Trans.* 5.

1884 EDMUNDS, WALTER, M.C., 75, Lambeth Palace Road, S.E.

1882 EMOND, EMILE, M.D., 113, Boulevard Beaumarchais, Paris.

O.M. ERICHSEN, JOHN E., LL.D., F.R.S., 6, Cavendish Place, W. (V.P. 1869–71.)

1868 EVANS, JULIAN, M.B., 123, Finborough Road, Redclyffe Square, S.W.

1888 *EVE, FREDERIC S., 125, Harley Street, Cavendish Square, W. *Trans.* 1, *C.S.* 1.

1877 EWART, WILLIAM, M.D., 33, Curzon Street, W. (C. 1884–6.) *C.S.* 1.

1893 EZARD, EDWARD HENRY, M.D., B.S., 220, Lewisham High Road, S.E.

1868 †FAIRBANK, FREDERICK ROYSTON, M.D., 39, Warrior Square, St. Leonards-on-Sea. *Trans.* 1.

1889 FARDON, EDWARD ASHBY, Middlesex Hospital.

1885 FENN, EDWARD LIVEING, M.D., Grey Friars, Colchester.

1887 FENWICK, E. HURRY, 5, Old Burlington Street, W. *Trans.* 1, *C.S.* 1.

1872 FENWICK, J. C. J., M.D., 25, North Road, Durham.

1893 FENWICK, WILLIAM SOLTAU, M.D., 63, Upper Berkeley Street, W.

1878 FIELD, GEORGE P., 34, Wimpole Street, W.

1876 FINLAY, DAVID WHITE, M.D., 2, Queen's Terrace, Aberdeen. (C. 1885–7, S. 1891.) *Trans.* 6.

1885 FITZ-PATRICK, THOMAS, M.D., 30, Sussex Gardens, Hyde Park, W.

1889 FLEMMING, PERCY, M.D., 35, Regent's Park Road, N.W. *C.S.* 1.

1878 *FONMARTIN, HENRY DE, M.D., 1, Anchor Gate Terrace, Portsea, Hants.

1889 FORBES, DANIEL MACKAY, Shoreditch Infirmary, 204, Hoxton Street, N.

1890 FORMAN, E. BAXTER, M.D., 11, Bramham Gardens, S. Kensington, S.W.

1890 FOSTER, MICHAEL G., M.B., M.A., Villa San Giovanni, Alassio, Italy.

1881 FOWLER, JAMES KINGSTON, M.D., 35, Clarges Street, W. (C. 1887–9.) *Trans.* 4, *C.S.* 5.

1886 FOX, R. HINGSTON, M.D., 23, Finsbury Square, E.C.

1878 FOX, THOMAS COLCOTT, M.B., 14, Harley Street, W. (C. 1888–90.) *Trans.* 6, *C.S.* 1.

1887 FREEMAN, HENRY WILLIAM, 24, Circus, Bath.

1890 FULLER, HENRY ROXBURGH, 45, Curzon Street, W.

1891 FYFFE, W. KINGTON, M.B., B.C., 19, Duke Street, Manchester Square, W. *Trans.* 1.

1888 GAGE-BROWN, CHARLES HERBERT, M.D., 74, Cadogan Place, S.W.

1868 GANT, FREDERICK JAMES, 16, Connaught Square, W. (C. 1877–9.) *Trans.* 3.

1887 GARROD, ARCHIBALD EDWARD, M.A., M.D., 9, Chandos Street, W.

1879 GARSTANG, THOMAS WALTER HARROPP, The Heath, Knutsford, Cheshire.

1885 GIBBONS, ROBERT ALEXANDER, M.D., 29, Cadogan Place, S.W. *Trans.* 1.

ELECTED

1868 GLOVER, JAMES GREY, M.D., 25, Highbury Place, N. (C. 1878–80, V.P. 1892–3.) *Trans.* 2.

1893 GLOVER, LEWIS G., M.B., B.C., Victoria Hospital, Tite Street, Chelsea, S.W.

1882 GODDARD, EUGENE, M.D., 106, Highbury New Park, N.

1875 GODLEE, RICKMAN JOHN, M.S., 19, Wimpole Street, W. (C. 1882–3, 1887–9, S. 1884–6.) *Trans.* 12, *C.S.* 4.

1882 GOLDIE, ROBERT WILLIAM, Medical Superintendent, Poplar and Stepney Sick Asylum, Devon's Road, Bromley.

1878 GOLDING-BIRD, C. H., M.B., 12, Queen Anne Street, W. (C. 1887–9.) *Trans.* 10, *C.S.* 1.

1875 GOODHART, JAMES FREDERIC, M.D., 25, Weymouth Street, W. (C. 1880–2.) *Trans.* 13, *C.S.* 2.

1891 GOODMAN, ROGER NEVILLE, M.B., 3, Grove Crescent, Kingston-on-Thames.

1869 GOODRIDGE, HENRY FREDERICK AUGUSTUS, M.D., 10, Brock Street, Bath.

1882 GOODSALL, D. H., 17, Devonshire Place, W.

1877 GOULD, A. PEARCE, M.S. (*Hon. Secretary*), 10, Queen Anne Street, W. (C. 1885–7, S. 1892–3.) *Trans.* 11, *C.S.* 3.

1875 GOWERS, WILLIAM RICHARD, M.D., F.R.S., 50, Queen Anne Street, W. (C. 1881–2.) *Trans.* 5.

1891 GRANT, J. DUNDAS, M.D., 8, Upper Wimpole Street, W.

1868 GREEN, T. HENRY, M.D., 74, Wimpole Street, W. (C. 1877–9.) *Trans.* 2, *C.S.* 1.

1875 †GREENFIELD, WILLIAM SMITH, M.D., 7, Heriot Row, Edinburgh. (C. 1881.) *Trans.* 3.

1893 *GRIFFITH, WALTER SPENCER ANDERSON, M.D., 114, Harley Street, W.

1883 GROSS, CHARLES, M.D., M.S., 112, Westbourne Grove, W.

1887 HABERSHON, SAMUEL HERBERT, M.D., 70, Brook Street, W.

1875 HALE, C. D. B., 3, Sussex Place, W. *Trans.* 1.

1878 HALL, F. DE HAVILLAND, M.D., 47, Wimpole Street, W. (C. 1885–87.) *Trans.* 8, *C.S.* 3.

1889 HALSTEAD, GEORGE EZRA, M.D., B.S., Ramsgate.

1888 HANDFIELD-JONES, MONTAGU, M.D., 35, Cavendish Square, W.

1886 †HANDFORD, HENRY, M.D., 14, Regent Street, Nottingham. (C. 1893.) *Trans.* 5, *C.S.* 1.

1886 HARDIE, JAMES, M.D., 15, St. John Street, Manchester.

O.M. HARLEY, JOHN, M.D., F.L.S., 9, Stratford Place, W. (C. 1875.) *Trans.* 1.

1890 HARPER, JAMES, M.D., 25, Rosary Gardens, South Kensington, S.W.

1872 HARRIS, HENRY, M.D., Trengweath, Redruth, Cornwall.

1889 HARRIS, HERBERT ELWIN, M.B., The Infirmary, East Dulwich Grove, S.E. *Trans.* 1.

1881 HARRISON, CHARLES EDWARD, M.B., Grenadier Guards Hospital, Rochester Row, S.W.

ELECTED

1892 HARRISON, DAMER, 53, Rodney Street, Liverpool. *Trans.* 1.

1892 HARVEY, JOHN STEPHENSON SELWYN, M.D., 1, Artwood Road, S.W.

1869 HAWARD, J. WARRINGTON, 16, Savile Row, W. (C. 1876–8, 1884–6, S. 1881–3, V.P. 1888.) *Trans.* 13.

1886 HAWKINS, FRANCIS HENRY, M.B., 59, Wimpole Street, W. *Trans.* 3, *C.S.* 2.

1889 HAWKINS, HERBERT PENNELL, M.B., B.S., 109, Harley Street, W. *Trans.* 1.

1890 HAWKINS-AMBLER, GEORGE ARTHUR, 162, Upper Parliament Street, Liverpool.

O.M. HEATH, CHRISTOPHER 36, Cavendish Square, W. (C. 1867–71, V.P. 1876–8, T. 1879–88, P. 1889–90.) *Trans.* 19.

1879 HENDERSON, GEORGE COURTENAY, M.D., Kingston, Jamaica, West Indies.

1882 HERON, GEORGE ALLAN, M.D., 57, Harley Street, W.

1884 HERRINGHAM, WILMOT PARKER, M.D., 13, Upper Wimpole Street, W. *Trans.* 2, *C.S.* 1.

1888 †HETHERINGTON, GEORGE HAYNES, 10, Museum Street, Ipswich.

1874 HOLDERNESS, WILLIAM BROWN, 15, Park Street, Windsor.

1868 †HOLMAN, CONSTANTINE, M.D., 26, Gloucester Place, Portman Square, W.

O.M. HOLMES, TIMOTHY, 18, Great Cumberland Place, W. (C. 1867–9, V.P. 1873–5.) *Trans.* 16.

O.M. HOLT, BARNARD WIGHT, 14, Savile Row, W. *Trans.* 1.

O.M. HOLTHOUSE, CARSTEN. (C. 1870–2.) *Trans.* 8.

1878 HOOD, DONALD WILLIAM CHARLES, M.D., 43, Green Street, W. (C. 1891–3.) *Trans.* 1.

1883 HOPKINS, JOHN, Central London Sick Asylum, Cleveland Street, W. *C.S.* 1.

1884 HORSLEY, VICTOR, M.B., F.R.S., 25, Cavendish Square, W. *Trans.* 2, *C.S.* 1.

1880 *HOVELL, T. MARK, 105, Harley Street, W.

1893 HOWARD, R. J. BLISS, M.D., 31, Queen Anne Street, W.

1876 HOWSE, HENRY GREENWAY, M.S., 59, Brook Street, W. (C. 1881–3, V.P. 1890–2.) *Trans.* 3.

O.M. HULKE, JOHN WHITAKER, F.R.S., 10, Old Burlington Street, W. (C. 1867–9, V.P. 1878–80, P. 1893.) *Trans.* 14.

O.M. HUMPHRY, SIR GEORGE MURRAY, M.D., LL.D., F.R.S., Cambridge. (V.P. 1867–70.)

1892 HUNTER, WILLIAM, M.D., 54, Harley Street, W.

O.M. HUTCHINSON, JONATHAN, F.R.S., 15, Cavendish Square, W. (C. 1867–8, V.P. 1875–6.) *Trans.* 14, *C.S.* 1.

1879 INKSON, JAMES, M.D., Brigade Surgeon, Army.

1883 JACKSON, GEORGE HENRY, 6, Cliff Bridge Terrace, Scarborough.

ELECTED

O.M. JACKSON, J. HUGHLINGS, M.D., F.R.S., 3, Manchester Square, W. (C. 1872–3, V.P. 1887.) *Trans.* 2.

1877 JACOBSON, WALTER HAMILTON ACLAND, M.B., M.Ch., 66, Great Cumberland Place, W. (C. 1890–2.) *Trans.* 2.

1888 JAMISON, ARTHUR, M.D., C.M., 18, Lowndes Street, S.W.

1888 JAMES, JAMES THOMAS, M.D., 30, Harley Street, W.

1875 JESSETT, FREDERICK BOWREMAN, 1, Buckingham Palace Mansions, S.W. *Trans.* 1.

O.M. JOHNSON, SIR GEORGE, M.D., F.R.S., 11, Savile Row, W. (V.P. 1874–6.) *Trans.* 5.

1889 JOHNSON, RAYMOND, M.B., B.S., 20, Weymouth Street, W. *Trans.* 1.

1878 JOHNSTON, WILLIAM, M.D., M.C., 16, Lonsdale Terrace, Upper Kent Street, Leicester.

O.M. JONES, SYDNEY, M.B., 16, George Street, Hanover Square, W. (C. 1867–8, V.P. 1886–7.) *Trans.* 2.

1872 JONES, THOMAS RIDGE, M.D., 4, Chesham Place, S.W. (C. 1892–3.)

1876 JORDAN, FURNEAUX. *Trans.* 1.

1886 JULER, HENRY EDWARD, 23, Cavendish Square, W.

1878 KEETLEY, CHARLES ROBERT BELL, 56, Grosvenor Street, W. *Trans.* 2.

O.M. KELLY, CHARLES, M.D., Worthing, Sussex.

1882 KESTEVEN, WILLIAM HENRY, 372, Camden Road, N. *Trans.* 1.

1883 KIDD, PERCY, M.D., 60, Brook Street, W. (C. 1891–2.) *Trans.* 4, *C.S.* 2.

1887 †KNAGGS, R. LAWFORD, B.C., Huddersfield. *Trans.* 1.

1878 LACEY, THOMAS WARNER, 196, Burrage Road, Plumstead.

1890 LANCASTER, ERNEST LE CRONIER, M.B., B.Ch., Winchester House, Swansea, S. Wales. *Trans.* 1.

1883 LANE, WILLIAM ARBUTHNOT, M.B., M.S., 8, St. Thomas's Street, S.E. (C. 1893.) *Trans.* 15, *C.S.* 6.

O.M. LANGTON, JOHN, 62, Harley Street, W. (C. 1878–80, V.P. 1892–3.) *Trans.* 2.

1886 LANKESTER, HERBERT, M.D., 1, Elm Park Gardens, South Kensington, S.W.

1885 LARDER, HERBERT, Whitechapel Infirmary, Baker's Row, E. *C.S.* 1.

O.M. LAWSON, GEORGE, 12, Harley Street, W. (S. 1871–3, C. 1874–6, V.P. 1881–3.) *Trans.* 16.

1877 †LEDIARD, HENRY AMBROSE, M.D., 41, Lowther Street, Carlisle. (C. 1889.) *Trans.* 5.

O.M. LEE, HENRY, 9, Savile Row, W. (V.P. 1870–2.) *Trans.* 7.

1877 LEES, DAVID B., M.D., 22, Weymouth Street, W. (C. 1885.) *Trans.* 4.

1893 LENDON, EDWIN HARDING, M.B., 8, Norland Place, Holland Park, W.

1892 LEWIS, EDWARD JOHN, M.B., B.C., 87, Hamilton Terrace, N.W.

1879 LICHTENBERG, GEORGE, M.D., 47, Finsbury Square, E.C.

1890 LITTLE, JOHN FLETCHER, M.B., 32, Harley Street, W. *C.S.* 2.

1868 LITTLE, LOUIS STROMEYER, China.

ELECTED

1891 LITTLEWOOD, HARRY, 40, Park Square, Leeds *Trans.* 1.
1875 LIVEING, EDWARD, M.D., 52, Queen Anne Street, W.
1872 LIVEING, ROBERT, M.D., 11, Manchester Square, W. (C. 1883–4.) *Trans.* 2.
1885 LOCKWOOD, CHARLES BARRETT, 19, Upper Berkeley Street, W. *Trans.* 2.
1876 LONGHURST, ARTHUR EDWIN TEMPLE, M.D., 4, Eaton Square, S.W. (C. 1889–91.) *Trans.* 1.
1881 LUBBOCK, MONTAGU, M.D., 19, Grosvenor Street, W.
1876 LUCAS, R. CLEMENT, M.B., B.S., 18, Finsbury Square, E.C. (C. 1883–5.) *Trans.* 9.
1879 LUNN, JOHN REUBEN, New Marylebone Infirmary, Rackham Street, Ladbroke Grove Road, W. (C. 1890–1.) *Trans.* 5, *C.S.* 8.
1889 MACBRIDE, P., M.D., 16, Chester Street, Edinburgh.
1871 MAC CORMAC, Sir WILLIAM, 13, Harley Street, W. (C. 1877–9, V.P. 1888–9.) *Trans.* 5.
1891 MACDONALD, GRENVILLE, M.D., 85, Harley Street, W.
1881 MCHARDY, MALCOLM MACDONALD, 5, Savile Row, W. *Trans.* 1.
1882 MACKENZIE, FREDERIC MORELL, 29, Hans Place, S.W.
1891 MACKENZIE, HECTOR W. G., M.A., M.D., 59, Welbeck Street, W. *Trans.* 4.
1879 MACKENZIE, STEPHEN, M.D., 18, Cavendish Square, W. (C. 1884, 1888–90, S. 1885–7.) *Trans.* 9, *C.S.* 10.
1884 MACKERN, JOHN, M.B., St. German's Lodge, Shooter's Hill Road, Blackheath.
1879 MACLAGAN, THOMAS JOHN, M.D., 9, Cadogan Place, S.W. (C. 1889–91.) *Trans.* 2.
1885 MACLAREN, RODERICK, M.D., Portland Square, Carlisle. *Trans.* 1.
1879 MAGILL, JAMES, M.D., M.C., Coldstream Guards Hospital, Vincent Square, Westminster, S.W.
1885 MAGUIRE, ROBERT, M.D., 4, Seymour Street, W. *Trans.* 1.
1881 MAKINS, GEORGE HENRY, 47, Charles Street, Berkeley Square, W. (C. 1892–3.) *Trans.* 2, *C.S.* 5.
1887 MALCOLM, JOHN D., M.B., C.M., 13, Portman Street, W.
1890 MANSON, PATRICK, M.D., C.M., 21, Queen Anne Street, W.
1888 †MARRIOTT, HYDE, M.B., Dial House, Stockport.
1868 MARSH, F. HOWARD, 30, Bruton Street, W. (C. 1876–7, 1881–3, S. 1878–80, V.P. 1887–8.) *Trans.* 12, *C.S.* 3.
1875 MARSHALL, F. J., St. George's Hospital, S.W.
1887 MARTIN, SIDNEY, M.D., B.S., 10, Mansfield Street, W.
1888 MASON, DAVID JAMES, M.D., C.M., Maidenhead.
1892 MASTERS, JOHN ALFRED, 35, Bruton Street, W.
1884 MAUDSLEY, HENRY CARE, M.D., 11, Spring Street, Melbourne, Victoria.
1892 MAUNSELL, HENRY WIDENHAM, M.D., M.A., 37, Stanhope Gardens, Queen's Gate, S.W.

ELECTED

1868 †MAY, EDWARD HOOPER, M.D., High Cross, Tottenham, Middlesex.
1888 MAY, WILLIAM PAGE, M.D., B.Sc.
1888 MENZIES, J. HERBERT, 47, Earl's Court Square, S.W.
1893 MERCER, WILLIAM BRACEWELL, M.B., B.C., Royal Hospital for Diseases of the Chest, City Road, E.C.
1878 MEREDITH, WILLIAM APPLETON, C.M., 21, Manchester Square, W. (C. 1887–9.) *Trans.* 2.
1873 MICKLE, WILLIAM JULIUS, M.D., Grove Hall Asylum, Bow, E.
1890 MILEY, MILES, M.A., M.B., 21, Belsize Avenue, Hampstead, N.W.
1882 MONEY, ANGEL, M.D. (C. 1888–90.) *Trans.* 3.
1874 MORGAN, JOHN HAMMOND, 68, Grosvenor Street, W. (C. 1883–5.) *Trans.* 2, *C.S.* 5.
1877 MORRIS, HENRY, M.B., 8, Cavendish Square, W. (C. 1884–6.) *Trans.* 9.
1877 MORRIS, MALCOLM ALEX., 8, Harley Street, W. (C. 1890–2.) *Trans.* 1, *C.S.* 1.
1888 MORISON, ALEXANDER, M.D., 14, Upper Berkeley Street, W. *Trans.* 2.
1885 MOTT, FREDERICK WALKER, M.D., C.M., 84, Wimpole Street, W.
1879 MOULLIN, CHARLES W. MANSELL, 69, Wimpole Street, W. (C. 1888–90.) *Trans.* 5, *C.S.* 2.
1875 MURPHY, SHIRLEY F., 41, Queen Anne Street, W. (C. 1888–90.) *C.S.* 1.
1885 MURRAY, ALEXANDER DALTON, M.B., Colombo, Ceylon.
1893 MURRAY, GEORGE REDMAYNE, M.B., 2, Saville Place, Newcastle-on-Tyne.
1883 MURRAY, HUBERT MONTAGUE, M.D., 27, Savile Row, W. (C. 1893.) *Trans.* 1.
1868 MYERS, ARTHUR BOWEN RICHARDS, 43, Gloucester Street, Warwick Square, S.W. (C. 1877–9.) *Trans.* 1.
1882 MYERS, A. T., M.D., 2, Manchester Square, W. (C. 1892–3.) *Trans.* 1, *C.S.* 1.
1872 MYRTLE, ANDREW S., M.D., 8, Park Parade, Harrogate. (C. 1892.)
1892 NASH, WALTER GIFFORD, 31, St. Peter's, Bedford.
1875 NETTLESHIP, EDWARD, 5, Wimpole Street, W. (C. 1881–2.) *Trans.* 2.
1889 †NEWMAN, D., M.D., 18, Woodside Place, Glasgow. *Trans.* 1.
O.M. NORTON, ARTHUR TREHERN, 101, Harley Street, W. (C. 1874–6.) *Trans.* 7.
O.M. NUNN, THOMAS WILLIAM, 8, Stratford Place, W. (C. 1873–4.) *Trans.* 8.
1880 O'CONNOR, BERNARD, M.D., Greenhill Park, Harlesden, N.W. *Trans.* 1.
O.M. OGLE, JOHN WILLIAM, M.D., 30, Cavendish Square, W. (C. 1867–8. V.P. 1884–5.) *Trans.* 6.
1868 †OGLE, WILLIAM, M.D., 98, Friar Gate, Derby.
1883 OLIVER, GEORGE, M.D., West End Park, Harrogate. *Trans.* 1.
1887 †OLIVER, THOMAS, M.D., 7, Ellison Place, Newcastle-upon-Tyne.

ELECTED

1887 OPENSHAW, THOMAS HORROCKS, M.B., 16, Wimpole Street, W.
1868 OPPERT, FRANZ, M.D., 128, Leipzigerstrasse, Germany. *Trans.* 1.
1877 ORD, WILLIAM MILLER, M.D. (*Treasurer*), 37, Upper Brook Street, W. (C. 1882–4, T. 1889–93.) *Trans.* 8, *C.S.* 1.
1890 ORD, W. WALLIS, M.B., B.Ch., 2, Queen Street, Mayfair, W. *C.S.* 1.
1887 ORMEROD, JOSEPH ARDERNE, M.D., 25, Upper Wimpole Street, W.
1884 ORMSBY, LAMBERT HEPENSTAL, M.D., 4, Merrion Square West, Dublin.
1883 ORTON, GEORGE HUNT, M.B., 1A, Campden Hill Road, Kensington, W.
1877 OWEN, ISAMBARD, M.D., 40, Curzon Street, W. (C. 1888–90.) *Trans.* 1.
1888 OXLEY, ALFRED RICE, M.D., Streatham Common.
1888 PAGE, FREDERICK, M.D., 1, Saville Place, Newcastle-on-Tyne.
1875 PAGE, HERBERT W., M.C., M.B., 146, Harley Street, W. (C. 1882–4.) *Trans.* 6.
1884 PAGET, STEPHEN, 57, Wimpole Street, W. *Trans.* 5, *C.S.* 1.
1873 PARKER, ROBERT WILLIAM, 13, Welbeck Street, W. (C. 1882–4, 1890–2, S. 1887–9, V.P. 1893.) *Trans.* 12, *C.S.* 7.
1881 PARKER, RUSHTON, M.B., B.S., 59, Rodney Street, Liverpool. *Trans.* 1, *C.S.* 1.
1890 PARKIN, ALFRED, M.S., 5, Albion Street, Hull. *Trans.* 1.
1881 PASTEUR, WILLIAM, M.D., 4, Chandos Street, W. (C. 1891–3.) *Trans.* 1, *C.S.* 3.
1893 PATERSON, DONALD ROSE, M.D., C.M., 18, Windsor Place, Cardiff.
1892 PAUL, FRANK THOMAS, 38, Rodney Street, Liverpool. *Trans.* 1.
1893 PAUL, JOHN ERNEST, M.B., University College Hospital, W.C.
1883 PAUL, JOHN LISTON, M.D., 43, Queensborough Terrace, W.
O.M. PAVY, FREDERICK WILLIAM, M.D., F.R.S., 35, Grosvenor Street, W. (C. 1869–71, V.P. 1882–4.) *Trans.* 3.
1886 PAYNE, JOSEPH FRANK, M.D., 78, Wimpole Street, W. *Trans.* 1.
1879 PEEL, ROBERT, 130, Collins Street East, Melbourne, Victoria.
1886 †PENNY, WILLIAM JOHN, 42, Caledonia Place, Clifton.
1887 PENROSE, FRANCIS GEORGE, M.D., 4, Harley Street, W. *Trans.* 1.
1882 PEPPER, AUGUSTUS JOSEPH, M.S., M.B., 13, Wimpole Street, W. *Trans.* 1.
1874 PHILLIPS, CHARLES DOUGLAS F., M.D., 10, Henrietta Street, W.
1884 PHILLIPS, SIDNEY, M.D., 62, Upper Berkeley Street, W. (C. 1893.) *Trans.* 4.
O.M. PICK, THOMAS PICKERING, 18, Portman Street, W. (S. 1874–7, C. 1878–80, V.P. 1885–6.) *Trans.* 4.
1885 PITT, GEORGE NEWTON, M.D., 24, St. Thomas's Street, S.E. *Trans.* 1, *C.S.* 4.
1883 PITTS, BERNARD, M.A., M.C., 109, Harley Street, W. (C. 1893.) *Trans.* 4.
1871 †PLAYNE, ALFRED, M.B., Maidenhead.
1884 POLAND, JOHN, 4, St. Thomas's Street, S.E.
1884 POLLARD, BILTON, 24, Harley Street, W. *Trans.* 2.

ELECTED

1868 POLLOCK, JAMES EDWARD, M.D., 52, Upper Brook Street, W. (C. 1878–80.)

1871 POORE, GEORGE VIVIAN, M.D., 30, Wimpole Street, W. (C. 1879–81.) *Trans.* 3.

1873 PORT, HEINRICH, M.D., 48, Finsbury Square, E.C.

1881 POWELL, H. A., M.A., 44, Sandgate Road, Folkestone.

O.M. POWELL, R. DOUGLAS, M.D., 62, Wimpole Street, W. (C. 1874–6, V.P. 1889–90.) *Trans.* 4.

1868 PRENTIS, CHARLES, Surgeon-Major, Bengal Medical Service; India.

1884 PRINGLE, JOHN JAMES, M.B., 23, Lower Seymour Street, W. *Trans.* 1, *C.S.* 1.

1884 PYE-SMITH, PHILIP HENRY, M.D., F.R.S., 48, Brook Street, W. (C. 1890–2.) *Trans.* 1.

O.M. QUAIN, Sir RICHARD, Bart., M.D., LL.D., F.R.S., 67, Harley Street, W. (C. 1867–9.)

1893 RAKE, ALFRED THEODORE, M,B., B.S., Guy's Hospital, S.E.

O.M. RAMSKILL, J. SPENCE, M.D., 5, St. Helen's Place, E.C.

1889 RANKING, JOHN E., M.D., Hanover House, Tunbridge Wells.

1868 RASCH, ADOLPHUS A., M.D., 7, South Street, E.C.

1883 READ, THOMAS LAURENCE, 11, Petersham Terrace, Queen's Gate, S.W.

1891 REMFRY, LEONARD, M.D., 60, Great Cumberland Place, W. *Trans.* 1.

O.M. REYNOLDS, JOHN RUSSELL, M.D., F.R.S., 38, Grosvenor Street, W. (C. 1867–8.)

1868 RICE, MICHAEL W., M.D. (C. 1876–8.)

O.M. RINGER, SYDNEY, M.D., F.R.S., 15, Cavendish Place, W. (C. 1871–2.)

1877 RIVINGTON, WALTER, M.S., 95, Wimpole Street, W. (C. 1886–8.) *Trans.* 3.

1873 †ROBERTS, DAVID LLOYD, M.D., 11, St. John Street, Manchester.

1888 ROBERTS, FRANK ERNEST, Tulse Dale Villa, Lower Norwood, S.E.

1883 ROBERTS, FREDERICK THOMAS, M.D., 102, Harley Street, W. (C. 1892–3.)

1890 ROBERTSON, ROBERT, M.D., Belgrave Road, Ventnor, Isle of Wight.

1885 ROBINSON, ARTHUR HENRY, M.D., Mile End Infirmary, Bancroft Road, N.E. *C.S.* 3.

1890 ROBINSON, GEORGE SOMERVILLE, Surgeon-Major, Army.

1892 ROBINSON, HENRY BETHAM, M.D., M.S., 6, Mansfield Street, W. *C.S.* 2.

1885 ROBSON, A. W. MAYO, Hilary Place, Leeds. (C. 1893.) *Trans.* 10.

1889 ROLLESTON, HUMPHRY DAVY, M.A., M.D., 13, Upper Wimpole Street, W. *Trans.* 1.

1888 ROPER, ARTHUR, Lewisham Hill, Blackheath. *Trans.* 1.

1889 ROSS, DANIEL MCCLURE, 76, Upper Berkeley Street, W.

1877 ROTH, BERNARD, 29, Queen Anne Street, W. *Trans.* 1, *C.S.* 4.

1890 ROUGHTON, EDMUND WILKINSON, 33, Westbourne Terrace, W.

O.M. ROUSE, JAMES, 2, Wilton Street, S.W. (C. 1875–7.) *Trans.* 2.

1874 ROWLAND, EDWARD ROGER, Dordrecht, Wodehouse, S. Africa.

ELECTED

1887 RUTHERFOORD, H. T., M.B.

1885 RYLE, REGINALD JOHN, M.D., Green View, Hadley Green, Barnet.

1882 SAINSBURY, HARRINGTON, M.D., 63, Welbeck Street, W.

O.M. SANDERSON, JOHN BURDON, M.D., LL.D., F.R.S., 50, Banbury Road, Oxford. (S. 1867–9, C. 1870, V.P. 1871–3.) *Trans.* 3.

1873 SAVAGE, GEORGE HENRY, M.D., 3, Henrietta Street, W. (C. 1882–3.)

1886 SAVILL, THOMAS DIXON, M.D., 12, Upper Berkeley Street, W. *Trans.* 1, *C.S.* 2.

1886 SCOTT, ALFRED, 15, German Place, Brighton.

1892 SCOTT, RICHARD JAMES HERBERT, 28, Circus, Bath.

1877 SEATON, EDWARD, M.D., The Limes, Clapham Common, S.W. *Trans.* 1.

1869 SEDGWICK, LEONARD WILLIAM, M.D., 2, Gloucester Terrace, Hyde Park, W. (C. 1879–81.)

1878 SEMON, FELIX, M.D., 39, Wimpole Street, W. (C. 1885–7.) *Trans.* 7, *C.S.* 3.

1884 SHARKEY, SEYMOUR, J., M.D., 2, Portland Place, W.

1889 SHAW, LAURISTON ELGIN, M.D., 10, St. Thomas's Street, S.E.

1875 SHERWOOD, ARTHUR PAUL, 8, Seaside Road, Eastbourne.

1886 SILCOCK, ARTHUR QUARRY, M.D., M.S., 52, Harley Street, W. *Trans.* 1. *C.S.* 2.

1879 SKERRITT, EDWARD MARKHAM, M.D., Coburg Villa, Richmond Hill, Clifton, Bristol. *Trans.* 2.

1872 SLIGHT, GEORGE, M.D., 37, Western Street, King's Road, Brighton.

1882 SMITH, E. NOBLE, 24, Queen Anne Street, W. *Trans.* 1.

1888 SMITH, FREDERICK J., M.B., 4, Christopher Street, Finsbury Square, E.C.

1884 SMITH, R. PERCY, M.D., Bethlem Royal Hospital, St. George's Road, S.E.

1893 SMITH, SOLOMON CHARLES, M.D., 4, Portman Mansions, Baker Street, W.

O.M. SMITH, THOMAS, 5, Stratford Place, W. (C. 1869–71, V.P. 1880–2.) *Trans.* 14.

1875 SMITH, T. GILBART, M.A., M.D., 68, Harley Street, W. (C. 1883–5.)

1872 SMITH, WILLIAM WILBERFORCE, M.D., 14, Stratford Place, W.

1868 SNOW, WILLIAM V., M.D., Richmond Gardens, Bournemouth.

1890 SOLLY, ERNEST, M.B., Strathlea, Harrogate, Yorks. *C.S.* 1.

O.M. SOUTHEY, REGINALD, M.D., 32, Grosvenor Road, Pimlico, W. (C. 1867–70, 1876–8, S. 1873–5, V.P. 1883–4.) *Trans.* 16.

1888 SPENCER, WALTER GEORGE, M.S., M.B., 35, Brook Street, W. *C.S.* 5.

1885 SPICER, FREDERICK, M.D., 282, Camden Road, N.W.

1888 SPICER, ROBERT HENRY SCANES, M.D., 28, Welbeck Street, W.

1882 SPOONER, FREDERICK HENRY, M.D., 4, Maitland Place, Lower Clapton, N.E.

1876 SQUIRE, A. BALMANNO, M.B., 24, Weymouth Street, W. *Trans.* 5, *C.S.* 3.

1892 STABB, EWEN CARTHEW, St. Thomas's Hospital, S.E. *C.S.* 1.

ELECTED

1879 STAPLES, FRANCIS PATRICK, Brigade-Surgeon, Army.
1889 STEWART, EDWARD, M.D., The Farm, Sheffield.
1871 STEWART, WILLIAM EDWARD, 16, Harley Street, W.
1874 †STIRLING, EDWARD C., M.D. [care of Messrs. ELDER & Co., 7, St. Helen's Place, E.C.], Adelaide, South Australia.
1888 STOKER, GEORGE, 14, Hertford Street, W.
1881 STOKES, HENRY FRASER, 2, Highbury Crescent, N.
1878 STOKES, Sir WILLIAM, M.D., 5, Merrion Square North, Dublin. *Trans.* 2.
1884 STONHAM, CHARLES, 4, Harley Street, W. *C.S.* 3.
1878 STRUGNELL, FREDERICK WILLIAM, 45, Highgate Road, Highgate, N.W. *C.S.* 1.
1878 †STURGE, WILLIAM ALLEN, M.D., 29, Boulevard Dubouchage, Nice, France. *Trans.* 4.
1872 *SUTHERLAND, HENRY, M.D., 6, Richmond Terrace, Whitehall, S.W. *Trans.* 1.
1887 SUTTON, JOHN BLAND, 48, Queen Anne Street, W. *Trans.* 9. *C.S.* 2.
1882 SYMONDS, CHARTERS JAMES, M.S. (C.), 26, Weymouth Street, W. (C. 1888–9.) *Trans.* 11, *C.S.* 4.
1876 SYMONDS, HORATIO PERCY, 35, Beaumont Street, Oxford.
1885 TAIT, EDWARD SABINE, M.D., 48, Highbury Park, N.
1885 TAIT, HENRY BREWER, Lincluden, Sunnyside Road, Hornsey Lane, N.
1891 TATE, WALTER WILLIAM HUNT, 57, Lambeth Palace Road, S.E.
1868 TATHAM, JOHN, M.D., 12, George Street, Hanover Square, W.
1886 TAY, WAREN, 4, Finsbury Square, E.C.
1878 TAYLER, FRANCIS THOMAS, M.B., 224, Lewisham High Road, S.E.
1875 TAYLOR, FREDERICK, M.D., 20, Wimpole Street, W. (S. 1879–81, C. 1882–4.) *Trans.* 9, *C.S.* 2.
1889 †TAYLOR, HENRY HERBERT, 10, Brunswick Place, Brighton.
1890 TAYLOR, JAMES, M.D., 45, Weymouth Street, W.
1882 TAYLOR, SEYMOUR, M.D., 16, Seymour Street, W. *Trans.* 1, *C.S.* 1.
1885 †TAYLOR, W. C. EVERLEY, 34, Queen Street, Scarborough.
1886 TEALE, THOMAS PRIDGIN, M.B., F.R.S., 38, Cookridge Street, Leeds.
1890 THANE, EDGAR HERBERT, M.D., Wagga-Wagga, New South Wales.
1882 THIN, GEORGE, M.D., 22, Queen Anne Street, W. *Trans.* 1.
1886 THOMPSON, CHARLES HERBERT, M.D., Junior Constitutional, Piccadilly, W.
O.M. THOMPSON, EDMUND SYMES, M.D., 33, Cavendish Square, W. (C. 1880–2.) *Trans.* 1.
O.M. THOMPSON, Sir HENRY, 35, Wimpole Street, W. (C. 1867–8, V.P. 1886–7.) *Trans.* 3.
1887 THORNTON, JOHN KNOWSLEY, M.B., C.M., 49, Montagu Square, W. (C. 1890–1.)
1872 THORNTON, WILLIAM PUGIN, 35, St. George's Road, Canterbury. *Trans.* 5.

ELECTED

1885 THURSFIELD, THOMAS WILLIAM, M.D., Selwood, Beauchamp Square, Leamington.
1891 TOMSON, W. BOLTON, M.D., Park Street West, Luton, Bedfordshire.
1892 TOOTH, HOWARD HENRY, M.D., 34, Harley Street, W.
1887 TOTSUKA, KANKAI.
1874 TRAVERS, WILLIAM, M.D., 2, Phillimore Gardens, Kensington, W.
1884 TREVES, FREDERICK, 6, Wimpole Street, W. *Trans.* 7. (C. 1893.)
1882 TURNER, FRANCIS CHARLEWOOD, M.D., 15, Finsbury Square, E.C. (C. 1887–9.) *Trans.* 1.
1882 TURNER, GEORGE ROBERTSON, 49, Green Street, W. *Trans.* 6.
1888 TURNER, PHILIP DYMOCK, M.D., 95, Cromwell Road, S.W. *Trans.* 1.
1877 TWEEDY, JOHN, 100, Harley Street, W.
1878 TYSON, WILLIAM JOSEPH, M.D., 10, Langhorne Gardens, Folkestone. (C. 1886–8.) *Trans.* 5.
1881 UNTHOFF, JOHN CALDWELL, M.D., 46, Western Road, Hove, Brighton.
1868 VENNING, EDGCOMBE, 30, Cadogan Place, S.W. (C. 1876–8.) *Trans.* 2.
1890 VOELCKER, ARTHUR FRANCIS, M.D., B.S., 13, Welbeck Street, W. *Trans.* 1.
1886 WADE, CHARLES H., Stanfield, Torquay.
1868 WAGSTAFFE, WILLIAM WARWICK, Purleigh, St. John's Hill, Sevenoaks. (C. 1878.)
1886 *WAINEWRIGHT, BENJAMIN, M.B., C.M., 67, Grosvenor Street, W. *Trans.* 2, *C.S.* 2.
1885 WAKLEY, THOMAS, jun., 5, Queen's Gate, W.
1885 WALKER, CHARLES ROTHERHAM, M.D., 7, Grove Road, Leytonstone, E.
1890 WALLIS, FREDERICK CHARLES, M.B., B.S., 26, Welbeck Street, W.
1875 WALSHAM, WILLIAM J., 27, Weymouth Street, W. (C. 1882–4.) *Trans.* 5, *C.S.* 1.
1888 WALTERS, FREDERICK RUFENACHT, M.D., 20, Finsbury Circus, E.C. *C.S.* 2.
1888 †WARNER, PERCY, Woodford, Essex.
1891 WATERHOUSE, HERBERT FURNIVALL, M.D., 81, Wimpole Street, W.
1868 WATKINS, EDWIN T., M.D., 61, Guildford Street, W.C. (C. 1881–3.)
1879 DE WATTEVILLE, ARMAND, M.A., M.D., B.Sc., 30, Welbeck Street, W.
O.M. WEBER, HERMANN, M.D., 10, Grosvenor Street, W. (C. 1867–71, V.P. 1873–5.) *Trans.* 9.
1876 WEIR, ARCHIBALD, M.D., St. Mungho's, Great Malvern.
1868 WELLS, Sir THOMAS SPENCER, Bart., 3, Upper Grosvenor Street, W. (C. 1873.)
1882 WEST, SAMUEL, M.D., 15, Wimpole Street, W. (C. 1887–9.) *Trans.* 10, *C.S.* 2.
1874 WHEELHOUSE, CLAUDIUS GALEN, Hilary Place, Leeds. *Trans.* 1.
1868 WHIPHAM, THOMAS TILLYER, M.B., 11, Grosvenor Street, W. (C. 1878–80.) *Trans.* 13.
1874 WHISTLER, W. MCNEIL, M.D., 17, Wimpole Street, W.

ELECTED

1891 WHITE, CHARLES PERCIVAL, M.B., B.C., 144, Sloane Street, S.W.
1882 WHITE, EDWIN FRANCIS, Westlands, 280, Upper Richmond Road, Putney, S.W.
1890 WHITE, GILBERT B. MOWER, M.B., B.S., 105, Gower Street, W.C.
1883 WHITE, WILLIAM HALE, M.D. (*Hon. Secretary*), 65, Harley Street, W. (C. 1887–9. S. June, 1893.) *Trans.* 8, *S.C.* 2.
1883 WHITE, WILLIAM HENRY, M.D., 43, Weymouth Street, W. *C.S.* 1.
1882 WHITTLE, EDWARD GEORGE, M.D., 65, Dyke Road, Brighton.
1871 WIGHT, GEORGE, M.B., C.M.; 428, Liverpool Road, N.
1879 WILCOX, HENRY, M.B., Newlyn, Fleet, Hants.
1884 WILLCOCKS, FREDERICK, M.D., 14, Mandeville Place, W. *C.S.* 1.
O.M. WILLETT, ALFRED, 36, Wimpole Street, W. (C. 1872–5, V.P. 1889–91.) *C.S.* 1.
1890 WILLETT, EDGAR, M.B., 24, Welbeck Street, W.
1888 WILLIAMS, CAMPBELL, 24, Welbeck Street, W.
O.M. WILLIAMS, CHARLES THEODORE, M.D., 2, Upper Brook Street, W. (C. 1877–9, V.P, 1889–90.) *Trans.* 8.
1888 WILLIAMS, DAWSON, M.D., 25, Old Burlington Street, W. (C. 1893.)
1881 WILLIAMS, JOHN, M.D., 63, Brook Street, W. (C. 1885–6.)
1870 WILLIAMS, WILLIAM RHYS, M.D., Linden House, Bertle Road, Leamington.
1890 WILLIAMS, W. ROGER, 28, Winckley Square, Preston.
1876 WILLIAMSON, JAMES MANN, M.D., Ventnor, Isle of Wight.
O.M. WILLIS, FRANCIS, M.D., The Spa, Braceborough, Stamford.
1889 WILLS, WILLIAM ALFRED, M.D., 23, Lower Seymour Street, W.
1886 WILSON, ALBERT, M.D., Leytonstone, Essex.
1888 †WILSON, CLAUDE, M.D., C.M., Belmont, Tunbridge Wells. *Trans.* 2.
1891 WILSON, THEODORE STACEY, M.B., C.M., 65, Temple Row, Birmingham.
1890 WOOD, NEVILLE, 42, Elvaston Place, Queen's Gate, S.W.
1883 WOODCOCK, JOHN ROSTRON, Boston Spa, R.S.O. Yorkshire.
1879 WOODWARD, GEORGE P. M., M.D., Deputy Surgeon-General; Sydney, New South Wales.
1884 WORTS, EDWIN, 6, Trinity Street, Colchester.
1888 WYMAN, WILLIAM S., M.D., Red Brae, 18, Putney Hill, S.W.
1892 WYNTER, WALTER ESSEX, M.D., B.S., 30, Upper Berkeley Street, W.
1872 YEO, I. BURNEY, M.D., 44, Hertford Street, W. (C. 1881–3.) *Trans.* 8.

[*It is requested that any change of Title or Residence be communicated to the Secretaries before the 1st of July in each year, in order that the list may be made as correct as possible.*]

LIST OF MEMBERS.

ORIGINAL MEMBERS (ALPHABETICALLY).

Sir Henry Acland, M.D., F.R.S.
James Andrew, M.D.
Henry Arnott.
Richard Barwell.
Henry Charlton Bastian, M.D., F.R.S.
John Syer Bristowe, M.D., F.R.S.
Sir Wm. Henry Broadbent, Bart., M.D.
Bernard Edward Brodhurst.
Thomas Bryant.
Sir George Buchanan, M.D., F.R.S.
Thomas Buzzard, M.D.
William Cayley, M.D.
William Selby Church, M.D.
Edward Clapton, M.D.
Sir Andrew Clark, Bart., M.D., F.R.S.
John Couper.
John Croft.
William Howship Dickinson, M.D.
John Langdon Down, M.D.
Sir Dyce Duckworth, M.D.
Alfred B. Duffin, M.D.
Arthur Edward Durham.
John Eric Erichsen, F.R.S.
John Harley, M.D.
Christopher Heath.
Graily Hewitt, M.D.
Timothy Holmes.
Barnard Wight Holt.
Carsten Holthouse.
John Whitaker Hulke, F.R.S.
Sir George Murray Humphry, M.D., LL.D., F.R.S.
Jonathan Hutchinson, F.R.S.
J. Hughlings Jackson, M.D., F.R.S.
Sir William Jenner, Bart., M.D., F.R.S.
Sir George Johnson, M.D., F.R.S.
Sydney Jones.
Charles Kelly, M.D.
John Langton.
George Lawson.
Henry Lee.
Arthur Trehern Norton.
Thomas William Nunn.
John William Ogle, M.D.
Sir James Paget, Bart., F.R.S.
Frederick William Pavy, M.D., F.R.S.
Thomas Pickering Pick.
Richard Douglas Powell, M.D.
Sir Richard Quain, Bart., M.D., F.R.S.
J. Spence Ramskill, M.D.
John Russell Reynolds, M.D., F.R.S.
Sydney Ringer, M.D., F.R.S.
James Rouse.
John Burdon Sanderson, M.D., F.R.S.
Thomas Smith.
Reginald Southey, M.D.
Edward Symes Thompson, M.D.
Sir Henry Thompson.
Hermann Weber, M.D.
Alfred Willett.
Charles Theodore Williams, M.D.
Francis Willis, M.D.

ARRANGED ACCORDING TO DATE OF ELECTION.

1868 Constantine Holman, M.D.
Thomas Tillyer Whipham, M.B.
Christian G. H. Baümler, M.D.
John Cavafy, M.D.
Frederick James Gant.
James Grey Glover.
T. Henry Green, M.D.
Howard Marsh.
Arthur Bowen Richards Myers.
Charles Prentis.
Edgcombe Venning.
Sir Thomas Spencer Wells, Bart.
John Ford Anderson, M.D.
George Granville Bantock, M.D.
George Charles Bright, M.D.
Frank W. Cooper.
Julian Evans, M.B.
Edward Hooper May, M.D.
William Warwick Wagstaffe.
Edwin T. Watkins, M.D.
William Ogle, M.D.
James Edward Pollock, M.D.
Franz Oppert, M.D.
William V. Snow, M.D.
Charles Drage, M.D.
John Tatham, M.D.
Frederick Royston Fairbank, M.D.
Michael W. Rice, M.D.
William Henry Day, M.D.
John Meaburn Bright, M.D.
Louis Stromeyer Little.

1869 Robert Brudenell Carter.
Leonard William Sedgwick, M.D.
J. Warrington Haward.
Henry Frederick Augustus Goodridge, M.D.
Olliver Thomas Duke, M.B.

1870 William Rhys Williams, M.D.

1871 Julius Althaus, M.D.
Robert M. Gover, M.B.
Sir William Mac Cormac.
Alfred Playne, M.B.
William F. Butt.
George Wight, M.B.
Ebenezer Diver, M.D.
George Vivian Poore, M.D.
William Edward Stewart.

1872 Thomas Cooke.
J. Burney Yeo, M.D.
Henry Harris, M.D.
William Pugin Thornton.
Robert Liveing, M.D.

1872 Anderson Critchett.
J. C. J. Fenwick, M.D.
Andrew J. Myrtle, M.D.
Sir William Bartlett Dalby.
Thomas Ridge Jones, M.D.
George Slight, M.D.
Henry Sutherland, M.D.
William Wilberforce Smith, M.D.

1873 William Julius Mickle, M.D.
Robert William Parker.
David Lloyd Roberts, M.D.
George Henry Savage, M.D.
Heinrich Port, M.D.
Edwin Chisholm, M.D.
Thomas Churton, M.D.

1874 John Hammond Morgan.
Edward R. Rowland.
Claudius Galen Wheelhouse.
Charles Douglas F. Phillips, M.D.
W. M. Whistler, M.D.
Edward C. Stirling, M.D.
William Henry Bennett.
William Travers, M.D.
William Brown Holderness.
Andrew Clark.

1875 Thomas Barlow, M.D.
Sidney Coupland, M.D.
Clinton T. Dent.
C. D. B. Hale.
Frederick Bowreman Jessett.
Edward Liveing, M.D.
F. J. Marshall.
Edward Nettleship.
William J. Walsham.
Rickman John Godlee, M.S.
Arthur Paul Sherwood.
T. Gilbart Smith, M.D.
James Frederic Goodhart, M.D.
William Richard Gowers, M.D., F.R.S.
William Smith Greenfield, M.D.
Shirley F. Murphy.
Herbert W. Page.
Frederick Taylor, M.D.

1876 Arthur E. J. Barker.
Horatio Percy Symonds.
A. Balmanno Squire, M.B.
Archibald Weir, M.D.
David White Finlay, M.D.
Henry Greenway Howse, M.S.
Furneaux Jordan.
R. Clement Lucas, B.S.

1876 James Mann Williamson, M.D.
George Buckston Browne.
Arthur Edwin Temple Longhurst, M.D.

1877 Robert Hogarth Clay, M.D.
A. Pearce Gould, M.S.
Henry Radcliffe Crocker, M.D.
David B. Lees, M.D.
Walter Hamilton Acland Jacobson, M.B., M.Ch.
Isambard Owen, M.D.
William Ewart, M.D.
Henry Morris, M.B.
William Miller Ord, M.D.
Walter Rivington, M.B.
Edward Seaton, M.D.
Henry Ambrose Lediard, M.D.
Bernard Roth.
Henry Hugh Clutton.
Malcolm Alex. Morris.

1878 George P. Field.
Thomas Warner Lacey.
Thomas Colcott Fox, M.B.
Felix Semon, M.D.
Henry de Fonmartin, M.D.
C. H. Golding-Bird, M.B.
Donald Wm. Charles Hood, M.D.
Sir Joseph Lister, Bart., F.R.S.
Francis Thomas Tayler, M.B.
F. de Havilland Hall, M.D.
Storer Bennett.
Sir William Stokes, M.D.
William Allen Sturge, M.D.
William Joseph Tyson, M.D.
William Johnston, M.D.
Charles Robert Bell Keetley.
William Appleton Meredith, C.M.
Frederick William Strugnell.

1879 William Edward Burton.
James Magill, M.D.
Wm. John Vereker Bindon, M.D.
Edward Markham Skerritt, M.D.
Henry Wilcox, M.B.
James Inkson, M.D.
John Abercrombie, M.D.
F. G. Dawtrey Drewitt, M.D.
Stephen Mackenzie, M.D.
William Harrison Cripps.
Francis Patrick Staples.
Geo. Courteney Henderson, M.D.
Thomas John Maclagan, M.D.
Henry Davy.
Thos. Walter Harropp Garstang.
George Lichtenberg, M.D.

1879 Charles W. Mansell Moullin.
John Reuben Lunn.
Armand de Watteville, M.D.
George P. M. Woodward, M.D.
J. Neville Davies-Colley, C.M.
Robert Peel.
Frederic S. Dennis, M.D.

1880 T. Mark Hovell.
Wyndham Cottle, M.D.
Henry Francis Baker.
Bernard O'Connor, M.D.
Charles Edward Beevor, M.D.

1881 George Henry Makins.
Robert William Burnet, M.D.
James Kingston Fowler, M.D.
Charles Edward Harrison, M.B.
Malcolm Macdonald McHardy.
Rushton Parker.
John Williams, M.D.
Montagu Lubbock, M.D.
James Black.
William Pasteur, M.D.
Henry Fraser Stokes.
John Caldwell Uhthoff, M.D.
Henry Treutham Butlin.
H. A. Powell, M.A.

1882 George Robertson Turner.
E. Noble Smith.
Robert William Goldie.
Frederick Charles Barker, M.D.
William Henry Kesteven.
Frederic Morell Mackenzie.
A. T. Myers, M.D.
Daniel Colquhoun, M.D.
Seymour Taylor, M.D.
Francis Charlewood Turner, M.D.
Philip Henry Bindley, M.B.
Edward George Whittle, M.D.
D. H. Goodsall.
Frederick Henry Spooner, M.D.
J. W. Dennis Dallaway.
Frederick Haycraft Berry, M.D.
Herbert Collier, M.D.
Samuel West, M.D.
Emile Emond, M.D.
Eugene Goddard, M.D.
Charters James Symonds.
Angel Money, M.D.
C. F. Coxwell, M.B.
George Allan Heron, M.D.
Augustus Joseph Pepper, M.B.
Harrington Sainsbury, M.D.
George Thin, M.D.
Edwin Francis White.

1883 Charles Gross.
Anthony A. Bowlby.
Cecil Yates Biss, M.D.
Percy Kidd, M.D.
William Henry White, M.D.
George Oliver, M.D.
Hubert Montague Murray, M.D.
Robert Fitzroy Benham.
William Henry Allchin, M.B.
John Mitchell Bruce, M.D.
William Arbuthnot Lane, M.S.
Bernard Pitts.
William Hale White, M.D.
William Coode Adams, M.B.
William Anderson.
Robert Leamon Bowles, M.D.
George Henry Jackson.
George Hunt Orton, M.B.
John Liston Paul, M.D.
Thomas Laurence Read.
Frederick Thomas Roberts, M.D.
Charles Alfred Ballance, M.B.
John Hopkins.
John Rostron Woodcock.

1884 Frederick Willcocks, M.D.
R. Percy Smith, M.D.
Edgar Duke.
John Mackern, M.B.
Paul M. Chapman, M.D.
Wilmot Parker Herringham, M.B
Philip Henry Pye-Smith, M.D. F.R.S.
Charles Stonham.
Dudley Wilmot Buxton, M.D.
Edwin Worts.
Seymour J. Sharkey, M.B.
Frederick Treves.
John James Pringle, M.B.
Frederick Lucas Benham, M.D.
Walter Edmunds, M.D.
Stephen Paget.
Lambert Hepenstal Ormsby, M.D.
John Poland.
Edwin Leonard Adeney, M.D.
Victor Horsley, F.R.S.
Henry Carr Maudsley, M.D.
Bilton Pollard.

1885 Frederick Spicer, M.B.
Herbert Larder.
A. Hughes Bennett.
James Berry.
Frederick Walker Mott, M.D.
George Newton Pitt, M.D.
W. C. Everley Taylor.
Sidney Philip Phillips, M.D.
A. W. Mayo Robson.
Thomas Wakley, jun.
Herbert William Allingham.
Thomas William Thursfield, M.D.
Alexander Dalton Murray, M.B.
Robert Maguire, M.D.
Robert Alexander Gibbons, M.D.
Thomas Fitz-Patrick, M.D.
Henry Brewer Tait.
Charles Rotherham Walker, M.D.
Richard Caton, M.D.
Arthur Henry Robinson, M.D.
Edward Sabine Tait, M.B.
William Bruce Clarke.
Charles Barrett Lockwood.
Reginald J. Ryle, M.D.
J. Michell Clarke, M.B.
Henry George Armstrong.
Roderick Maclaren, M.D.
W. Watson Cheyne.
Edward Liveing Fenn, M.D.

1886 Thomas Dixon Savill, M.D.
John Cahill.
Charles Henry Wade.
Benjamin Wainewright.
Waren Tay.
William John Penny.
William Henry Battle.
James Hardie, M.D.
Francis Henry Hawkins, M.B.
R. Hingston Fox, M.D.
Henry Edward Juler.
John Ward Cousins, M.D.
Joseph Frank Payne, M.D.
T. Pridgin Teale.
H. H. Lankester.
Arthur T. Davies, M.B.
Charles Herbert Thompson, M.D.
Arthur Quarry Silcock.
Henry Handford, M.D.
Alfred Scott.
Albert Wilson, M.D.

1887 Archibald E. Garrod, M.D.
H. T. Rutherfoord, M.B.
Kankai Totsuka.
Thomas Oliver, M.D.
Francis George Penrose, M.D.
Samuel Herbert Habershon, M.D.
John Knowsley Thornton.
John Bland Sutton.
Oswald Auchinleck Browne, M.B.
Albert C. Butler-Smythe.
Joseph Arderne Ormerod, M.D.

1887 C. J. Arkle, M.D.
J. H. E. Brock, M.B., B.S.
Francis William Clark.
A. H. Weiss Clemow, M.D., C.M.
E. Hurry Fenwick.
Henry William Freeman.
R. Lawford Knaggs, B.C.
John D. Malcolm, M.B., C.M.
Sidney Martin, M.D., B.S.
Thomas Horrocks Openshaw, M.B.
1888 A. G. Barrs, M.D.
J. W. Batterham, M.B., B.S.
Montagu Handfield-Jones, M.D.
Alfred Rice Oxley, M.D.
Arthur Roper.
Robert Henry Scanes Spicer, M.D.
Campbell Williams.
Frederic S. Eve.
Alexander Morison, M.D.
Frederick Page, M.D.
Frederick J. Smith, M.B.
Frederick R. Walters, M.D.
Claude Wilson, M.D., C.M.
Charles H. Gage-Brown, M.D.
Arthur Jamison, M.D., C.M.
J. H. Menzies.
Frank Ernest Roberts.
George Stoker.
Robert Ashton Bostock.
Hugh Armstrong.
Hyde Marriott, M.B.
Percy Warner.
J. F. James, M.B.
Edwin A. Barton.
W. P. May, M.B.
Philip D. Turner, M.D.
William S. Wyman, M.D.
Dawson Williams, M.D.
Augustus W. Addinsell, M.B., C.M.
John Anderson, M.D.
Henry French Banham, M.D.
George Haynes Hetherington.
David James Mason, M.D., C.M.
Walter G. Spencer, M.S., M.B.
1889 Theodore Dyke Acland, M.D.
Raymond Johnson, M.B., B.S.
H. Davy Rolleston, M.B., B.S.
P. MacBride, M.D.
D. Newman, M.D.
Herbert Elwin Harris, M.D.
John E. Ranking, M.D.
William Alfred Wills, M.B.
Edward Ashby Fardon.

1889 Wm. Alexander Carte, M.D., M.Ch.
Stanley Boyd, M.B.
George Ezra Halstead, M.D., B.S.
Edward Stewart, M.D.
Henry Herbert Taylor.
John Duncan, M.D.
Wm. Wallis Ord, M.B., B.Ch.
Leonard Arthur Bidwell.
Arthur J. M. Bentley, M.D.
Francis R. B. Bisshopp, M.B.
Henry Percy Dean, M.B., B.S.
Louis Albert Dunn, M.S.
Percy Flemming, M.B.
Daniel Mackay Forbes.
H. Pennell Hawkins, M.B., B.S.
D. M. Ross.
Lauriston Elgin Shaw, M.D.
1890 John Rose Bradford, M.D.
J. Fletcher Little, M.B.
Robert Robertson, M.D.
Ernest Solly, M.B.
James Taylor, M.D.
Francis O. Buckland, B.A., M.B., C.M.
E. Baxter Forman, M.D.
G. Somerville Robinson.
Edmund W. Roughton, B.S.
Edgar Willett, M.B.
Thomas H. Rickard Crowle.
Robert A. Bindley.
James Calvert, M.D.
H. Roxburgh Fuller, M.D.
Arthur F. Voelcker, M.D.
Neville Wood.
W. Roger Williams.
Gilbert B. M. White, M.B., B.S.
Frederick Charles Wallis, M.B., B.S.
Alfred Parkin, M.S.
George A. Hawkins-Ambler.
James Harper, M.D.
Walter Henry Brown.
John Walter Carr, M.D.
Ernest Le Cronier Lancaster, M.B., B.Ch.
Patrick Manson, M.D., C.M.
Miles Miley, M.A., M.B.
Edgar Herbert Thane, M.B.
Charles William Chapman, M.D.
Michael G. Foster, M.B., M.A.
1891 Frederic Francois Burghard, M.D., M.S.
H. E. Leigh Canney, M.B.

1891 Roger Neville Goodman, M.B.
Herbert Furnivall Waterhouse, M.D.
Leonard Remfry, M.D.
Walter William Hunt Tate.
William Lee Dickinson, M.B.
Greville MacDonald, M.D.
J. Kingston Barton.
Henri Dardenne, M.B.
J. Dundas Grant, M.D.
W. Kington Fyffe, M.B., B.C.
Albert Carless, M.S., M.B.
Bolton Tomson, M.D.
Harry Littlewood, M.D.
Hector W. G. Mackenzie, M.A., M.D.
Chas. Percival White, M.B., B.C.
Arnold Caddy.
Theodore Stacey Wilson, M.B., C.M.

1892 William Hunter, M.D.
Frank Thomas Paul.
Edward Cotterell.
Frank Richardson Blaxall, M.D.
Walter Essex Wynter, M.D., B.S.
Damer Harrison.
Henry Widenham Maunsell, M.D.
John Alfred Masters, M.D.
Walter Giffard Nash.
J. Stephenson Selwyn Harvey, M.D.

1892 Ewen Carthew Stabb.
Edward John Lewis, M.B., B.C.
Henry Betham Robinson, M.D., M.S.
Richard James Herbert Scott.
Howard Henry Tooth, M.D.

1893 John Ernest Paul, M.B.
J. W. Bond, M.D.
Harry Campbell, M.D.
W. Soltau Fenwick, M.D.
Ernest Alfred Snape.
Lewis G. Glover, M.B., B.C.
Solomon Charles Smith, M.D.
William Bracewell Mercer, M.B., B.C.
Robert Henry Cole, M.B.
Donald Rose Paterson, M.D., C.M.
Edward Henry Ezard, M.D., B.Sc.
Walter Spencer Anderson Griffith, M.D.
Alfred Theodore Rake, M.B., B.S.
Francis Charles Abbott, M.B., B.S.
James William Browne, M.B.
Edwin Harding Lendon, M.B.
R. J. Bliss Howard, M.D.
Henry Jones Curtis, M.D., B.S.

REPORT

OF THE

COUNCIL OF THE CLINICAL SOCIETY,

MAY, 1893.

THE COUNCIL has the pleasure of reporting that the prosperity of the Society has been fully maintained.

The Members now number 522, of whom 25 have been elected during the session. Eleven have ceased to be Members, and the Council regrets that four of these have been lost by death, viz. Dr. James Anderson, Dr. Ball, of Paris, Mr. Charles Cotes, and Dr. William Hope.

In the financial report of last year it was shown that the Society had, on the 30th of April, a balance of £240 12*s.* 9*d.* This balance was unusually large, by reason of the accumulation of subscriptions for sixteen months against the expenditure of twelve months. The Treasurer has now to report a larger balance—£309 11*s.* 3*d.* In the earlier part of the financial year it seemed probable that the ordinary balance would be insufficient to meet the expense of printing the Incubation Report, and that it would be necessary to trench upon the £600 invested by the Society in Consols. It is a matter of great satisfaction to the Council to state to the Society that, after the payment of £117 15*s.*, a balance actually exceeding the working balance of last year, and still larger than the balance of the preceding year, will be available for the uses of the Society in the coming year. The balance is in fact increased by the sum of £26 5*s.* paid

in advance by inadvertence, and therefore not chargeable on next year's income.

The report on the Periods of Incubation and Contagiousness of certain Infectious Diseases has recently been distributed to the Members. The investigation has been conducted with such thoroughness and judgment that the Society may justifiably claim that the report is the best work of its kind in existence. The Council is of opinion that the warmest thanks of the Society are due to the Committee for a report which cannot fail to reflect great credit upon the Society, and that special recognition should be accorded to the Chairman of the Committee, Dr. Broadbent, and to the Honorary Secretary and Editor, Dr. Dawson Williams.

TREASURER'S STATEMENT OF ACCOUNTS,
MAY 1, 1892, TO APRIL 30, 1893.

	Dr.	£	s.	d.		Cr.	£	s.	d.
1892-3	To Balance at Bank, 1st May, 1892 . .	240	12	9	1892-3	By Cost of *Transactions*, Vol. XXV:			
	„ 383 Subscriptions at 21*s.*	402	3	0		Paper, printing, binding, and delivery	171	8	6
	„ 18 „ received through Bank	18	18	0		Illustrations	47	18	6
	„ 27 Admission Fees at £2 2*s.*	56	14	0		„ Meetings:			
	„ Sale of *Transactions*:					Expenses of rooms (Rent, &c.) . .	105	0	0
	By the Publishers . . .	15	19	2		Refreshments	33	8	0
	„ Dividends on Consols	16	2	0		R. Coldrey, for attendance . . .	7	10	0
						Microscopes	1	0	6
						„ Treasurer and Hon. Secretaries:			
						Secretarial assistance	26	5	0
						„ „ (paid in advance)	26	5	0
						Commission to Collector . . .	15	15	0
						Printing and Stationery . . .	1	7	0
						Petty expenditure	5	0	0
						Bank postages	0	0	2
						„ Balance in hand	309	11	3
		£750	8	11			£750	8	11

Examined and found correct, *May* 17, 1893. { G. NEWTON PITT, M.D., W. BRUCE CLARKE, } *Auditors.*

WILLIAM M. ORD, M.D., *Treasurer.*
May 17, 1893.

W. B. HADDEN, M.D., A. PEARCE GOULD, M.S., } *Hon. Secs.*

Amount of Investments in hands of Trustees (Consols) £600.

BOSTON MEDICAL
NOV 15 1893
LIBRARY ASS'N.

COMMUNICATIONS.

I.—*A case of Intestinal Obstruction accompanied by Thrombus in the Abdominal Aorta extending down the iliac vessels.* By W. H. Brown. *Read October 14, 1892.*

I SAW the patient, a man of 58, with Dr. Mason, of Gomersal, near Leeds, on February 7, 1892. The history given was as follows:

The patient had enjoyed good health up to the preceding Monday (February 1). On the evening of that day he was seized whilst sitting in his chair with a sharp pain at the epigastrium. This pain lasted for about one hour, when he vomited a little partly digested food, after which he became easier. A few hours later the pain returned, and Dr. Mason was sent for, who administered a hypodermic injection of morphia; he then slept for some hours, and awoke free from pain. During the next three days he had occasional attacks of pain, and vomited once or twice, but did not appear to be very ill. Flatus passed at intervals. Two days before I saw him the pain grew worse, and the vomited matter became of a fæcal character. On my arrival a basin containing 3 oz. of liquid fæces was shown me. This he had vomited in the early morning. Upon examination I found the abdomen slightly distended, and resonant all over save in the left flank. He bore handling very well, and said he had no pain. Flatus had passed some forty-eight hours before.

The tongue was clean, pulse 100, temperature normal, countenance placid. An enema of two quarts of water had been given and had returned, bringing a few small fragments of fæcal matter.

On examining the rectum I found it collapsed, and quite empty so far as my finger could reach. As all urgent symptoms had disappeared, and as the amount of distension was so slight, I decided to wait longer before interfering, and arranged for the patient's removal to the infirmary, as his surroundings were not favorable for operation.

The next day he was brought to the infirmary, where I saw him on his arrival. The symptoms of obstruction of the bowel had not returned, but he now complained of intense pain in both lower limbs with loss of power. This he said had commenced the previous evening, whilst he was in bed. Upon examining the abdomen the distension had disappeared, and the abdomen seemed natural. The legs and thighs were cold, and the veins deeply outlined; sensation was diminished, and he could with great difficulty move his thighs. Tongue clean, pulse and temperature natural, but the face was slightly drawn and pinched.

As the signs and symptoms had assumed an entirely different character, and all the evidence of bowel obstruction had passed away, I had him put to bed and a little morphia given, as his pain was excruciating.

In the evening the skin of the legs, thighs, and lower portion of abdomen had a slightly mottled appearance resembling gangrene; loss of motion was complete, and sensation much impaired.

The house surgeon visited him twice during the night, and gave him more morphia as the pain increased in severity. The next morning the man was sinking rapidly; the lividity of the limbs had increased materially. There was no return of vomiting, and no distension of the abdomen.

The patient died at one o'clock.

Thorough inquiry was made as to any possible cause for his later symptoms, but no history of accident, recent or remote, could be elicited.

The post-mortem, made the next day by my colleague Dr. Barrs, gave the following result:

The body was well nourished, no abdominal distension. Legs, thighs, and abdomen up to level of navel showed extensive patches of extravasation of blood resembling gangrene. The viscera were healthy, brain and spinal cord normal.

General stinking peritonitis, fluid of a chocolate colour. The free border of the great omentum was fixed by a tight band to front of the top of sacrum. About five feet of small intestines had all the appearance of gangrene. The gangrene

was limited above by a distinct line of demarcation, and below in a similar manner. At one point there was a short piece of unaffected bowel in the centre of the gangrenous gut. The intestine below strangulation point to the ileo-cæcal valve measured eleven feet and was collapsed; the bowels above this point were greatly distended; the stomach contained a little fæcal fluid. The large intestine was empty.

The abdominal aorta was extensively diseased; many large patches of atheroma, some calcareous. The vessels were completely blocked about one inch above bifurcation, the block extending down both external iliacs to the femorals and internal iliacs to their division into anterior and posterior branches. The clot was firm and commenced to change colour, and adhered to sides of vessels. The distended vessels were hard and had an annulated appearance. The mesenteric vessels and all above the lower lumbar arteries were free from clot. No source of embolism being found, it was concluded that the clot was thrombotic in origin.

The surgical aspect of the case I have related appears to open out a condition of intestinal obstruction which is not by any means common. That so large an amount of strangulated intestine should give rise to so few symptoms, and further that these symptoms should have gradually disappeared, is, so far as I can learn, very rare.

I do not think any surgeon would have opened up the abdomen on the occasion of my first seeing the man, and twenty-four hours later what few symptoms there were had entirely disappeared, so much so that those who then saw him were inclined to doubt the accuracy of the history of the case. I feel, indeed, that I am adding to the difficulties of the diagnosis of intestinal obstruction, and putting the vexed question of early or late explanation a point further from being definitely settled.

I have not been able to meet with any record of a similar case. Had I opened the abdomen earlier, and released the band which tied down the intestine, I should have thought that possibly the manipulation had set up an inflammation in the diseased patch of the aorta and led to the formation of the clot.

Two views amongst others may be held satisfactory: one that the occurrence was purely coincident; the other that the strangulation may have been the means of causing an inflammatory outbreak in the aorta in the diseased patch. Personally I am not able to suggest that either of these is sufficient,

and am content to vouch for the facts as I observed them, leaving to others more skilled in the unravelling of pathological mysteries to point out what may be the true explanation.

The absence of distension ante mortem, and the freedom from pain on examination, are to me at any rate quite new features in cases of internal strangulation. Possibly a specialist might have detected sufficient reasons for operation earlier; I can only speak as a general surgeon. The pathological condition of the aorta is, I believe, rare, the recorded cases being chiefly in the thoracic portion of the vessel.

The sketch with the specimen of the aorta will, I hope, explain anything I may have left unsaid.

II.—*A Case of extensive Nævus of the Peritoneum.* By W. Arbuthnot Lane, M.S. *Read October* 14, 1892.

S. P., æt. 7 years, was admitted into Guy's Hospital on September 12, 1891. His family history was very good. At birth the child was observed to have a tumour on the right side of the abdomen, and it had gradually increased in size since.

On admission the right side of the abdomen was occupied by a large prominent tumour, which extended from near the middle line in front to the loin posteriorly, and from the margin of the thorax above to the iliac crest below. It appeared to involve the abdominal wall; but whether it was wholly in the wall, or whether it was intra-peritoneal and involving the wall secondarily, was very difficult to decide. In prominent portions of it, it was possible to detect fluctuation over an area of about 3 inches or less. The skin was not involved, nor was there any pain on pressure. Its bulk was not influenced by forcible compression.

On September 14 the outer portion of the tumour was freely exposed, it being necessary to divide the abdominal muscles, the deeper aspect of which appeared to be involved in the tumour. Several large cysts, some nearly as big as an orange, were opened. They contained liquid blood, and were smooth and polished on their inner aspect. Besides these larger cysts there were an immense number of smaller ones, whose contents and structure were precisely similar. The tumour appeared to start in the outer surface of the peritoneum, and not to extend, except in the form of livid projections, into the peritoneal cavity. It extended upwards beneath the diaphragm, and backwards into relation with the kidney, but the large bulk of the tumour occupied the side of the abdomen. A great deal of blood was lost in excising the greater portion of the tumour, of which it was estimated four fifths were removed; and as the child's pulse became very rapid, 160 or more, and very feeble, about a pint and a quarter of normal salt solution was introduced into the circulation, with the result of at once relieving us of great anxiety.

The child was discharged on October 4, with a hardly perceptible difference between the two sides. In the beginning of this year, 1892, the child continued in the same condition, there not being the slightest indication of any return of the growth. The tumour proved to be nævoid in structure, and was apparently degenerating rapidly. It is the only example of nævus of the peritoneum that I have heard of; and although I have looked up the literature of the subject, I can find no description of a similar case. I therefore thought it worth while bringing it before this Society.

III.—*Case of Traumatic Aneurysm of the External Iliac Artery in a boy six years of age.* By H. H. Clutton. *Read October* 14, 1892.

A WOUND of the external iliac artery, spontaneous cessation of hæmorrhage, and the subsequent formation of a circumscribed traumatic aneurysm must be a very rare event. It seems desirable, therefore, to place this isolated case on record.

On May 24, 1891, I was summoned by Messrs. Pitts and Holland, of Chelmsford, to see a case which, they stated, was a traumatic aneurysm of the external iliac artery.

The following history was supplied by Mr. Pitts, who had seen the case from the commencement:—A boy, aged 5½ years, on April 29 was presented with a pocket knife, and a few hours afterwards began to use it to cut some cake. In trying to shut up the knife he placed it against his right side, and in so doing ran it into his abdomen. The knife dropped out of the wound, and the boy ran in terror to the house, a distance of 120 yards. There he became faint, and was caught up by his mother and carried indoors. Mr. Pitts was immediately sent for, and found the boy blanched and collapsed, but there had been very little external bleeding, and there was practically none at the time of the examination. There was a wound 1½ inches above the centre of the right Poupart's ligament, such as would be made by a stab with a pocket knife about ¼ inch in the perpendicular direction. There was a rounded swelling of a pale blue colour beneath the wound, but there was no indication that a large artery had been wounded. The boy, however, complained of "a trickling down his leg." He was placed in bed with his legs drawn up, and given small doses of opium every four hours.

The next morning, April 30, his temperature was 101·5°. There was the same rounded swelling, and, on handling, some emphysematous kind of crackling was felt over an area of about 8 inches, which extended down the thigh, over the femoral vessels. There was marked tenderness in the iliac fossa, extending to the median line of the abdomen. No difference could be detected in the temperature of the two limbs, and there was no œdema of the extremity. The tempe-

rature slowly fell, and the swelling and crepitation diminished till May 4, when distinct pulsation was felt and a loud blowing murmur was heard over the tumour, which had become more distinctly defined in its outline. The bruit could be heard and the thrill felt some distance below Poupart's ligament along the femoral artery.

May 14.—The crepitation had almost disappeared.

May 20.—A distinctly circumscribed tumour in right iliac fossa could be felt, of about the size of a small walnut, pulsating with a loud bruit. No pain or tenderness on examination.

At the consultation held on May 24 the following note was made:—"In the right iliac fossa, in the line of the external iliac artery, but on its outer side, 1½ inches above Poupart's ligament, is a pulsating tumour with an aneurysmal expansion and a loud bruit. The bruit can be heard and the thrill felt as far as the apex of Scarpa's triangle. The aneurysm appears to be about the size of the last phalanx of the thumb. There is a small scar in the skin, on the outer side, between the swelling and the anterior superior spine of the ilium, but this is freely moveable, and there is no inflammatory infiltration between the skin and the sac. The aneurysm is beneath the abdominal wall, but some distance above the origin of the epigastric artery. Compression also of the external iliac artery immediately above Poupart's ligament, where the epigastric arises, does not stop the pulsation of the aneurysm, but rather increases it. Compression of the external iliac above arrests the pulsation. No difference in the temperature between the two limbs can be detected with the hand, but the arteries below are weaker than on the left side."

We came, therefore, to the conclusion that the aneurysm really involved the external iliac artery, and was distinctly circumscribed. As there was no surrounding infiltration, and the aneurysm was not increasing in size, we decided that it would be best to postpone the operation a little longer. We thought that it was just possible a spontaneous cure might take place, and that, even if it did not, the collateral circulation would be more thoroughly established by a little further delay; and lastly, that the child's general health, which was not quite normal, would improve.

June 15.—The local condition was found to be exactly the same. There was no obvious increase or decrease in the size of the aneurysm, and the same pulsation and bruit could be felt and heard as before, but the boy's general health had much improved. An operation, for which he had been care-

fully prepared, was therefore undertaken at Chelmsford, with the assistance of Messrs. Pitts, Holland, and Martin.

After the whole limb had been wrapped in cotton wool and a bandage, an incision was made in the linea semilunaris, just above the internal abdominal ring, and the aneurysm exposed. The spermatic cord was found lying over the centre of the aneurysm, which sprang from the outer side of the external iliac artery. The sac appeared to be directly continuous with the coats of this vessel. It was thought best to ligature the artery immediately above the aneurysm without disturbing the sac. The peritoneum was therefore opened, in the expectation that the artery would be more easily secured. This, however, proved to be a mistake, for the artery was subsequently much more easily reached by raising the peritoneum from the iliac fascia. A kangaroo-tendon ligature was passed round the external iliac artery, just above the aneurysm, which appeared to have its upper limit at the centre of this vessel. On tightening the ligature the pulsation ceased. After waiting a few minutes, to make sure that all pulsation had been arrested, Mr. Pitts and I fancied that we could again detect a very slight impulse in the sac. The incision was prolonged downwards, and another ligature applied to the external iliac artery between the aneurysm and Poupart's ligament. No branches from the main artery were met with in this dissection. The wound was carefully closed with silkworm gut sutures, including the peritoneum, where it had been divided, and a large dressing of cyanide gauze and wool applied. No drainage-tube was inserted. The operation was conducted throughout in the ordinary aseptic manner. The after treatment of the case was left entirely in the hands of Mr. Pitts at Chelmsford, who watched the patient most carefully to a successful issue. The highest temperature in the first twenty-four hours was 100·2°, and then varied between 98° and 99·5° for the rest of the first week. The dressing was therefore not changed till the 22nd, exactly a week after operation. Mr. Pitts's note at that date was as follows:—"The wound has healed by first intention, and I have removed two of the sutures. I cannot feel any pulsation in the aneurysm nor in the femoral. The leg is warm and good in colour, but the thigh is one inch larger than the other, and the leg half an inch larger. He is well in every other respect." At the end of the second week his temperature again rose to 100·2°, and on dressing the wound a small collection of pus was evacuated. After this the

wound healed rapidly and permanently. At the end of the third week he was considered to be so far out of all danger of any complications, that the nurse who had been sent from London to look after him was allowed to return home.

The boy was brought to me by Mr. Pitts for examination on October 14, four months after the operation, as it was thought advisable that he should be measured for an abdominal support. The cured aneurysm could be detected as a small hard lump without pulsation. The femoral artery could be felt below Poupart's ligament, but the pulsation was very feeble compared to that on the opposite side of the body. The limb was quite natural, and the boy was fat and healthy. There was very little bulging of the scar, but an abdominal belt was ordered as a precaution.

The case is interesting chiefly from the rarity of such an accident. A wound of so large an artery must usually result in a rapidly fatal hæmorrhage, but in this case there was so little bleeding at the time of the accident as to lead Mr. Pitts to think of other causes of shock than of a wounded vessel.

I would submit that the aneuyrsm either arose from a very small wound, which subsequently healed and then again expanded to form the sac; or the knife did not penetrate all the coats of the artery, and the damaged walls subsequently yielded before the blood-pressure. In the latter case the extravasated blood in the iliac fossa probably came from the smaller vessels which were wounded by the transit of the knife towards the main vessel. This would account for the absence of serious hæmorrhage at the time of the accident, and would appear on the whole to be the more probable interpretation of the case.

The method of ligature adopted was based on the view that the aneurysm was after all only a wounded vessel, and that a ligature above and below would be the ordinary course for such a case in its most recent condition. The circumstances were not much altered by the wounded vessel having become an aneurysm, and, provided the aneurysm itself were not touched, there was not much danger in isolating it from the circulation. Gangrene was not in my opinion likely to ensue if the ligatures were fairly close together.

IV.—*A case of Cicatricial Stricture of Œsophagus: œsophagotomy for removal of impacted Symonds' tube: complete division of stricture: no recurrence two years after operation.* By Frederic Eve. *Read October* 14, 1892.

ALICE D., æt. 17, was admitted to the London Hospital on July 26, 1889, for dysphagia.

History.—Twenty months before she swallowed one and a half teaspoonfuls of aqua fortis, and she was taken into the hospital for two weeks. After an interval of one month she was readmitted, and remained an in-patient for three months. At that time she could swallow solid food. Three months later difficulty in swallowing returned, and she was treated at the Golden Square Hospital both as out- and in-patient for three months, bougies being passed. She continued well for some months, after which she was re-admitted to the London Hospital, and subsequently again attended at Golden Square as an out-patient.

I first saw her on July 26, 1889, when a No. 11 bougie was passed through the stricture, which appeared to be low down in the neck.

Next day a No. 7 Symonds' tube was passed, and left in for the purpose of facilitating feeding and keeping up continuous dilatation.

On July 29 this was replaced by a No. 11, quite new and apparently in good condition.

July 31.—The House Surgeon in attempting to remove the tube pulled away the thread attached to it, leaving the tube in the stricture.

In the afternoon I made, under anæsthesia, a prolonged attempt to extract the tube with long forceps, but never once succeeded in catching its edge or moving it.

August 3.—I performed œsophagotomy on the left side of the neck as low as possible, and after opening the gullet on a sound, could see no signs of the tube. Even from the wound its edge could not be seized with forceps, owing apparently to its being tightly impacted, and the walls of the gullet overlapping its edge. On introducing a finger through the

œsophageal wound, the tube was felt a short distance below it. The incision into the œsophagus was then prolonged downwards with scissors, while its walls were drawn up with forceps until the edge of the tube was reached, when extraction was effected. The œsophagus was still further drawn up and snipped until all the narrowed part was divided. A soft rubber tube was inserted through the mouth past the wound, and the cut edges of the gullet were brought together with sutures. The external wound was left open and dressed with iodoform, sponges and cotton wool.

August 3, 9.30 P.M.—The patient vomited several times, and there was a profuse and continuous discharge of stringy mucus through the wound. Pulse 120, temp. 103°. Slinger's suppositories given, nothing through the mouth.

August 4.—Attempts to give nourishment through tube caused vomiting. Nutrient enemata given every four hours. Much discharge of saliva through mouth, and of mucus through wound.

August 5.—Condition much the same.

August 6.—Wound looks healthy. Temp. 99°. Two ounces of milk injected through tube into stomach were retained.

August 9.—Nourishment is now taken well through tube.

August 14.—Tube removed. On swallowing water a very little came out through wound.

August 15.—Twelve days after operation, milk swallowed without any escaping through wound, and after this no further escape was observed.

August 16.—No. 11 bougie passed without difficulty.

August 31.—Bougies have been passed daily, No. 18 being now admitted. Solid food given.

September 3.—Patient discharged, with instructions to come up to have bougies passed. Wound nearly healed.

She continued to swallow easily until the end of October, when for three days she experienced some dysphagia, and the left side of the neck seemed sore. Finally, on taking some medicine, it passed through the old opening. She was readmitted October 28, and bougies were passed, No. 20 being easily introduced. Was discharged on November 16, and shortly after that the wound closed permanently. I did not see her again until two years later, November, 1891, when I wrote asking her to come to the hospital. She stated that she had been quite well in the interval, and had had no difficulty in swallowing whatever.

I passed a No. 18 bougie without encountering any obstruction. The cure may therefore be considered permanent.

Remarks.—The points to which I especially wish to draw attention in this case are—1st, that the stricture was exceedingly resilient and obstinate. This is clearly shown from the patient having been on several occasions and for long periods under treatment by bougies, both at the London Hospital and at the Golden Square Hospital. The fact of her returning again and again to one of these institutions suggests that re-contraction took place rapidly on the cessation of active treatment. When she first came under my care, twenty months after the commencement of her trouble, she could only swallow liquid nourishment. 2ndly, after the operation of œsophagotomy with division of the stricture in August, 1889, she remained under observation until the end of November. Subsequently no bougies were passed until I saw her two years later, when no re-contraction of the stricture had taken place.

The operation itself may in some respects be compared to external urethrotomy for stricture of the urethra. But if one can draw any conclusions from only one case, the tendency to re-contraction after division of a stricture of the œsophagus appears to be less than in the case of the urethra. This may perhaps be accounted for by the difference in the surroundings of the two tubes; the œsophagus being quite free and unattached, while the urethra is firmly bound down to adjacent structures.

During the course of the operation I was surprised at the mobility of the œsophagus in the direction of its axis. It was such that I could draw up some length of the tube into the wound; and on the dead body I have found that from an inch to an inch and a half of the tube can be pulled up from the thorax. This is of importance, as it admits of division of a stricture extending even below the level of the thoracic aperture.

The late Sir Morell Mackenzie, in his work on *Diseases of the Throat and Nose,** quotes three cases in which œsophagotomy was done for fibrous stricture, but in each as a substitute for gastrostomy, the intention being to open the œsophagus below the obstruction. The patients were all children, aged three and a half, five, and nine years respectively. In two of the cases the gullet was unintentionally opened above the obstruction, and in none of them was the stricture divided.

* Vol. ii, p. 141.

Two patients died in twenty-four hours from shock, while the third died eight days after the operation owing to hæmorrhage from the internal jugular vein caused by septic ulceration.

There is no reason for supposing that this operation would be attended by an abnormally high mortality in adults. Unless too long postponed, it does not appear to me that it should be higher, if so high as in œsophagotomy for the removal of foreign bodies; for in the latter case severe injury and inflammation are often set up by the foreign body. Of 66 cases of œsophagotomy for the removal of foreign bodies collected by Gross, and 16 by Southam, in all 82, the mortality was 25 per cent.;* whereas the mortality of gastrostomy as quoted by Mr. Croft is 29·47 per cent.

It is not my intention to discuss the alternative treatment of strictures of the œsophagus by internal œsophagotomy or by electrolysis; but I desire to point out that in those cases of stricture of the œsophagus high up, in which gastrostomy would otherwise be indicated, œsophagotomy fulfils the same purposes, while it admits of a complete cure by division of the stricture. *This is proved by the case related.*

The same procedure may also be sometimes indicated in less severe cases of resilient stricture in the neck which have resisted other methods of treatment.

As regards the impaction and tearing of the Symonds' tube (which turned out so fortunately for the patient in the present case), I have only to suggest that the rim of the tube to which the threads are attached should be made stronger.

* *Cent. f. Chir.*, vol. xviii, 1890, p. 397.

V.—*Two cases illustrative of an operation of Complete Erasion of the Ankle-joint.* By W. Arbuthnot Lane, M.S. *Read October* 28, 1892.

I PROPOSE to describe briefly a simple operation by means of which the ankle-joint can be exposed most fully, and every particle of its synovial membrane can be seen and removed. It is not improbable that this method has been adopted by many others, but as I have never seen any description of such an operation, I venture to bring it before this Society, and to illustrate it by two cases. It is, of course, at once obvious that it is only adapted to the removal of tubercular material when the disease is limited to the ankle-joint itself, and when it has not extended to the subastragaloid joint. Yet even when this joint has become involved by extension, it may also be freely exposed and erased, though not with such perfect accuracy and certainty as can the ankle-joint alone.

The operation is performed in this manner:—An incision is made from the anterior margin of the tip of the inner malleolus across the front of the ankle, then backwards immediately below the external malleolus around the heel to within a measurable distance of the flexor longus hallucis tendon, everything being divided down to the bone. The only structures about the ankle-joint which are left uncut in this operation are the internal lateral ligament, the tendons of the flexor longus hallucis, flexor longus digitorum, and tibialis posticus, the posterior tibial vessels and nerve, and the superjacent connective tissue and skin.

The interior of the ankle-joint can then be exposed as readily as one separates the pages of a book, and the whole of its synovial membrane can be seen. The narrow prolongation of synovial membrane upwards between the tibia and fibula is shown more completely by dividing the inferior interosseous and anterior tibio-fibular ligaments. It is therefore apparent that no other joint in the body can be erased more perfectly or easily than this one if this method be adopted.

To expose the subastragaloid joint as well, it is necessary also to divide all the structures covering in this joint superiorly and externally, together with the interosseous ligament which connects these bones, and in extensive infiltration of the astragalus this bone may be removed with advantage. It is well to suture the cut surfaces of the several tendons accurately together, though this is not necessary for their satisfactory union. Some care is required in putting up the limb in plaster after the operation, that the fibula does not fall back a little from its normal position.* I will now illustrate very briefly the operation of erasion of the ankle-joint by two cases of tubercular disease of the synovial membrane of this articulation.

Case 1.—G. F. S., æt. 13, a very delicate half-starved boy, presented an advanced condition of tubercular disease of the ankle-joint from which he had suffered for more than a year. The amount of swelling suggested that the disease had extended to the subastragaloid joint, and probably also to the os calcis. He was operated on in the manner described on July 22, 1891, when the ankle-joint was found to be completely disorganised, the articular cartilage over the astragalus, tibia, and fibula coming away readily, and the subarticular layer of bone, being soft and inflamed, was readily removed with a sharp spoon. Though there was extensive burrowing upwards into the leg, and downwards about the heel, the subastragaloid joint had escaped. The branching cavities and the ankle-joint were cleansed as effectively as possible, and were filled with dry iodoform. Recovery was slow and tedious, but when the boy was last seen the condition of the foot was most satisfactory.

Case 2.—A. B., æt. 2 years, was admitted into Guy's Hospital under my care on March 10, 1892, with a large fluctuating swelling over the outer part of the ankle-joint and a smaller one over the inner aspect. She had suffered from tubercular disease of the ankle for about a year or more.

The joint was carefully erased in the manner indicated, every portion of diseased membrane being removed. The subastragaloid joint was not involved in the disease, while

* How this can be avoided is shown in another paper in this volume, entitled "Cases illustrating a New Operation for Dorsal Dislocation of the Head of the Femur, and some Points in the Surgery of the Hip-joint."

the articular surfaces of the tibia, fibula, and astragalus were only involved about their margins.

The case was dressed twenty-four hours after the operation, when the drainage-tube was removed and the limb was put in a permanent dressing, and was fixed by plaster-of-Paris bandages in a splint, the foot being placed with its inner margin at a suitable angle of deviation from the vertical, namely, one of about 45°.

The subsequent progress of the case was all that could be desired, the child recovering a very considerable amount of movement in the joint, and being able to walk firmly and gracefully.

VI.—*The conditions seen at an operation for Ventral Hernia, five and a half years after laparotomy for tubercular peritonitis.* By R. Lawford Knaggs, M.C. *Read November* 11, 1892.

In vol. xxi, p. 37, of the Society's *Transactions* I have recorded a case of tubercular peritonitis treated by laparotomy and washing out.

The condition of the peritoneum at the operation on July 7, 1886, is there described as follows:—"The uterus and ovaries were quite normal, and the intestines, mesentery, and parietal peritoneum (which was much thickened) were covered with myriads of pale pink gelatinous-looking tubercles, as big as hemp-seeds, thickly and universally distributed, and varying but little in appearance and size."

In vol. xxii, p. 427, a supplementary report is given of the patient's continued well-doing.

In October, 1891, the patient, E. N., who has grown into a strong, healthy, young woman, returned with an irreducible ventral hernia, containing omentum at the site of the incision. The rupture occasionally became much larger, and could only be reduced with difficulty by a medical man.

On November 6, 1891, this was operated upon with a satisfactory result. The opening in the aponeurosis was circular, and large enough to admit the index finger.

Though it was not possible to make much of an examination of the parts inside the abdomen, the following points were made out.

The omentum was perfectly normal in appearance, except that part that had been irreducible and adherent. This was like omentum that had been retained in a hernial sac for some time. During the operation a considerable quantity slipped out through the ring, so that a good opportunity was afforded of examining it.

In the original report the state of the omentum is not mentioned, probably because it was not seen at the operation.

The parietal peritoneum round the ring inside felt quite smooth to the finger. The hernial sac was not thick, but it was altered inside by inflammatory changes, such as might

have been expected in an irreducible hernia where many adhesions had been formed. It had numerous small pouches, into which nodules of the omentum had fitted.

A coil of intestine could be well seen through the opening. It was glossy, and had the appearance of healthy intestine. No sign of tubercle nor any evidence of the tubercular condition that existed five and a half years ago was detected.

Slight and imperfect as these observations necessarily are, they may be worth recording, not only as helping to complete the particular case, but because they throw some light upon what becomes of peritoneal tubercle when the patient gets well.

VII.—*A case of Hyperplastic (obliterating) Phlebitis or Phlebo-sclerosis affecting the larger veins.* By H. Handford, M.D. *Read November* 11, 1892.

THE subject of intermittent albuminuria has given rise to so much discussion, and to the expression of such widely divergent opinions as to its importance and significance, that the case I am about to relate possesses much general interest and some importance quite apart from the presence of the somewhat rare phenomenon of venous sclerosis proceeding to a very unusual degree.

Case.—*Intermittent albuminuria, cardiac hypertrophy, high vascular tension, general dilatation of the superficial venules, obliterative endarteritis, and phlebitis, the last nearly occluding the saphena and other large veins.*—G. D., æt. 30, a lace-maker, a tall, sparely built man, with dark hair going grey, has been out of sorts for two years and has lost weight. He suffers frequently from attacks of sick headache. He used to be quite strong, and has never had scarlet fever, rheumatism, or typhoid fever. He also denies having had gonorrhœa or syphilis, and there is no evidence of the latter beyond the vascular sclerosis. His family history is good.

He has complained for many months of pain in the right loin of an aching character, not influenced by pressure or movement of any kind, and sometimes replaced by a feeling of heat or cold.

The heart's apex-beat is just inside the nipple line, 3½ inches below the nipple, which is on the fourth rib, and 3¼ inches from mid-sternum, and is forcible and heaving in character. There is evidently hypertrophy, but little if any dilatation. There is a very distinct reduplication of the first sound audible at the apex; and at the base an accentuated aortic second sound, and a faint short systolic aortic murmur. The heart's action is quite regular, and it beats usually eighty times in the minute.

The radial arteries are narrow, contracted, indurated, but not tortuous; and the vascular tension is very high, as shown by the sphygmogram.

The temporals are very small and difficult to examine.

The first part of the aorta is probably a little dilated, as shown chiefly by the systolic murmur and by pulsation in the second right intercostal space.

Generally over the face, trunk, and lower extremities the small venous radicles are very distinctly dilated. Both internal saphena veins below the knee stand out prominently as shown in the photographs, which were taken in the *horizontal* position. To the touch they resemble tendons, for which they would be taken were it not for their anatomical position. There are no adhesions and no phlebitis. The veins can be rolled quite freely under the finger, but they cannot be flattened. In the horizontal position it is not possible to detect any flow of blood along the lower third of the main trunk on either side; but with the patient standing there appears to be a slight movement of blood in them. A similar condition, but to a less though varying degree, affects the external saphena veins and most of the branches of both internal saphenas, the radial, ulnar, and cephalic veins. But the jugular, superficial epigastric, and circumflex iliac veins appear normal.

The patient has never suffered from swelling of the legs or any pains or other symptoms such as arise from venous thrombosis and subsequent phlebitis; and, indeed, the condition is too wide-spread to render such an hypothesis tenable.

The urine on admission had a sp. gr. of 1010, and contained a marked cloud of albumen. No casts could be found on repeated examination, but there were numerous minute crystals of oxalate of lime. For about three weeks the urine collected at 6 A.M., 11 A.M., and 8 P.M. was examined separately every day. On one occasion all three specimens were free from albumen; but on all the other occasions the 11 o'clock urine contained a quantity varying from a minute trace to a good cloud, and had a sp. gr. from 1010 to 1020, but generally near 1010.

The 6 A.M. urine was always free, and its sp. gr. varied from 1016 to 1026, but was generally 1022.

The evening urine not unfrequently contained a trace, but then always much less than the 11 A.M. urine; its sp. gr. varied from 1020 to 1026.

On examination of the eyes there was a well-marked arcus senilis on both sides. Vision was good, and there was no change in the fundus.

As regards treatment, he was made to rest in bed for a few days, and took ten grains of iodide of potassium thrice daily, and a rhubarb pill containing one grain of calomel

every night or every other night. For a fortnight he was kept on light diet and fish; afterwards he took small quantities of meat. At the end of three weeks the iodide was omitted. For one week sulphate of soda and tincture of nux vomica were given instead. Afterwards the iodide was resumed for another three weeks.

Under treatment the reduplicated first sound of the heart very soon disappeared, and the vascular tension was much lowered, the radial pulses becoming quite soft.

The change in the veins was most marked. Though the coats remained thicker than normal, and the saphena veins could be rolled under the finger above the ankle, even while the tension was low, yet the vessel could be easily flattened, and evidently carried a good volume of blood.

The degree of the vascular sclerosis (arterial as well as venous) in a man of his age, as well as the remarkable diminution of the induration under the use of iodide of potassium, render it extremely probable that the lesion was syphilitic. But there was no other evidence of syphilis, and the patient persistently denied ever having been infected. But even assuming the syphilitic origin of the vascular lesion, such an advanced degree of sclerosis of the veins as to lead to the impression that they were obliterated fibrous cords, and that a portion might be excised without harm (a suggestion actually made to me), is very rare.

Neither is it quite clear that, if syphilitic, the *whole* morbid condition was of syphilitic origin. It is rather probable that in a patient with high vascular tension, and a tendency to arterial degeneration, the syphilitic poison picked out the weakened tissues, and specially affected the blood-vessels. Just as in a fatal case of a woman, recently under my care, the syphilitic manifestations were limited to the cancellous tissue of bones, including the cranium, sternum, ribs, and vertebræ (the latter affection causing paraplegia), without any trace of syphilis elsewhere.

There is no reason to assume lardaceous disease or any special syphilitic affection of the kidney. Neither is it likely that any very advanced degree of renal cirrhosis (granular kidney) exists at present. But I think it likely that, whether syphilis be an adjuvant cause or not, the vascular sclerosis will again steadily increase, the cardiac and renal changes advance, and his life will not be a long one.

Whether intermittent albuminuria is even purely *functional* or *physiological* I very much doubt. In the case I have

just described the albuminuria was typically intermittent, and though the absence of casts and of persistent low specific gravity made the evidence of renal cirrhosis incomplete, yet there could be no question of the cardio-vascular changes.

N.B.—Since the above was written Osler's *Principles and Practice of Medicine* has appeared, and in it (p. 667) the following occurs:

"Sclerosis of the veins—*phlebo-sclerosis*—is not at all an uncommon accompaniment of arterio-sclerosis, and is a condition to which of late a good deal of attention has been paid. It is seen in conditions of heightened blood-pressure, as in the portal system in cirrhosis of the liver, and in the pulmonary veins in mitral stenosis. . . . . In ordinary diffuse arterio-sclerosis the veins may also be involved, but rarely to a marked degree."

Bristowe and others have called attention to the same condition. This phlebo-sclerosis is not to be confounded with *multiple and recurring venous thrombosis*, of which I have recently recorded an *éclatant* example.

VIII.—*A case of Nephrolithotomy: large calculus.* By Donald D. Day (*introduced by* Howard Marsh). *Read November* 11, 1892.

Mr. President and Gentlemen,—Norwich and the county of Norfolk are, as you well know, celebrated for the frequency of calculous disorders. The museum of the Norfolk and Norwich Hospital has a collection of calculi, removed from the bladder by various operations, which can hardly be surpassed. It is, however, a curious circumstance that, though the vesical calculi amount to about 1300, until last summer (1891) it possessed no renal calculi except those removed post mortem.

I will briefly describe my case, and subsequently comment on the chief points of interest.

Mrs. A. F., æt. 32, sent for me one night in July, 1891, on account of violent abdominal pain. The presence of a large renal tumour was at once detected, and she was advised to go into the Norfolk and Norwich Hospital, which she did on July 25. Her history is as follows:—No family tendency to gout, rheumatism, or kidney disease, but one brother had died of phthisis. Her own health was good during childhood. For the past fourteen years she has suffered occasional pain in the right loin, lasting perhaps three days, with intervals of complete freedom. The pain was very sharp, but did not produce nausea, vomiting, or any urinary trouble. In June, 1890, during her second pregnancy, the pain became constant and severe, with exacerbations at times; the urine became thick and slimy, and she noticed a lump in the loin.

Her confinement in February, 1891, was natural. Since then the pain increased and the tumour grew, both conditions varying in severity in proportion to the scantiness or abundance of the urine passed.

Present condition.—A rather emaciated woman, with dry, rough skin, and worn, anxious expression. Pulse 90 per minute, soft and full; thoracic organs sound.

In the right lumbar region is a visible tumour, which feels as big as a cocoa-nut the long axis running downwards and

slightly forwards, and on this axis there is some mobility. No movements induced by respiration. The tumour feels tense and elastic, universally dull on percussion, the surface being smooth and rounded, and reaching from under the ribs down to the level of the anterior superior spine. Not much tenderness unless the pain is severe.

Micturition painless, but more frequent when pain is present. The urine, of total daily quantity about 30 oz., is pale and muddy, depositing pus about 7 oz., acid, albuminous; sp. gr. 1024. The microscope reveals pus and blood, but no crystals or tubercle bacilli.

There are no signs of disease of the left kidney.

It was evident that the right kidney was distended with pus, and the balance of evidence pointed to its being due to calculus rather than tubercular disease. I decided to explore and drain the kidney, as the patient was steadily losing ground.

Operation.—On August 7, the patient being etherised, I made the usual oblique incision as for lumbar colotomy, and at once came down upon the tense capsule; as soon as this was incised fœtid pus flowed freely. A rough stone was felt just under the capsule. To avoid laceration of the soft parts this was broken and removed with forceps, and its bed flushed with hot water. The finger exploring the cavity could feel no more stone, though the size of the tumour was not much lessened.

The patient was rather collapsed, so after puncturing the tumour with a needle to the depth of 2 inches in two or three places, and feeling no stone, I inserted a large tube and closed the wound, the amount of stone removed being 270 grs. whilst wet.

She rallied well from the operation; pus, faintly urinous, flowed freely from the wound, and the tumour was distinctly lessened. The urine passed *per urethram* remained the same, about 20 to 30 oz., but contained less pus. The wound healed entirely except the track of the tube, which lay at the anterior end of the incision.

On probing the wound a week after the operation distinct grating could be felt; pressure upon the front of the tumour caused pus to well out from the wound, and on "dipping" sharply downwards a hard substance could be felt, the distance from the end of the probe being estimated at 3 inches.

Second operation on August 20.—The patient being etherised, the incision was prolonged forwards 4 inches, being

carried right down to the capsule without exposing the colon or peritoneum. The original sac was much contracted, and in its front wall a point of stone was felt with some difficulty. The kidney substance was incised (the section being tough and anæmic), and by dilating with the finger a large stone was felt, very firmly fixed. This was broken off and removed. Beyond it lay the main bulk of the stone, the connection with the piece just removed being a narrow neck. By careful dilatation and incision of the kidney substance the stone was enucleated from its bed (this piece weighing just 2 oz.). Some small facetted stones were picked out with a scoop, and three broken branches disinterred after dilatation of their sac walls. The finger passed right through the kidney to the anterior capsule, and could be easily felt through the thin abdominal wall. Careful and prolonged search failed to find any more stone, so after copious flushing, tubes were inserted into the principal sacs and the wound closed, the abdominal muscles being united with buried sutures. Only one vessel required ligature, and the bleeding from the kidney substance was trifling, and easily controlled by pressure. Considering the length and severity of the operation, there was very little shock—in great contrast to the first operation. The after treatment of the case calls for little comment. The temperature rose to 102° that night, 101° next day, and then dropped to normal. The discharge from the wound was pale, inodorous urine, with little pus.

The urine passed was almost free from pus, about 10 oz. daily at first, gradually increasing to 40 oz. by the end of a month. The tubes were removed at the end of a fortnight, and the patient rapidly recovered health and strength. She left the hospital in six weeks on October 3, with a sinus discharging about 5 oz. of urinous fluid. In May the sinus was still open, but the general health was perfect, and she had gained nearly 2 stone in weight.

The calculus, thoroughly dried, weighs 1331 grs., its longest diameter being $3\frac{3}{4}$ inches, lying in the kidney in an antero-posterior direction in the shortest axis. Its shape is very suggestive of a dumb-bell, the handle being the body, which probably originated in a calyx in the centre of the kidney. It seems to have increased slowly until its extremities reached the capsule, when they took on more rapid growth until they far exceeded the original mass. The resemblance of the small facetted calculi to gall-stones is curious, especially as the finger passing through the cavity impinged upon the

PLATE I,

To illustrate Mr. Donald D. Day's Case of Nephrolithotomy.

Calculus weighing 1331 grains successfully removed by lumbar nephrolithotomy from a woman, A. F., æt. 32. The operation was performed in two stages. The calculus, which is mainly phosphatic, had apparently been growing for fourteen years.

Adlard and Son, Imp.

margin of the ribs just where the gall-bladder should be, the facetting evidently being caused by the friction of the loose calculi by the abdominal muscles over the firmly fixed mass.

The chemical analysis is as follows:

	Body.	Process.	Small loose stone.
Phosphate of lime . .	82 ...	66 ...	83·6
Phosphate of magnesium .	16 ...	32·3 ...	8·3
Oxalate of lime . . .	2 ...	1·7 ...	8·1
Urates	traces. ...	traces. ...	traces.
	100	100	100

In referring to previously recorded cases I can find no account of a stone of this size being successfully removed. Mr. Jacobson, in his Manual, quotes cases of 652 grs. and 473 grs., both ending fatally.

Dr. Shepherd of Montreal has published a fatal case, the weight being 4 oz. 7 drs.

Mr. Bennett May has recorded a case at a previous meeting of this Society, weight 473 grs., which was successful.

Mr. Myles, of Dublin, gives a case in the *Journal of Medical Science,* weight 282 grs., also successful.

The nearest in similarity to mine is a case published in the *British Medical Journal* for January 9, 1892, by Mr. Footner, of Tunbridge Wells. From a young adult man he removed successfully a branched calculus weighing 822 grs.

My case is an instance of what lumbar nephrolithotomy can accomplish in the hands of a general surgeon unused to special abdominal surgery, though it may prompt the thought that "fools rush in where angels fear to tread."

The diagnosis was that of pyonephrosis probably due to calculus, and the plan of treatment was to incise the tumour at its most prominent point in the loin and drain it, removing calculus if present, and to be guided by the course of events, and do a secondary nephrectomy if necessary. The end certainly justified the treatment, as being one way to success. But the question arises, would primary nephrectomy have succeeded better? I doubt if the patient could have had strength to stand the shock. With the presence of tumour and a large quantity of offensive pus I should not have cared to attempt removal entire through the loin, and I doubt if Mr. Knowsley Thornton would recommend extirpation through the abdomen in the hands of any average surgeon.

In his hands doubtless it would have been successful, but in mine the lumbar operation, though less brilliant, was safer, and it has left the patient with some amount of useful kidney. That this is not imaginary the gradual increase of urine passed after the operation proves, as one can hardly expect such a rapid increase of activity in the opposite kidney, seeing that her malady had existed fourteen years.

What I consider to have been the principal cause of the successful issue is due to the division of the operation into two stages, in the first of which I removed the posterior process and gave free vent for drainage, so that the patient was in better condition to stand the major operation. For this I can lay no claim for special credit, as it was the result rather of accident than design, but it might be a plan worth adopting in any similar case.

IX.—*A case of Double Empyema: simultaneous drainage of the pleural cavities: recovery.* By J. Walter Carr, M.D. *Read November* 11, 1892.

JOSEPH L., æt. 7¾, was admitted under my care into the Victoria Hospital for Children, Chelsea, on January 1, 1892, suffering from double empyema. The family history was good; no phthisis on either side. The boy had been considered delicate, but had had no special illness except measles four or five years before.

He was in good health until December 13, 1891, when he had a slight cough, and said he did not feel well; during the night he had a convulsion and was feverish. Next day there was dyspnœa, some blood-stained expectoration; skin hot and dry. On December 18 he developed pleurisy, and about December 22 there were well-marked signs of pleural effusion. On December 27 the breathing rapidly got worse, and the temperature became hectic. In all probability, as indicated by the very acute onset, there was pneumonia, most likely double from the first, with secondary pleural effusion, which, as so often happens in children, soon became purulent.

The boy was brought to the hospital from Chiswick, and his condition on admission, at 2 P.M. on January 1, was such as not to admit of a very thorough examination. He was much wasted, pale, with slight hectic flush on cheeks, urgent dyspnœa, alæ nasi working, respirations shallow, about 72 per minute; pulse 176, regular, very small and weak; temperature 102°. The respiratory movements were about equal on the two sides, but very slight, there being no expansion at the bases. There was good resonance in front on either side, but both axillæ were absolutely dull, and also the back on each side below a line about midway between the spine and angle of the scapula; very harsh breath-sounds and a few coarse râles were heard over the upper part of each lung, and distant bronchial breathing with diminished vocal resonance below. Heart not displaced, sounds normal; no sign of pericardial effusion. Urine free from albumen. On the right side an exploring syringe readily drew off pus; on the left

side a few drops were obtained, and the needle then became blocked.

Stimulants were given freely, but distinct difficulty in swallowing was noticed. The boy rallied a little, and at 5 P.M. the largest sized aspirating needle was introduced into the right side, from which the pus had already been found to come freely, and about 8½ oz. of thick inodorous pus were withdrawn.

Immediately afterwards the temperature was 102·4°; it subsequently fell to 100·6°: patient seemed somewhat relieved, took food fairly well during the night, and slept for two or three hours.

The first problem that now presented itself was whether, considering the critical condition of the boy, it would be safe at once to do a radical operation and establish free drainage, or whether to be content with repeated aspirations on both sides, so relieving the most urgent symptom, the dyspnœa, and gaining time before venturing upon more severe treatment. It seemed to me, however, that with pus freely forming in both pleural cavities any delay would tend to further weaken the child, and rather to diminish the prospects of ultimate recovery than to improve matters; in short, that the fact of the empyema being double tended to increase rather than to diminish the need for immediate operation. Moreover on the left side the pus had not escaped freely at the preliminary exploration, and free drainage of it would be likely to relieve the heart as well as the lung. Accordingly, the dyspnœa having been somewhat lessened by the aspiration of the right side, and the patient's condition being less desperate than on admission, next morning, January 2, at 9 A.M., Mr. Nairn, the house surgeon, after injecting ten minims of a 20 per cent. solution of cocaine, removed a portion of the eighth rib in the posterior axillary line on the left side; about 7 oz. of inodorous pus and some large flakes of lymph escaped, a large drainage-tube was inserted, and the wound dressed with cyanide gauze. The boy stood the operation well, and showed no sign of collapse or faintness during or after it; he felt no pain, only remarking when the rib was being cut by the bone forceps that his side ached a little. The discharge for the first few hours was very abundant.

During the next few days the child was distinctly better, pulse stronger, varying between 130 and 168; respirations from 52 to 56. Diarrhœa, which had been present before admission, was troublesome, averaging about six liquid motions

a day. Temperature fell after the operation to 97·8°, and subsequently oscillated irregularly between 99° and 101°. The right pleural cavity, however, was evidently refilling, and the question now arose whether to be content for the present with aspirating it, or whether to drain it freely like the other side. The first point to decide was whether the double opening would cause fatal embarrassment of respiration by collapse of both lungs, for as recently as 1886 it has been definitely stated in *Heath's Dictionary of Surgery* that "if a general empyema have been opened, and another form on the opposite side, it is obvious that the only surgical treatment for the second collection is by aspiration." As was pointed out, however, by Dr. Sidney Coupland and Mr. Pearce Gould in the paper on a case of double empyema which they read before this Society in December, 1890 (*Transactions*, vol. xxiv), the lung does not collapse when an empyema is drained as it does when the healthy pleural cavity is opened, owing to the adhesions which will almost certainly have formed; and, in fact, that draining an empyema and freely admitting air diminishes rather than increases the pressure upon the lung. Moreover a crucial test was afforded by the patient's condition after the first operation: had that been attended with further collapse of the left lung the dyspnœa must have been at once greatly increased, whereas it had from the first steadily diminished, and the physical signs indicated freer entry of air into the lung; it might, therefore, fairly be assumed that the same result would follow drainage of the other pleural cavity, especially as, the two empyemata having originated at or about the same time, the adhesions on each side might be expected to be equally firm.

But, granting the absence of any inherent danger in the simultaneous drainage, the question still remained as to whether it would be well to subject the boy to the risks from shock, &c., of a second operation when, even though the more urgent symptoms were relieved, he was still in a most precarious state. I thought, however, whilst one must admit the possibility of the right pleura recovering under treatment by aspiration only, that yet this was exceedingly improbable, and that so long as a large internal abscess remained undrained no real improvement could be expected; the temperature would almost certainly remain up, the diarrhœa continue, emaciation increase, the strength further deteriorate, and so, the shock of the first operation having been recovered from, further delay would only render the boy less rather than

better fitted to undergo the second one, which would in all probability be necessary sooner or later. He was certainly in a better condition now than he had been before the first operation, through which he had passed safely. It seemed, therefore, only right to adopt the ordinary rule of freely evacuating pus wherever it could be found, and to do so as soon as possible.

On January 6, therefore, four days after the first operation, the same quantity of cocaine as before was injected into the side, and Mr. Nairn excised a portion of the right sixth rib in the mid-axillary line. About 8 oz. of thick pus escaped; the lung was felt adherent in front and behind; it could not be reached by the finger opposite the wound. A large drainage-tube was inserted, and the wound dressed like the previous one. The local anæsthesia did not seem nearly so complete as it had been at the first operation, or perhaps the patient was more capable of feeling pain, but the collapse afterwards was certainly greater, for though the temperature only fell to 98·8° the respirations rose to 80, and were very laboured; the pulse was 180, feeble and irregular. The colour became very leaden. Four minims of liquor strychninæ were given hypodermically as a respiratory stimulant.

The child slowly rallied, but for some time, contrary to what I had expected, there was but little improvement in the general condition; the pulse varied from 140 to 160, respirations from 50 to 60, and the diarrhœa was even more severe than before; for some days also there was pain in swallowing, referred to the chest; throat quite healthy; temperature very irregular, varying between 98° and 103°.

The febrile symptoms were probably due in part to a double purulent otorrhœa which developed during the third week of January, and possibly also the original pneumonia had not subsided, as for some weeks subcrepitant râles were heard in the right lung, especially about the angle of the scapula.

The discharge from the right pleural cavity continued to be very abundant, but on the left side the lung rapidly expanded and the discharge notably diminished. On January 25, on the right side there was resonance and clear breathing to the fifth rib in front and to the angle of the scapula behind, absolute dulness below the latter point. The left lung seemed to have completely expanded, except for deficient resonance and very weak breath-sounds at the extreme posterior base. Heart's apex-beat in fifth left space in nipple line, distinct pulsation at the epigastrium.

Despite the continuance of irregular pyrexia the child's condition began slowly to improve; the pulse remained for a long time at about 140, the respirations at about 40 per minute. On January 29 the tube was removed from the left side, but a smaller one had to be inserted a few days later, owing to some pus reaccumulating in a small sinus which still remained. After this, from January 31, the temperature became normal and the diarrhœa ceased. Henceforward the improvement was rapid, the temperature remaining normal except for an occasional short rise due to the right side not draining quite freely. The tube on the left side was finally left out on March 10, but for several weeks previously the lung had practically completely expanded, only a narrow sinus being left. The right lung was much longer in expanding, and for some weeks pus was discharged freely from the wound; the tube was finally left out on April 5. Probably a more posterior opening close to the angle of the scapula, as Mr. Godlee advocates, and such as was made on the left side, would have afforded better drainage and led to more rapid closure of the cavity.

At the beginning of March patient had a curious attack of hæmoglobinuria; for some days the urine was very scanty, only 7 to 10 oz. per diem, got gradually darker, and at last almost porter-coloured; for five days it deposited about one third albumen on boiling, presented an enormous dark granular deposit, and gave the typical blood-pigment reaction with ozonic ether and guaiacum. The microscope showed a few red blood-corpuscles, a few granular casts, and amorphous débris. During the first three days of this attack there was some fever, but this seemed to be due to retention of pus in the right pleural cavity, for the temperature rapidly fell to normal when a larger tube was inserted, whereas the abnormal condition of the urine lasted four days longer; it then suddenly became perfectly healthy again, and remained so. I cannot explain the nature of this attack; there was nothing, I think, in the cyanide dressings to produce it. I am not aware of any cases having been recorded attributable to retained pus; the boy had not been out of bed; there seemed no possibility of his having been exposed to any chill, and no history could be obtained of any previous similar attack.

Patient was sent to Margate on April 13; at that time on the right side there was resonance in front to the fifth space, but still some dulness and very weak breathing in the lower part of the axilla and below the angle of the scapula,

but beside the spine a narrow band of resonance extended to the extreme base of the lung. On the left side the resonance was normal, and the breath-sounds were clear to the extreme base. Heart's apex-beat in the fifth space just inside the nipple line; still some epigastric pulsation. The boy returned from Margate on May 11, having gained 6 lbs. in weight; since then he has continued to gain weight. The right lung has completely expanded; the movements on both sides are now fairly good, with normal resonance and clear breath-sounds all over. He seems perfectly well in every respect, and his mother tells me that he is as well as he ever was in his life.

I have already referred to Dr. Sidney Coupland's and Mr. Pearce Gould's case of double empyema, and have nothing to add to the remarks which they made upon it, as my case entirely confirms the conclusions at which they arrived, particularly as to the advisability and safety of treating these cases by free drainage, provided that if possible an interval of a few days be given between the operations on the two sides in order to avoid the danger of excessive shock. But in view of the comparative rarity of the condition, and still more because the old belief probably still lingers that double empyema cannot be safely treated by simultaneous drainage of both sides, I thought it well to bring forward this case as a confirmation of previous ones; feeling, too, that though the ultimate result was so successful, yet on several occasions it was very nearly being very different, and that, as I had had no previous experience of the management of such cases, some suggestions might be elicited for still further diminishing the inevitable dangers attendant upon them.

Dr. Coupland and Mr. Gould appended to their paper a list of previous similar ones which have been recently recorded, and I have only found four which have been published since. In the *Lancet*, 1891, vol. i, p. 1385, a case is described by Dr. Handford, of Nottingham. The patient was a boy æt. 7½; he had been ill three weeks. Respirations were 56. On the left side dulness began at the fourth rib, and on the right at the fifth, and below the middle of the scapula behind on both sides. On February 13 the left side was opened in the sixth space in the posterior axillary line, and three quarters of an inch of rib removed. Ten days later the right side was opened in the seventh space below the angle of the scapula, and an inch of rib excised. The tubes were both left out in nine weeks, and three weeks later respiration was normal over the whole of both lungs.

Dr. Deanesly records two cases from the Wolverhamptom General Hospital in the *Lancet*, 1892, vol. i, p. 1299. (1) A girl æt. 10, ill three weeks; on December 23, 1891, the left side was aspirated and 22 oz. of pus removed. Next day a portion of the fifth rib was resected in the left posterior axillary line, and 38 oz. of pus evacuated. Five days later 3½ oz. of pus were withdrawn by aspiration from the right side, and eleven days after the first operation a small right empyema was drained by free resection of the eighth rib in the scapular line. The child left the hospital on February 1, and a week later both wounds were soundly healed.

(2) An infant, æt. 18 months, admitted March 21, 1892, with an indefinite history of illness. Pus was found on the left side, and next day half an inch of the eighth rib was resected in the scapular line without an anæsthetic; a large quantity of pus escaped. Twelve days later pus was found at the right base. Death occurred suddenly next day, before an operation could be performed, and the right pleural cavity was found full of thin pus.

Dr. F. Huber, of New York, records a case (*Archives of Pediatrics*, March, 1892, p. 203) in addition to two which he had previously published. A boy, æt. 6, had right lobar pneumonia followed by empyema; a free incision was made into the right pleura and a pint of pus evacuated. Six days after, signs of effusion having developed in the left pleura, a free incision was made into it; the tubes were removed two months later, and the boy made a complete recovery.

X.—*A case of Pancreatic Cyst: exploratory laparotomy: enucleation impracticable: death from shock.*

By J. W. Hulke, F.R.S. *Read November* 25, 1892.

THE number of recorded instances of cysts arising in connection with the pancreas is still so small that it has appeared to me that a short account of one which some time since came under my observation might be worthy of the notice of the Clinical Society. No analysis was made of the fluid it contained, but I surmise that an analysis would not have thrown any light on the nature of the cyst at the time the operation was undertaken; for, as in the analogous case of retention cyst of the gall-bladder, where the biliary fluid at first enclosed is ultimately replaced by a clear or turbid mucus without bile-stain, so it seems probable that pancreatic cysts originally containing the proper products of this gland would ultimately have substituted for these an indifferent mucoid contents.

As regards the diagnosis of the origin of the cyst the absence of such an analysis was, I submit, compensated by an exact appreciation of its anatomical relations, for these were such as, I think, leave no doubt as to whence it arose. They show also the technical difficulties which the surgeon may encounter, and which, as here, may make the completion of his task impracticable.

In March, 1874, I operated on a lady forty-three years old for a strangulated femoral hernia, from which she made a good recovery. She had also an abdominal tumour, thought, I was told, to be ovarian. Its history was not, however, quite consonant with this idea, since the tumour was known to have been present for very many years; so long, indeed, had it existed that the patient did not recollect when she first noticed it, and was inclined to connect it with a severe illness in childhood, marked by long-continued jaundice. From that time her digestion had ever been easily disordered. Milk, she found, particularly disagreed with her, so that for more than twenty years she had carefully avoided it and all food prepared with it.

At the herniotomy I availed myself of the opportunity of examining the tumour with the finger passed through the femoral ring and the other hand placed on the front of the belly, and I was particularly impressed by two things: 1, the fixity; and 2, the hardness of the tumour, suggestive of solidity or of a very tightly distended thick-walled cyst.

I next saw the patient on December 1, 1878—four years later, when I learned she had latterly suffered increasingly from gastric disturbance, and for the past three weeks had vomited daily. The bowels also were obstinately bound. She looked extremely ill, and was very emaciated and feeble.

The tumour now occupied the whole central area of the belly, extending from near the free tip of the ensiform cartilage almost to the pubes. Around it was a resonant band which, beginning above, on the left, at the point of first contact of the eighth with the seventh costal cartilage, thence crossed between the tumour and the right costal cartilages into the right flank, thence descended into the right inguinal region, crossed the lowest part of hypogastric region and ascended into the left flank, where it ceased a short distance above the level of the highest point of the iliac crest. Thus there was a distinct resonant interval between the upper border of the tumour and the liver, and also between its lower border and the pelvis. No fluctuation could be elicited.

The uterus, small, was pressed down and backwards, and its degree of mobility was such as to suggest that any connection of it with the tumour could be only of a very indirect, lax kind.

As it seemed probable that the vomiting and the obstruction were due to the pressure of the tumour on the stomach, and on the colon at the pelvic brim, and as her condition was so urgent that the question of an operation had to be immediately faced, I advised her to go into the Middlesex Hospital, which she did, her home circumstances being such that she could not have otherwise had the necessary attention. At a consultation with other members of the hospital staff the preponderant opinion was rather in support of the tumour being a multilocular ovarian cyst, its fixity being attributed to extensive adhesions.

On December 9, at 9 o'clock A.M., I made an exploratory laparotomy, dividing the abdominal walls by an incision between the navel and pubes. No adhesions to the anterior parietes were present. The front of the tumour was overlaid

7 o'clock P.M. she had rallied somewhat. The surface was warmer than it had been at noon, and the pulse was slightly less feeble. She had dozed at short intervals. In the night her exhaustion increased, and at 5 o'clock A.M., December 10, death occurred.

Permission to make a necropsy could not be obtained.

by the omentum, and on this being pressed out of the way the tumour was found to be retro-peritoneal, for on tracing its surface upwards and downwards, and also laterally, its peritoneal covering was found to pass directly from it into that lining the posterior abdominal parietes. When, for better examination of its relations, the tumour had been more thoroughly exposed by largely prolonging the abdominal incision upwards, the upper border of the tumour was found to be horizontally crossed by the pancreas, which was intimately connected with it. Immediately below this viscus, and parallel to its lower margin, the upper part of the tumour was also crossed by a large artery (splenic?); and again below this, and separated from it by only a slight interval, it was crossed by a large vein, which increased in size towards the right by the accession of several tributaries, the largest of which ascended vertically rather to the right of the axis of the tumour, and appeared to be the vena comes of a large artery which escaped from under the lower border of the pancreas and passed vertically downwards, grooving the front of the tumour, and disappeared from view at its lower border beneath a piece of small intestine, which, in a roughly horizontal course, crossed the lowermost limit of the tumour, being fixed to it by the expansion of peritoneum covering it and the front of the tumour. The large vein and artery just described were regarded as the superior mesenteric, and the small intestine as the duodenum removed from its normal relation with the pancreas and carried downwards by the enlarging tumour.

The peritoneum was divided parallel to these large vessels, and an attempt was made to enucleate the tumour, but the superior adhesions proved inseparable, and those behind seemed to attach it so closely to the aorta and vena cava that it was to be feared that any prolonged attempt to separate it from these parts might lead to injury of the vessels and uncontrollable hæmorrhage. Under these circumstances further endeavour to enucleate the tumour was abandoned; it was tapped, and much brownish glairy fluid escaped. The cyst wall was thick, and in it harder parts were noticed, giving the impression of their being adventitious bony plates. The opening in the cyst was brought to the surface and stitched to the integument, and a drain inserted. The external wound was closed, and dressings as after an ovariotomy were applied.

The shock from the operation was considerable. At

7 o'clock P.M. she had rallied somewhat. The surface was warmer than it had been at noon, and the pulse was slightly less feeble. She had dozed at short intervals. In the night her exhaustion increased, and at 5 o'clock A.M., December 10, death occurred.

Permission to make a necropsy could not be obtained.

by the omentum, and on this being pressed out of the way the tumour was found to be retro-peritoneal, for on tracing its surface upwards and downwards, and also laterally, its peritoneal covering was found to pass directly from it into that lining the posterior abdominal parietes. When, for better examination of its relations, the tumour had been more thoroughly exposed by largely prolonging the abdominal incision upwards, the upper border of the tumour was found to be horizontally crossed by the pancreas, which was intimately connected with it. Immediately below this viscus, and parallel to its lower margin, the upper part of the tumour was also crossed by a large artery (splenic?); and again below this, and separated from it by only a slight interval, it was crossed by a large vein, which increased in size towards the right by the accession of several tributaries, the largest of which ascended vertically rather to the right of the axis of the tumour, and appeared to be the vena comes of a large artery which escaped from under the lower border of the pancreas and passed vertically downwards, grooving the front of the tumour, and disappeared from view at its lower border beneath a piece of small intestine, which, in a roughly horizontal course, crossed the lowermost limit of the tumour, being fixed to it by the expansion of peritoneum covering it and the front of the tumour. The large vein and artery just described were regarded as the superior mesenteric, and the small intestine as the duodenum removed from its normal relation with the pancreas and carried downwards by the enlarging tumour.

The peritoneum was divided parallel to these large vessels, and an attempt was made to enucleate the tumour, but the superior adhesions proved inseparable, and those behind seemed to attach it so closely to the aorta and vena cava that it was to be feared that any prolonged attempt to separate it from these parts might lead to injury of the vessels and uncontrollable hæmorrhage. Under these circumstances further endeavour to enucleate the tumour was abandoned; it was tapped, and much brownish glairy fluid escaped. The cyst wall was thick, and in it harder parts were noticed, giving the impression of their being adventitious bony plates. The opening in the cyst was brought to the surface and stitched to the integument, and a drain inserted. The external wound was closed, and dressings as after an ovariotomy were applied.

The shock from the operation was considerable. At

7 o'clock P.M. she had rallied somewhat. The surface was warmer than it had been at noon, and the pulse was slightly less feeble. She had dozed at short intervals. In the night her exhaustion increased, and at 5 o'clock A.M., December 10, death occurred.

Permission to make a necropsy could not be obtained.

by the omentum, and on this being pressed out of the way the tumour was found to be retro-peritoneal, for on tracing its surface upwards and downwards, and also laterally, its peritoneal covering was found to pass directly from it into that lining the posterior abdominal parietes. When, for better examination of its relations, the tumour had been more thoroughly exposed by largely prolonging the abdominal incision upwards, the upper border of the tumour was found to be horizontally crossed by the pancreas, which was intimately connected with it. Immediately below this viscus, and parallel to its lower margin, the upper part of the tumour was also crossed by a large artery (splenic?); and again below this, and separated from it by only a slight interval, it was crossed by a large vein, which increased in size towards the right by the accession of several tributaries, the largest of which ascended vertically rather to the right of the axis of the tumour, and appeared to be the vena comes of a large artery which escaped from under the lower border of the pancreas and passed vertically downwards, grooving the front of the tumour, and disappeared from view at its lower border beneath a piece of small intestine, which, in a roughly horizontal course, crossed the lowermost limit of the tumour, being fixed to it by the expansion of peritoneum covering it and the front of the tumour. The large vein and artery just described were regarded as the superior mesenteric, and the small intestine as the duodenum removed from its normal relation with the pancreas and carried downwards by the enlarging tumour.

The peritoneum was divided parallel to these large vessels, and an attempt was made to enucleate the tumour, but the superior adhesions proved inseparable, and those behind seemed to attach it so closely to the aorta and vena cava that it was to be feared that any prolonged attempt to separate it from these parts might lead to injury of the vessels and uncontrollable hæmorrhage. Under these circumstances further endeavour to enucleate the tumour was abandoned; it was tapped, and much brownish glairy fluid escaped. The cyst wall was thick, and in it harder parts were noticed, giving the impression of their being adventitious bony plates. The opening in the cyst was brought to the surface and stitched to the integument, and a drain inserted. The external wound was closed, and dressings as after an ovariotomy were applied.

The shock from the operation was considerable. At

7 o'clock P.M. she had rallied somewhat. The surface was warmer than it had been at noon, and the pulse was slightly less feeble. She had dozed at short intervals. In the night her exhaustion increased, and at 5 o'clock A.M., December 10, death occurred.

Permission to make a necropsy could not be obtained.

by the omentum, and on this being pressed out of the way the tumour was found to be retro-peritoneal, for on tracing its surface upwards and downwards, and also laterally, its peritoneal covering was found to pass directly from it into that lining the posterior abdominal parietes. When, for better examination of its relations, the tumour had been more thoroughly exposed by largely prolonging the abdominal incision upwards, the upper border of the tumour was found to be horizontally crossed by the pancreas, which was intimately connected with it. Immediately below this viscus, and parallel to its lower margin, the upper part of the tumour was also crossed by a large artery (splenic?); and again below this, and separated from it by only a slight interval, it was crossed by a large vein, which increased in size towards the right by the accession of several tributaries, the largest of which ascended vertically rather to the right of the axis of the tumour, and appeared to be the vena comes of a large artery which escaped from under the lower border of the pancreas and passed vertically downwards, grooving the front of the tumour, and disappeared from view at its lower border beneath a piece of small intestine, which, in a roughly horizontal course, crossed the lowermost limit of the tumour, being fixed to it by the expansion of peritoneum covering it and the front of the tumour. The large vein and artery just described were regarded as the superior mesenteric, and the small intestine as the duodenum removed from its normal relation with the pancreas and carried downwards by the enlarging tumour.

The peritoneum was divided parallel to these large vessels, and an attempt was made to enucleate the tumour, but the superior adhesions proved inseparable, and those behind seemed to attach it so closely to the aorta and vena cava that it was to be feared that any prolonged attempt to separate it from these parts might lead to injury of the vessels and uncontrollable hæmorrhage. Under these circumstances further endeavour to enucleate the tumour was abandoned; it was tapped, and much brownish glairy fluid escaped. The cyst wall was thick, and in it harder parts were noticed, giving the impression of their being adventitious bony plates. The opening in the cyst was brought to the surface and stitched to the integument, and a drain inserted. The external wound was closed, and dressings as after an ovariotomy were applied.

The shock from the operation was considerable. At

7 o'clock P.M. she had rallied somewhat. The surface was warmer than it had been at noon, and the pulse was slightly less feeble. She had dozed at short intervals. In the night her exhaustion increased, and at 5 o'clock A.M., December 10, death occurred.

Permission to make a necropsy could not be obtained.

extremity being partially hidden by coils of small intestine. On removing it from the belly the pedicle was found to be twisted through three complete revolutions; on this account, as well as from the large size of the veins, it resembled an exceedingly thick umbilical cord. The pedicle was transfixed and tied in two halves with plaited silk. For security an encircling ligature was placed around the pedicle a centimetre below the point of transfixion; the spleen was cut away, and the wound closed in the usual manner. The patient was treated on exactly the same plan as after ovariotomy. For three days after the operation the temperature and pulse were as follows: temp. 99°, pulse 104; temp. 100°, pulse 96; temp. 99°, pulse 92, and then became normal. She never exhibited an unfavourable symptom, and left, convalescent, August 5, twenty-five days after the operation.

A perusal of the recorded cases of splenectomy shows clearly enough that success depends in a large measure on the treatment of the pedicle. I selected moderately thin but very strong plaited silk, rendered aseptic and preserved in absolute alcohol.

The spleen weighed sixteen ounces, and differed slightly in shape from the normal organ. The anterior border presented only a shallow notch, and explained why we were unable to recognise definitely the splenic nature of the swelling before undertaking an exploratory operation. Before removing the spleen I attempted to ascertain the existence or otherwise of a splenculus or splenculi, but failed to find one. Nearly every fœtus possesses a spleen and at least one splenculus. Sometimes as many as five splenculi are present, and occasionally, especially when the viscera are transposed, the spleen is represented by a number of splenculi clustering together like a bunch of grapes, or widely separated, reminding one of asteroids. Although I failed to find a satellite spleen, its absence must not be regarded as proved. Had I recognised a splenculus my intention was to avoid removing it with the main spleen, in the hope that perhaps it would have taken on compensatory hypertrophy, as is occasionally the case with accessory thyroids.

Before the operation three observations were made on the numerical proportion of the blood-corpuscles. The calculation gave the following results:

July 9.—Red cells, 4,000,000; white cells, 1 to 600 red.
July 11.—Red cells, 5,300,000; white cells, 1 to 642 red.
July 12.—Red cells, 4,200,000; white cells, 1 to 642 red.

After the operation the observations gave the following results:

July 19.—Red cells, 3,900,000; white cells, 1 to 380 red.

August 4.—Red cells, 4,900,000; white cells, 1 to 250 red. (Dr. Wethered.)

November 30.—Red cells, 4,850,000; white cells, 1 to 155 red; hæmoglobin, 70 per cent.; several microcytes. (Dr. Wethered.)

XIV.—*A case of Hemiplegia in Typhoid Fever associated with Aphasia: hæmorrhage from the bowels and purpura.* By Francis Hawkins, M.B. *Read December* 9, 1892.

ALICE H., æt. 18, servant, came under my observation April 21, 1890, complaining of "pains in the head and diarrhœa," of four days' duration. There had been no rigor or shiver, and until four days ago she was quite well.

Examination of patient.—The patient lies upon her back; the face is flushed and pupils dilated; the tongue is dry, red at the tip, edges, and in the centre, but white on either side; no sordes on teeth; lips not cracked; skin dry, burning. Is very thirsty, feels mouth and throat dry; is fairly well nourished.

Heart.—Position normal; sounds normal. Pulse 70 per minute, regular.

BOSTON MEDICAL LIBRARY ASS'N NOV 15 1893

Lungs.—Percussion normal in all regions; few râles at bases. Respiration 20 per minute.

Abdomen.—Slightly prominent, tympanitic generally; no pain, no gurgling, no spots; spleen not enlarged; liver not enlarged.

Bowels.—Stools liquid, offensive, somewhat typhoidal in character.

Urine.—Sp. gr. 1020, acid, no albumen.

Temperature in axilla, 101·8°.

The case, from the above facts, was regarded as one of typhoid fever.

Without going into the daily condition of the patient I propose to draw attention to points of interest which preceded the hemiplegia.

On April 28—the seventh day after admission and the eleventh day from first feeling ill—the tongue was noticed to be quite clean and moist. The patient asked for food, and said she felt very hungry. The spleen was now enlarged.

May 2.—Since the above note the patient improved until yesterday, when she relapsed into a "typhoid state." The bowels were moved three times, and on each occasion blood was passed.

May 4 (thirteenth day since admission and seventeenth day of illness).—Typical typhoid spots are now seen on the abdomen. Blood has been passed by the bowels each day since last note.

May 6.—The patient vomited some brownish curds.

May 8.—Typhoid spots have been daily observed (since their first appearance, May 4) in successive crops, and now purpuric spots are seen over the abdomen—for the most part distinct and separate from the typhoid spots, but a few of the typhoid spots assume a hæmorrhagic character.

This is the sixth day since the first appearance of hæmorrhage from the bowels, which has, with only one intermission, been of daily occurrence. Yesterday a considerable quantity of blood was passed.

May 12.—No hæmorrhage from the bowels for the past three days. Patient is much exhausted and emaciated. Heart sounds are feeble, but no murmur is heard; while the typhoid spots are gradually fading the purpuric spots are increasing. They are specially numerous over the right iliac region. Some of the spots are of the size of a pea.

May 13.—Hæmorrhage occurred from the bowels last evening at 8 P.M., and recurred three times during the night and twice this morning. It is estimated that about half a pint of blood was passed on each occasion. The purpuric spots are more numerous, and now extend down the right thigh almost to the knee.

May 14.—No hæmorrhage from the bowels; no cardiac murmur.

May 15.—This is the twenty-fifth day since admission and twenty-ninth since onset of illness, the fourteenth day since hæmorrhage from the bowel was first noticed, and the eighth day since the first appearance of purpuric spots.

The patient when spoken to makes no reply, but when asked to put out her tongue—it requires very loud speaking, almost shouting to make her respond—she does so, and the tongue deviates to the right side. When asked to move the left arm she does so, but when asked to move the right arm she is unable to do so, although it is evident that she tries.

The right leg is everted and cannot be moved. The left leg can be moved.

The tendon-reflex is not marked on either side, but there are slight muscular vibrations.

So far as one can judge the cutaneous sensibility in the arms and legs of the right side is somewhat impaired. The

bowels are constipated; purpuric spots are abundant. The abdomen is less distended, but there is marked tympanites over the region of the cæcum and the ascending and transverse colon, while over the descending colon and to the left of the middle line the percussion note is of a muffled character.

On May 17, the thirty-second day, the patient died.

Post-mortem.—Body much emaciated; abdomen not much distended; purpuric spots over the abdomen and down the right thigh; post-mortem lividity on dorsum well marked.

The skin over iliac region is greenish in colour.

Right leg everted.

Rigor mortis marked in both legs and in the left arm, but only very slight in the right arm.

On opening the abdomen the cæcum is observed to be much distended; the ascending and transverse colon are also much distended. The descending colon is only slightly distended.

The small intestine is pushed *en masse* to the left of the middle line, and the stomach is pushed upwards.

On removing and opening the intestine, the large intestine throughout its whole extent, but more especially in the ascending and transverse portions, was a mass of ulceration; many of these ulcers extended down through all the coats, having only the serous coat for the base. The ulcers varied in size from a small to a large marble. No ulcerated vessels could be detected.

The cæcum contained a few ulcers, which were also deep, while in the ileum only three Peyer's patches showed signs of ulceration. These were not deep, and the edges were rounded.

The spleen was much enlarged, soft and friable.

The liver showed cloudy swelling.

The lungs were congested.

The Heart.—There was no pericarditis; the ventricular walls were soft and flabby. A thrombus was situated in the left auricle, and numerous blood-clots beneath the columnæ carneæ and amid the musculi pectinati of the left auricle. The valves were normal.

The brain was more soft anteriorly on the left side than the right. The left middle cerebral artery was occluded by a small reddish-white plug, about the size of a grain of rice. This plug was situated a few lines above the origin of the anterior cerebral artery and the posterior communicating.

Remarks.—Although this case presents many points of interest—I may for a moment mention "purpura,"* which is apparently not common in typhoid, and is frequently, but not always, indicative of a fatal termination—it is my intention to limit my remarks to the subject of "hemiplegia in typhoid fever;" and, while reflecting how best to make any remarks worthy of acceptance by the members of this Society, it occurred to me to bring together as many cases as I could find recorded, and then to make an analysis. This idea was further commended to my judgment when I remembered that although† paralysis occurring during, or as a sequel of, the acute infectious diseases has from time to time been written upon, "hemiplegia in association with typhoid fever" has, so far as I can ascertain, with the exception of an article by Professor Nothnagel,‡ received little attention, and in our own medical literature practically none beyond the recording of some six cases. After some considerable search I have succeeded in bringing together, including the case just read, seventeen instances in which hemiplegia was associated with typhoid, and I will now proceed to analyse them under the following headings:

Age.—In twelve of the seventeen cases the ages are recorded, and *three* cases occurred in those under fifteen years of age, being respectively between two and three, seven and eight years, and at eleven years; *nine* in patients over fifteen, one being eighteen, one nineteen, three twenty-one, three twenty-four, and one thirty.

Sex.—In twelve cases in which sex is mentioned, nine were males and three females.

Period of occurrence.—In fourteen cases in which data are given as to the time in the course of the fever or during convalescence, I find that the onset of hemiplegia was as follows:—At the beginning of the *second week* (the ninth day) in one case; during the *third week* in six and the *fourth week* in two cases; during convalescence in five cases, and in one

* Dr. Barlow, *Lancet*, 1884, vol. i. "Rare Complications in Typhoid Fever," *Medical Times and Gazette*, vol. i, 1884. Dr. Wickham Legge, *St. Bartholomew's Hospital Reports*, 1883.

† The first mention that I can find of paralysis in association with typhoid is by Monneret and Fleury, in *Compendium de Médecine pratique*, vol. viii, in 1846. Then Friedberg mentions it in 1858, in "Therapie der Muskellahmung" (*British and Foreign Med.-Chir. Review*, vol. xxiii, 1859). Gubler, in the *Archives général de Médecine*, is the first to record a case of hemiplegia in 1860. Since that date the subject has been mentioned, but so far as I am aware no separate analysis of cases has as yet been made.

‡ *Deutsches Archiv für klinische Medicin*, 1872, vol. ix.

of these five cases, in which the fever had been of a very severe type and convalescence prolonged, hemiplegia did not occur till between the eighth and ninth months.

Side and parts paralysed.—In sixteen cases in which mention is made of the side affected, I find that the right side was paralysed in twelve and the left in four. Facial paralysis* is described as being present in four instances on the opposite side to the extremities, while in one case the facial paralysis was on the same side as the paralysis of the extremities. The eyelids were described as being paralysed, but no other part of the face, in two cases. Swallowing was noted as being difficult in four cases. In some instances sensory as well as the motor paralysis was observed, but this was not noted in all cases. In my own it was very difficult to define, the patient being almost moribund at the time of the onset of the hemiplegia.

Preceding and associated lesions.—Convulsions preceded the attack of hemiplegia in two cases, and pains in the head in one. Hæmorrhage from the bowels (being in one instance† associated with purpura) in two cases, syphilis with pregnancy in another, and pneumonia was observed after the onset of hemiplegia in one case. In fourteen cases in which mention is made in reference to any affection of the speech, aphasia accompanied the hemiplegia in twelve instances, being in ten associated with right and in two with left hemiplegia. Any affection of speech is described as being absent in two cases.

Duration and result of the hemiplegia.—The duration in one case was three days. In all the other cases (except those terminated by death) the hemiplegia remained from ten days to several weeks. In fourteen cases in which the result is given, nine terminated in complete recovery. The hemiplegia remained persistent in three cases, and was followed by death in two instances.

Cause of the hemiplegia.—So far as this analysis teaches, it would appear that age exerts little influence upon the production of hemiplegia. It would, however, seem to be more common amongst males than females, and more frequent

* Dr. Adolf Wallenberg found that facial paralysis was seldom present in cases collected by him of hemiplegia in acute infectious diseases (*Jahrbuch der Kinderheilkunde*, 1885–6), and I observe the same in cases recorded by Dr. Osler, "Cerebral Palsies of Children."

† Fagge draws attention to the association of hæmorrhage from the bowels and purpura in vol. i.

at the end of, or during convalescence from, the fever. It may here be mentioned that in none of the cases analysed was there any reason to suspect valvular disease of the heart from which an embolus might originate, and yet in several instances the hemiplegia has been regarded as of embolic origin, and in one instance hæmorrhage was assigned as the cause.* Of the seventeen cases collected only two died. In each instance a post-mortem was made.†

In both of these cases a clot was present in the middle cerebral artery. In one the heart is described as normal, but there was an infarct in the lower lobe of the left lung. In the other case the heart was flabby, the ventricles dilated, and what was described as a thrombus was found in the left auricle. This fact, then, would tend to the view that when hemiplegia occurs in association with typhoid fever, and *late in its course, it is a consequence of a cardiac complication.*‡ I must admit that I cannot agree with Dr. Donkin§ when he suggests that probably the clot was produced *in situ*, when the artery is described as being perfectly healthy. In other acute diseases we have pathological instances of a thrombus in the left side of the heart producing an embolus and hemiplegia.

Henoch‖ mentions a case of hemiplegia associated with diphtheria in which an embolus was found in the right Sylvian artery and a thrombus in the left side of the heart.

Dr. Gee¶ had a case of diphtheria under his care in which hemiplegia occurred, and at the autopsy a clot was found in the middle cerebral artery. Infarcts were also observed in the spleen, and post-mortem clots in both sides of the heart. The same writer also refers to a case of noma vulvæ** in a

* It is known that endocarditis may very rarely arise during typhoid fever when no rheumatic basis can be traced, but typhoid may be associated with rheumatic fever and then endocarditis, but in such cases hemiplegia has not been noted (*Trans. Clin. Soc.*, vol. xvii).

† *Lancet*, vol. i, 1892, and P.M. notes of cases just read. Since writing this paper my attention has been called to the paper of Marie in the *Progrès médicale*, 1885, No. 30 ("Hémiplégie cérébrale infantile et maladies infectieuses"), where he directs attention to an article by Richardière ("Étude sur les scléroses encéphaliques primitives de l'enfance") where mention is made of two cases of cerebral sclerosis in typhoid fever.

‡ I find Hilton Fagge (*Principles and Practice of Medicine*) also suggests this view, vol. i, p. 181.

§ *Lancet*, 1892, vol. i.

‖ *Diseases of Children.*

¶ Reported by Dr. Abercrombie, *Medical Times and Gazette*, vol. ii, 1882.

** *Medical Times and Gazette*, 1878. Writers are not agreed if diphtheritic

girl in whom convulsions and hemiplegia occurred, and at the autopsy the cardiac valves were normal, but a thrombus was found in the left auricle and an embolus in the middle cerebral artery. While admitting that other causes may be at work in the production of the hemiplegia when it occurs late in the course of the fever, it is beyond a doubt evident that it may be the result of a cardiac complication. But the question arises, Is this the cause when the onset of the hemiplegia is *early in the disease?* Given that the cardiac valves are normal, I think such most improbable, and to support this view will ask your attention to the facts of the case in this analysis when such occurred.* The patient, a man æt. 24, had been ill for eight days, when he suddenly on the ninth day became insensible, and on his becoming conscious it was noticed that he had lost the power of speech and to move the right arm. In a very few hours he could speak, and on the eleventh day the hemplegia was completely recovered from. On recovery from his unconscious state it was found that pneumonia complicated the typhoid, and it seems to me that if in this case the cause of the hemiplegia had been a cardiac complication which allowed of the formation of a thrombus, that cardiac condition†—especially as the case was complicated with pneumonia—could scarcely have admitted of a prolonged illness following upon it, being attended, as was the case, by complete recovery. Moreover, in those cases in which the cardiac complication has been suggested as the cause, the onset of the hemiplegia has been late in the course of, or during convalescence from, the fever, and in no instance recorded has recovery taken place in less than ten days. I would therefore suggest that in this case the patient was primarily in an apoplectic condition, which, passing off, left symptoms of a weak cerebral lesion in the form of a hemiplegia.‡ This view might receive some

paralysis occurs in the form of hemiplegia, but these cases to which I refer are evidence that such may occur in association with diphtheria as a consequence of a cardiac complication. There is abundance of clinical evidence to show that dilatation of the heart is of frequent occurrence in cases of scarlatinal nephritis, and in such cases hemiplegia has frequently been observed without any evidence of valvular lesion. May we not also in such cases have cardiac thrombi formed, producing an embolus and hemiplegia?

* This case is recorded in the published Reports of the Middlesex Hospital for 1883.

† It may be a form of myocarditis, causing cardiac thrombi and thus emboli.

‡ Gowers, *Quain's Dictionary of Medicine.* Nothnagel, op. cit.

amount of support in the fact that cases of hemiplegia have been recorded in pneumonia and in phthisis in which no lesion has been observed at the autopsy.*

I add a tabular list of the cases referred to, with literary references.

* Lepine, *Revue de Médecine*, 1886.

Tabular account of cases of hemiplegia associated with typhoid fever.

No. of case.	Name of author, &c.	Sex and age.	Time of occurrence.	Concomitant symptoms.	Aphasia.	Side affected.	Result.
1	West, *Diseases of Children*	Child between 2 and 3 years	Middle of 3rd week	Convulsions; unconsciousness	?	?	Recovery.
2	Cayley, *Med. Times and Gazette*, 1878	Boy, 11 years	During convalescence	...	Speech not affected	Right	,,
3	Gee, *Med. Times and Gazette*, 1878	Boy between 7 and 8 years	,,	...	Aphasia	,,	,,
4	Scoresby Jackson, *Edin. Med. Journ.*, 1867	Man, 21 years	18th day	...	,,	Right side of face Right side of body	,,
5	Donkin, *Lancet*, April 23, 1892	Woman, 30 years	About 30th day	Pains in head	Aphasia	Right	*Died.* Clot in middle cerebral artery; heart dilated, otherwise normal.
6	G. P. Newbolt, *Lancet*, August 27, 1892	Man, 21 years	41st day	Hæmorrhage from bowels	,,	Left	Recovery.
7	Middlesex Hospital published Report, 1883	Man, 24 years	9th day	Convulsions; insensible	,,	Right	,,
8	Francis Hawkins, *Clin. Soc. Trans.*	Girl, 18 years	29th day	Hæmorrhage from bowels; purpura	,,	,,	*Died.* Clot in middle cerebral and in left auricle of heart

9	M. Sorel, *L'Union médicale*, 1883	Man, 24 years	19th day	...	„	„	Persistent one year after.
10	Gubler, *Archives gén. de Médecine*, 1860	Girl, 19 years	Height of fever	Syphilis; pregnancy 7th month	„	„	Recovery.
11	Karmin, *Wiener med. Presse*, 1868	Man, 24 years	Between 8th and 9th month of prolonged and severe case	...	No cerebral disturbance	Left	Persistent.
12	Berger, *Berlin. klin. Wochenschr.*, 1870	Man, 21 years	3rd week	Unconscious	?	„	„
13	Nothnagel, *Deutsches Archiv für klinische Medicin*, 1872	Man?	During convalescence	...	?	Right	?
14	Benedict, *Electrothérapie*, 1868	Not given	Not given	...	Aphasia	„	?
15	„	„	„	Atrophy of optic nerve	Speech faltering	Left	?
16	Eulenberg, quoted by Nothnagel	„	„	...	Aphasia	Right	Recovery.
17	Eulenberg	„	„	...	„	„	„

XV.—*A case of Rhinolith.* By F. de Havilland Hall, M.D. *Read January* 13, 1893.

MISS F. S., æt. 16, was sent to me by a medical friend with the idea that she was suffering from ozæna. The patient stated that from childhood, *i. e.* from about the age of two and a half, a faint smell had been noticed to proceed from the nose, that the smell had continued ever since, and that it had become more marked of late. It had been noticed that the nose was more offensive at the catamenial periods. The patient also complained of a discharge from the left nostril and the occasional passage of crusts. The sense of smell was preserved. On examination the left nostril was found to be almost completely occluded by a mass, the bulk of which was situated in the inferior meatus, but projections extended into the middle meatus. The mass was of stony hardness when struck with the sound, and was almost immovable. It was of blackish-grey colour, with a faint tinge of green. The right nostril was quite free, and with the exception of a few adenoid vegetations nothing abnormal was seen in the naso-pharynx.

I at once recognised that I had to do with a rhinolith, so, after applying a twenty per cent. solution of cocaine to the nasal mucous membrane, I endeavoured to seize the mass with forceps and drag it forwards. My first attempt convinced me that it would be impossible to remove the stone *en masse*, so I proceeded to remove it piecemeal, and succeeded in detaching some fragments. A few days later I had another sitting, and removed portions of the stone by means of forceps. After three further sittings there was left a large mass, which so blocked up the meatus that I could not get my forceps around it in any diameter to seize and crush it, and it was now so freely moveable that in attempting to seize it there was some risk of the stone being forced into the pharynx, with the danger of its passing into the larynx. After several fruitless attempts to seize the mass with forceps I had had specially made I gave up the attempt to remove it in this manner. It then occurred to me that as the stone moved about like a cork inside a bottle it might be

dislodged, just as a cork can, by noosing it. I accordingly made a loop of some wire off a soda water bottle, and after one or two attempts I succeeded in getting the loop well over the stone. But, having done this, I was still at a loss how to extract the stone, as it became so firmly impacted on drawing it forward that I could not apply sufficient traction simply by catching hold of the end of the wire. Fortunately I had a strong pair of forceps at hand, with which I seized the loop, and with a great tug I succeeded in relieving the patient of the stone which had bothered her for so many years. The last operation was very painful, and was followed by rather free hæmorrhage.

The patient presented herself for examination three weeks later. I found the left nostril in a perfectly healthy condition, and the patient was quite free from traces of the discharge which had existed for upwards of thirteen years.

After washing the fragments to remove the mucus and blood covering them, and drying them, I found that they weighed 92 grains.

Dr. Wilson Hake kindly made a chemical examination, and reported as follows:

"Organic matter	26·4
Calcium phosphate ($Ca_3,2PO_4$)	73·6
	100·0

There is no magnesium or carbonate present, and I estimated the calcium and the phosphoric acid separately." No nucleus was apparent, but it is possible that if the large mass were cut in two some foreign body might be detected in the centre. I could not obtain any history of the introduction up the nostril of anything likely to form a nucleus, but the early age from which the symptoms date will readily explain this circumstance.

When I started to write this paper it was my intention to bring before the Society the whole subject of rhinoliths, their mode of formation, chemical composition, the symptoms they produce, &c., and I was the more decided to do this as I can find no account of any lengthy communication on the subject at any of the London societies. In our own Society no rhinolith has previously been shown, and at the Pathological Society only four examples have been exhibited, viz. by Mr. Clutton in 1884, by Mr. George Stoker in 1885, by Mr. D'Arcy Power in 1887, and by Mr. Sydney Jones in 1889.

Rhinoliths are also conspicuous by their absence from the museums of London. There are no specimens in the museum of the Royal College of Surgeons, nor in the museums of the following hospitals, viz. Charing Cross, King's, Middlesex, St. George's, and St. Mary's. There are two specimens in the museum of University College Hospital, and one in the museums of St. Bartholomew's, Guy's, London, St. Thomas's, and Westminster respectively. While, however, I was collecting material for my paper I came across an admirable monograph published this year by Dr. Max Seeligmann, of Carlsruhe, which treats the subject so exhaustively that the ground is completely cut from beneath my feet. I will content myself, therefore, by making a few remarks, and by directing attention to some cases which have escaped Dr. Seeligmann's keen eye.

A few years ago rhinoliths were considered to be extremely rare, but now that trained rhinoscopists are examining the interior of the nose additional cases are constantly being discovered. Dr. Seeligmann has succeeded in collecting the records of 108 cases, which, with two of his father's cases not previously published, brings his list up to 110. To these I would add fifteen cases, including my own, which I have collected from various sources.

The first point which strikes one in going over the cases is the great preponderance of females who are subject to this affection. Of the 110 cases recorded by Seeligmann sixty-two occurred in women, twenty-nine in men, and in nine the sex is not recorded. There is no obvious explanation as to why rhinoliths should be so much more common in females than in males. Dr. Seeligmann suggests as a possible explanation the decidedly less frequency of blowing the nose in women compared with men (?), and a consequent retention of secretion.

There can be no doubt that in the vast majority of cases the concretion takes place round a foreign body, either introduced from without or which has entered the nostril through the choana in the act of vomiting or sneezing. In some cases the nucleus is represented by a piece of inspissated mucus or a small blood-clot. It is difficult to understand how a concretion can take place spontaneously, but at the same time its possibility must be admitted.

As a rule only one stone is met with, and the exceptions are usually more apparent than real, the second stone being probably masses detached from the first in the process of extraction. Mackenzie, however, records a case in which it

is quite clear that two stones really existed, and Sydney Jones has put another case on record. In all the cases hitherto reported, with one doubtful exception, one nostril only has been affected. In the doubtful case just mentioned it is stated that the stone occupied both nostrils, but, as Dr. Seeligmann points out, in the absence of exact particulars it is probable that an originally unilateral concretion had gradually perforated the septum and thus appeared on the other side, where it increased in size by the deposition of salts.

As regards its weight and size the calculus, which in my case weighed 92 grains, is distinctly above the average; this is given by Dr. Seeligmann as between 7½ grains (0·5 gramme) and 90 grains (6 grammes). In Dr. Seeligmann's list there are two stones, each weighing over 190 grains,—one stone which weighed 337 grains, and another which attained the extraordinary weight of 720 grains.

The composition of my calculus is more simple than usual, containing, as Dr. Wilson Hake points out, no carbonate or magnesium.

As in my case, the most common symptom denoting the presence of a rhinolith is the existence of a fœtid discharge from the nostril. This, indeed, was the only symptom of which my patient complained, but in Dr. Seeligmann's careful analysis of the symptoms met with in the cases he has collected it will be found that they are very varied. Among them may be mentioned the following:—Pains in head of a neuralgic character; eye troubles, especially increased secretion of tears on the affected side; disturbance of hearing, tinnitus, alteration in the voice, attacks of sneezing, giddiness, and a tendency to vomiting. Schmiegelow records the case of a man with a rhinolith in the left nostril who during five or six years felt a profuse perspiration break out on the left side of his head whenever he got warm. The curious part of the case is the circumstance that the phenomenon ceased four years before the stone was extracted. Schmiegelow explained this on the ground that by the continual growth of the rhinolith so much pressure came to be exercised on the mucous membrane that it and its nervous elements were destroyed. Once arrived at this point, the reflex neurosis could no longer be produced.

The question of treatment need not occupy us very long. The method of removing rhinoliths depends chiefly on their size. If they are small they can usually be readily extracted

by suitable forceps. In making attempts to seize the stone great care should be exercised so as not to push it backwards, on account of the risk of its passing into the larynx. Should it be impossible, on account of the position of the stone or the configuration of the nose, to extract it anteriorly, it may be necessary to push it backwards, but in this event the finger should be passed back to the pharynx so as to prevent the stone entering the larynx. In some cases forceps made with blades that can be introduced separately, like midwifery forceps, will enable the calculus to be seized, or, as in my case, the mass may be extracted by passing a wire loop over it and then exercising traction. If the calculus is very large it may be necessary to crush it before attempts are made to remove it. Should the calculus be unusually large and hard, it may be impossible to remove it without separating the nose from its attachment to the cheek. This had to be done in a case reported by T. H. Hendley.* If the rhinolith is of unusual size and also very hard, and especially if it is wished to remove it at a single sitting, a general anæsthetic will be required.

The introduction of cocaine has much facilitated the removal of rhinoliths, as painting a twenty per cent. solution of this drug over the mucous membrane not only renders the parts anæsthetic, but also dilates the passage by its constringent action on the mucous surfaces. The after treatment consists in spraying out the nostril with some mild antiseptic solution. I have appended to this paper Dr. Seeligmann's list of the literature bearing on the subject, with one or two corrections and the additional cases I have collected.

Literature.

1. *Mathias de Gardi*, Pratica Venetiis, 1502, pars ii, cap. 14, s. 308.
2. *Bartholin*, Hist. Anatom. Rar., 1654, cent. i, s. 47.
3. *Bartholin*, ibidem, cent. iv, s. 404.
4. *Clauder*, Ephem. Nat. Curios., 1685, dec. ii, ann. xiii, obs. 78.
5. *Kern*, ibidem, 1700, dec. iii, ann. iv und v, obs. 43, s. 100.
6. *Reidlinus*, ibidem, 1706, dec. iii, ann. ix und x, obs. 145, s. 268.
7. *Wepfer*, 1727, obs. 192, s. 905.
8. *Ruysch*, Obs. Anat. Amstelodami, 1733, obs. 44, s. 42.
9. *Horn*, Contrib. à l'étude des rhinolithes par Monnié, Bordeaux, 1889, obs. 8.
10. *Savialles*, Bull. de la Faculté de Méd., 1814, t. iv, s. 44.
11. *Graefe*, Annales d'Oculistique, 1828, t. viii, 4 et 5 livraison, s. 203; und Journal der Chirurgie und Augenheilkunde (*Graefe* und *Walther*), Bd. xii, s. 9.
12. *Graefe*, ibidem.

* *Brit. Med. Journ.*, 1886, vol. ii, p. 1161.

13. *Thouret*, Archives gén. de Méd., 1829, t. xix, s. 27.
14. *Axmann*, ibidem, 1829, série 1, t. xx, s. 102.
15. *Brodie*, Lancet, Jan. 6, 1844.
16. *Demarquay*, Archives gén. de Méd., 1845, série 4, t. viii, s. 174 ff.
17. *Köstlin*, Württemburger Korrespondenzblatt, 1854.
18. *Rouyer*, Bull. de la Société Anat. de Paris, 1857, s. 60.
19. *Verneuil*, Gaz. des Hôpitaux, 1859, s. 25.
20. *W. N. Browne*, Edinb. Med. Journ., 1859, vol. v, s. 50.
21. *M. Hays*, Monnié, l. c., obs. xviii.
22. *West*, Lancet, 1872, vol. i, s. 147.
23. *Hering*, Monatsschrift für Ohrenheilk., &c., 1881, No. 5.
24. *Moure*, Monnié, l. c., obs. xix.
25. *J. Pereswetow*, Revue mensuelle de Laryngologie, 1882.
26. *M. Mackenzie*, Manual of Diseases of the Throat and Nose, 1884, vol. ii, s. 446.
27. *M. Mackenzie*, ibidem, s. 447.
28. *Tillaux*, Bull. et mém. de la Soc. de Chir., N. S., ii, 2, s. 144.
29. *Deville*, in Schmidt's Jahrbücherncitiert, 1863, Bd. cxvii, s. 316.
30. *Pingault*, Gaz. des Hôpitaux, 1852, 145, s. 578.
31. *Weil*, Prager med. Wchschrft., 1880, No. 45.
32. *Störk*, Klinik der Krankh. d. Kehlkopfes, &c., 1880, s. 91.
33. *Schmiegelow*, Sitzungsbericht des Kongresses in Kopenhagen, 1884.
34. *Czarda*, Gaz. méd. de Paris, 1884, Nos. 49 and 50.
35. *Czarda*, ibidem.
36. *Czarda*, ibidem.
37. *Jacquemart*, Annales des Maladies de l'Oreille, 1884, i.
38. *Baginsky*, Berl. klin. Wchschrft., 1884, No. 48, s. 772.
39. *Chiari*, Wiener mediz. Wchschrft., 1885, No. 46.
40. *Krause*, Deutsche mediz. Zeitung, 1885, Juni 1, No. 44.
41. *Cresswell Baber*, Brit. Med. Journ., October 17, 1885.
42. *Moriarty*, ibidem, April 10, 1886.
43. *Koehler*, Verhandlungen der 59, Naturforscherversammlung (Laryngologische Sektion), Berlin, 1886.
44. *Clay*, Brit. Med. Journ., February 12, 1887.
*45. *Stoker*, ibidem, August, 1887.
46. *Charazac*, Rev. méd. de Toulouse, August und September, 1888.
47. *Lapthon-Smith*, Montreal Med. Journ., July, 1888.
48. *Moure*, Monnié, l. c., obs. xl.
49. *Moure*, ibidem, obs. xli.
50. *Seifert*, Sitzungsberichte der Würzburger Phys.-med. Gesellschaft, 1885.
51. *Voltolini*, Krankheiten der Nase, &c., Breslau, 1888.
52. *Brandes*, Archiv der Pharmazie, xi, s. 157.
53. *Römer, Dr. Franz Simon*, Handbuch der angewandten medizinischen Chemie, Berlin, 1842, Bd. ii, s. 572.
54. *Schaeffer*, Chirurg. Erfahrungen in der Rhinologie und Laryngologie, Wiesbaden, 1885, s. 32.
55. *Schaeffer*, ibidem.
56. *Noquet*, Revue de Laryngologie, &c., July 1, 1890, s. 425.
57. *Rualt*, ibidem, August 15, 1890, s. 530.
58. *Rualt*, ibidem, s. 531.
59. *Rualt*, ibidem.
60. *Schiffers*, Bericht über die Assemblée annuelle des Laryngologistes et Otologistes Belges in der Rev. de Laryngologie, &c., July 15, 1890, s. 478.
61. *Boland*, ibidem, s. 479.

* Query, *Brit. Med. Journ.*, 1885, vol. ii, p. 1164.

62. *Boland*, Bericht über die Assemblée annuelle des Laryngologistes et Otologistes Belges in der Rev. de Laryngologie, &c., July 15, 1890, s. 479.
63. *Higguet*, ibidem.
64. *Higguet*, ibidem.
65. *Jefferson Bettmann*, Journ. Amer. Med. Association, vol. iii, No. 10, September 6, 1884.
66. *Trukenbrod*, Bericht über die Sitzung norddeutscher Ohrenärzte in der Revue de Laryngologie, &c., June 15, 1889, s. 358.
67. *Hartmann*, ibidem.
68. *Chas. A. Todd*, St. Louis Cour. of Med., s. 171, August, 1885.
69. *P. W. Logan*, St. Louis Medical and Surgical Journal, August, 1885.
70. *R. E. Beach*, Medical Record, vol. xxviii, No. 2, s. 38, July, 1885.
71. *R. E. Beach*, ibidem.
72. *Edward Bovill*, Brit. Med. Journ., October 16, 1886.
73. *Morelli*, Orvosi Hetilap., 1886, No. 52.
74. *Thomas H. Hendley*, Brit. Med. Journ., Dec. 11, 1886.
75. *Cresswell Baber*, Lancet, April 16, 1887.
76. *Schötz*, Berl. klin. Wchschrft., 1887, s. 13.
77. *Nolte*, Mediz. Centralzeitung, lvi, 1887, s. 67.
78. *Schapringer*, Mediz. Monatsschrift (New York), November, 1889.
79. *Ferié*, Soc. anatom. de Bordeaux, June 21, 1887.
80. *Cozzolino*, Archiv di Laryng., January, 1888.
81. *Masini* (Turin), Gazzetta hospitali, June 4, 1888.
82. *Wheeney*, Dublin Journ. of Med. Science, February, 1889.
83. *Faulkner*, ibidem, March, 1889.
84. *Baden* (Dänemark) Hospitals-Tidende, Jan. 9, 1889.
85. *Hauquet*, Archives méd. Belges, April, 1889.
86. *Van der Heide*, Weekbl. van Het. Nederl. Tijdschrvoor Geneesk, No. 1, 1889.
87. *Baumgarten*, Wiener med. Wchschrft., No. 51, 1889.
88. *Kiesselbach*, Münchner med. Wchschrft., No. 9, 1889.
89. *Maurer*, ibidem, No. 10, 1889.
90. *Dethlefsen*, (Dänemark) Hospitals-Tidende, July 24, 1889.
91. *Chiari*, Annales des Maladies de l'Oreille, Jan., 1890.
92. *Chiari*, ibidem.
93. *James B. Ball*, Brit. Med. Journ., March 1, 1890.
94. *G. W. Major*, New York Med. Journ., June 28, 1890.
95. *W. W. Parker*, ibidem, July 19, 1890,
96. *Scheinmann*, Sitzungsbericht der Berliner laryngologischen Gesellschaft vom April 24, 1891.
97. *Wessing* (Kopenhagen), Hospitals-Tidende, s. 487, 1891.
98. *Bijlveld*, Weekbl. van Het. Nederl. Tijdschr. voor Geneesk, No. 1, July, 1891.
99. *Garel*, Monatsschrift für Ohrenheilkunde, 1890, s. 88.
100. *Hinde*, ibidem.
101. *Nitsche*, ibidem, s. 196.
102. *Herzfeld*, Sitzungsbericht der Berliner laryngologischen Gesellschaft, May 29, 1891.
103. *Schiffers*, Société chirurgicale de Liège, séance du Oct. 1, 1891.
104. *Rohrer* (Zürich), Wiener klin. Wchschrft., 1890, s. 27.
105. *Wagner* (München), Münchener mediz. Wchschrft., 1891, s. 833.
106. *Jurasz*, Krankheiten der oberen Luftwege, Heft 1, s. 96.
107. *Jurasz*, ibidem, s. 97.
108. *Edmond McWeeney* (Dublin), Privatmitteilung:

Zum Teil mir nicht zugänglich, zum Teil in ihrer Zugehörigkeit, zweifelhaft.
Cook, Ranking's Abstracts, 1847, vol. vi, s. 132.
Roe, Archives of Laryngology, 1880, vol. i, No. 2, s. 149 ff.
Nourse, Brit. Med. Journ., October, 1883, s. 728.
Guttceit, Mediz. Zeitung, Russland, No. 21, 1846.
Ritter, Memorabilien, Heilbronn, 1876, Heft 7.
Stockton, Boston Med. and Surg. Journ., 1884, vol. iii, No. 6, s. 135.
* *Clutton*, Brit. Med. Journ., March 8, 1884.
Silitsch, Rhinolithen und Fremdkörper in der Nase, Moskau.

Additional cases of rhinolith.

1. *F de Havilland Hall*, Clinical Society, 1892.
2. *H. B. Hewetson*, Journ. of Laryngology, vol. ii, p. 485.
3. *H. F. Weiss*, Brit. Med. Journ., 1887, vol. i, p. 482.
4. *T. E. Little*, ibidem, 1891, vol. i, p. 528.
5. *C. M. Anderson*, Intercolonial Medical Congress of Australasia, Transact. of Second Session, p. 797.
6. *A. L. Sandel*, Medical Reporter, Calcutta, September 1, 1892.
7. *D'Arcy Power*, Trans. Path. Soc., vol. xxxviii, p. 323.
8. *Sydney Jones*, ibidem, vol. xl, p. 401.
9. Museum of Univ. Coll. Hosp., 1383c.
10. Ibidem, 1383d.
11. *J. M. Hunt*, Practitioner, vol. xlii, p. 292.
12. *Schlesinger*, Centralblatt für Laryngologie, vol. iii, p. 270.
13. *Schmidt*, ibidem.
14. *J. Wright*, New York Med. Record, October 12, 1889.
15. Museum of London Hospital, series lvi, No. 185.

---

* For details see *Trans. Path. Soc.*, vol. xxxv, p. 330.

XVI.—*A case of Inherited Gout, with production of tophi at an early age.* By Sir Dyce Duckworth. *Read January* 13, 1893.

JOHN O., æt. 18, a baker, was admitted to John Ward in St. Bartholomew's Hospital under my care on December 7, 1891, suffering from pains in the feet, right arm, and hand. Ten months ago he was in the hospital under the care of Dr. Gee, suffering from gout in his feet, which followed a wetting. The pains now complained of came on two months ago after getting wet. He has been feeling weak and giddy, and was compelled to give up work.

For nine years past there had been occasional pains in the feet.

The family history was negative in respect of gout. The father died at forty-nine of bronchitis, and the mother of heart disease. No brothers or sisters. There was no history of rheumatism.

The patient was an under-sized youth, with an unintelligent expression. His head was small and ill-shaped. Face rather pallid, and affected with acne.

There was no pyrexia. Breathing natural. The pulse was 80, of fair volume and tension, intermitting every two or five beats. Arteries not thickened. Tongue furred. No blue line on the gums. Eyes rather hypermetropic. Vessels of the retina somewhat tortuous.

The chest was well-formed. Expansion good and equal. The heart was natural in all respects. In the abdomen nothing abnormal detected. Slight lumbar œdema.

Stiffness and tenderness in both great toe-joints which were rather deflected to the outer aspects of the feet. Swelling and pain in some small joints of right hand, especially at second metacarpo-phalangeal joint. The urine was of sp. gr. 1004, acid, and contained a trace of albumen. Bowels generally much confined.

A very noteworthy feature of this case was the occurrence of tophi of sodium urate on the helices and antihelices of the ears. The true nature of this deposit was ascertained by chemical examination.

Under treatment with colchicum and alkalies, anodyne

liniment (belladonna and ether), and subsequently with quinine and alkali, there was great improvement. As already stated, there was no history of gout in the patient's family to be obtained. This does not count for much.

The patient was a perfectly temperate youth, an abstainer from alcoholic drinks, and was certainly not "exposed to luxury."

The feeble brain development in this case is noteworthy, since gout does not, as Sydenham remarked, commonly attack fools.

It is exceedingly rare to meet with tophi in young persons. This is certainly the earliest age at which I have observed them, and Sir Alfred Garrod kindly informs me that in his experience he has not met with them in any patient so young as this one.

In this case it is interesting to note that the kidneys were probably inadequate to their proper functions, and were perhaps undergoing granular changes; and this is commonly the case in such individuals as are the subjects of tophi. Yet there were no marked indications of cardio-vascular changes dependent on an interstitial nephritis.

It is hardly possible to believe that this patient had acquired gout; and although the history of this disorder was not stated as having been present in his parents, I cannot suppose that there was absolutely no ancestral taint of this kind. The life history and occupation of this youth were opposed to the presumption of his having induced gout in his own textures.

(A water-colour drawing of the case was exhibited.)

XVII.—*A case of Uratic Deposit in the Conjunctival Membrane.* By T. D. Pryce (introduced by Sir Dyce Duckworth). *Read January* 13, 1893.

ABRAHAM P., æt. 73, postboy (postillion), cabman, and publican.

A fairly well-nourished man, of sallow complexion, dark hair and eyes.

He has numerous gouty deposits in the phalangeal and metacarpo-phalangeal joints of both hands.

The wrists on both sides are also affected, but to a less extent.

The bursæ over the olecranon processes of the forearms are also the sites of deposits.

Tophi are present in both ears, and there are a few hardened acne-like spots on the face; no reaction with murexide test in the contents of the latter.

The knees grate markedly on movement. Both ankles are the seat of chronic (gouty) inflammation. There is no noticeable deposit in the toes.

The lungs are normal, and there is no cardiac murmur. The liver is slightly enlarged.

Most of the arteries are distinctly atheromatous.

Urine, sp. gr. 1018; a trace of albumen, but no sugar.

The eyes.—There are numerous distinct uratic deposits in the conjunctival membrane of both eyes. Those in the right eye are situated chiefly in that portion of conjunctiva which intervenes between the outer canthus and the cornea, being arranged in minute deposits around the course of two or three small blood-vessels and their branches.

The deposits in the left eye are situated between the caruncula lachrymalis and the inner margin of the cornea.

Here also they are distributed around small blood-vessels.

The caruncula of each eye is the seat of small deposits. The murexide test showed these deposits to be urate of soda.

There are no retinal changes.

History.—Up to the age of forty—thirty-three years ago—the patient enjoyed good health.

At this time he suffered from an attack of acute gout, which affected, in the main, the joints of the hands, the ankles, and the knees. Since that date he has been subject to frequent subacute attacks.

He first noticed the formation of chalk-stones in the fingers about four years subsequent to the onset of the disease. The appearance of tophi in the ears is of more recent date.

The patient was unaware of the deposit in the eyes until they were pointed out by me two years ago.

He states that he has always been a constant and consistent drinker, but never (he says) has he demeaned himself by actual intoxication.

There is no history of lead-poisoning, or of his having been exposed to the influence of that metal.

The family history is good, and, as far as can be ascertained, quite free from any gouty tendency.

XVIII.—*Cases of Abscess beneath the Diaphragm in connection with Perforating Gastric Ulcer.* By F. G. Penrose, M.D., and Lee Dickinson, M.B. *Read January* 13, 1893.

We venture to bring these cases before the notice of the Society, although not having much that is new to communicate, because we are of opinion that the condition to be discussed is deserving of more attention than it has hitherto received. In the text-books on medicine there is very little mention of these abscesses, and their physical signs are certainly not widely known ;* but scattered through medical literature is a considerable number of published cases, and the fact that we have collected ten from the records of St. George's Hospital during a period of little more than four years is sufficient evidence that they are not so rare as to be mere pathological curiosities.

In the year 1845 a case which had been diagnosed correctly was published by Drs. Barlow and Wilks, but the subject does not seem to have attracted much attention till a paper apppeared in 1879, by Leyden, under the title of "Pyopneumothorax Subphrenicus."† In this paper the origin of gas-containing abscesses beneath the diaphragm was traced to perforation of the stomach or intestine, and the method of diagnosis was clearly set forth.

To state the physical signs briefly, they are or may be identical with those of true pneumothorax, though obtained over an area different from what is usual in the latter condition. Hyper-resonance on percussion, amphoric breathing, metallic tinkling, and the bell-note may all be present, and may extend for some distance up the thorax, but not to its summit, where on auscultation and percussion normal phenomena are found to persist; moreover the heart is displaced far less than by true pneumothorax. The history will usually show that the onset of the disease was in the abdomen and not in the thorax, and that dyspeptic troubles have existed for long. The diagnosis

* See an interesting paper by Dr. Sidney Coupland, "Subphrenic Abscess simulating Pneumothorax," *Brit. Med. Journ.*, March 23, 1889.

† *Zeitschr. f. klin. Med.*, Bd. i, Heft 2, s. 320.

is not as a rule very difficult, especially if the case comes under observation at an early period; but there are certain thoracic complications which are apt to occur, and may be extremely misleading, and even at an early period pericarditis and pneumonia may be simulated with considerable closeness.

Simulation of pneumonia.—Compression of the base of the left lung is apt to occur early, and in a patient who is acutely ill, dyspnœic and intolerant of much examination, may be mistaken for pneumonic consolidation (see Cases 6 and 9). In Case 6 either true pneumonia was contracted about the same time that the stomach was perforated, or was very closely imitated afterwards in more ways than one, and here the lower lobes of both lungs were affected.

With compression of the base of the lung there is usually pleurisy and some effusion of fluid.

Simulation of pericarditis.—Pericarditis may actually result from the inflammatory process penetrating the diaphragm from below (as in Case 2), or it may be simulated by the presence of lymph on the outer surface of the pericardium (Cases 1 and 10).

Dr. Ord, who observed signs of endo- and peri-carditis in patients suffering from ulcer of the stomach, has suggested that the cardiac and gastric changes may be the common result of a disturbance of the pneumogastric nerve;* but in our cases such an hypothesis is not necessary, for in those in which the signs of pericarditis were present during life a simple explanation was forthcoming after death.

Pleurisy, it has been said, is commonly caused at the base of the left lung, and there may even be an empyema in the left pleura without perforation of the diaphragm (see Case 5).

Lastly, perforation of the diaphragm is a frequent sequel of these abscesses with resulting pyopneumothorax or pulmonary abscess (see Case 9).

In every one of the ten cases communicated, seven of which were personally observed by one or both of us, the abscess was situated in the left upper abdomen, and bounded in much the same manner. In all but four (Cases 2, 3, 4, and 7) the general cavity of the peritoneum was completely shut off from the abscess by adhesions, and in the four exceptional cases there was a very definite, though imperfectly closed, abscess cavity.

* "Cardiac Symptoms in Conjunction with Gastric Ulcer," *Proc. Med. Soc.*, vol. xv.

It seems that in a considerable proportion of the cases where perforation of the stomach causes general peritonitis, this peritonitis has been within a reasonable distance of being limited by adhesions in the left hypochondrium or its vicinity. During the last ten years (1882—1892) there have been examined *post mortem* at St. George's Hospital twenty-two patients who died with peritonitis from the perforation of a simple gastric ulcer. In ten of these cases there is in the records no mention of a circumscribed cavity in connection with the ulcer, though in many the stomach had contracted adhesions to neighbouring organs. In one the perforation led into an incompletely closed cavity between the under surface of the left lobe of the liver and the upper surface of the stomach. In one, the patient having died from loss of blood, the perforation led into a cavity full of blood formed by the liver above, the head of the pancreas behind, and by the stomach and colon below and in front. The remaining ten have been communicated. The boundaries of the abscess caused by a perforating gastric ulcer appear, as we have said, to be fairly constant. In Cases 6, 8, 9, and 10 they were as follows :—Above, the arch of the diaphragm; on the right, the falciform ligament; below, the left lobe of the liver and part of the anterior surface of the stomach, to which it adhered; in front, the anterior abdominal wall, to which also the stomach adhered; on the left, the cardiac end of the stomach, the spleen, and the diaphragm, there being a deep pocket behind between these organs. The abscess was shut off from the general peritoneal cavity by the adhesions between the stomach and the anterior abdominal wall. The large intestine was in no way implicated.

Although these abscesses usually occur first to the notice of physicians, it is obvious that their rational treatment is surgical, and it is with the hope of learning by what method of operation they can best be opened, how the pocket in the direction of the spleen can best be drained, and whether it is feasible to close a gaping gastric ulcer, that we bring this paper before the Society.

In an interesting article by Mr. J. W. Taylor, in the *Birmingham Medical Review* for 1888, the surgical treatment of perforation due to gastric ulcer is discussed, and a case is narrated in which he performed laparotomy, and which came very near to recovery. In this article and in recent books upon abdominal surgery suggestions are made for the surgical treatment of the perforated ulcer itself, when this

may be practicable; but we have not found any published record of such treatment having been carried out with ultimate success, though perforated ulcers have been sutured or otherwise dealt with. In the British Isles such operations have been reported by Messrs. Barling* and Parsons.†

Our best thanks are due to the physicians and surgeons of St. George's Hospital, under whose care our cases have been, for so kindly allowing us to publish them. P.S.—Since this paper was written, a successful case of suture has been reported by Kriege (*Berl. klin. Woch.*, December, 1892).

Case 1.—Elizabeth C., æt. 24, who had suffered for some months from debility and dyspnœa, and had during the previous night been attacked by severe epigastric pain, was admitted into St. George's Hospital on the morning of December 4, 1887, under the care of Dr. Dickinson, obviously with peritonitis, and with considerable disturbance of respiration and circulation. On December 5, friction sounds, having all the characters of those present in pericarditis, were plainly audible along the right border of the sternum from the third to the fifth costal cartilage; moreover there was tenderness over the whole præcordium. Afterwards pleural friction was heard in the left axilla. These signs, taken in connection with the fact that there was great liability to syncopal attacks, seemed to indicate that, in addition to peritonitis and pleurisy, there was pericarditis.

When the patient had been in the hospital six days she was attacked by diphtheria, and she died on December 11.

Post-mortem.—It was found that there was no general peritonitis, but an abscess, caused by a perforating ulcer on the posterior wall of the stomach, existed between the diaphragm and the liver, bounded on the right by the falciform ligament, and pushing up the left leaflet of the diaphragm. A layer of soft lymph coated the lower part of the left pleura, which cavity contained five ounces of fluid.

There was no trace of pericarditis.

Case 2.—Ellen W., æt. 24, was admitted under the care of Dr. Cavafy on March 10, 1888. Her manner was hysterical, and a satisfactory history was not obtained. Her chief symptom was pain referred to the lower part of the chest and upper abdomen, and the temperature was irregular.

* *Brit. Med. Journ.*, Jan. 9, 1892.

† *Dublin Journ. of Med. Sci.*, July, 1892.

When she had been in the hospital six days she had a violent rigor, followed by severe abdominal pain and collapse, death occurring a few hours later.

Post-mortem.—An abscess was found between the stomach and diaphragm containing a pint of foul-smelling pus. The walls of this abscess were composed of thick old inflammatory tissue, which completely coated the left lobe of the liver and the spleen. The stomach was pushed down and adherent to the diaphragm on its anterior surface, midway between the small and large curvatures. On the posterior surface of the stomach was the scar of an old ulcer with a depressed centre, which, it was thought, had by its perforation caused the abscess. There was dirty yellow fluid in the peritoneal cavity, with signs of early general peritonitis.

It was noted that the inflammation had penetrated the diaphragm, the pericardial surface of which was markedly injected, and fine shreds of lymph covered the ventricles.

Case 3.—Annie J., æt. 23, who had suffered from severe symptoms of gastric ulceration for twelve months, was admitted on September 27, 1888, under the care of Dr. Ewart, with acute peritonitis, and died two days later.

Post-mortem.—The general peritoneum contained much gas and brown fluid which had escaped from an imperfectly closed cavity of a capacity of 1½ pints, formed by adhesions in the left upper abdomen. This cavity was between the left lobe of the liver, the diaphragm, the spleen, and the stomach, and it was lined by a thin layer of lymph.

The stomach was constricted about its middle, so as to be hour-glass shaped. Near the constriction were three ulcers, two on the posterior and one on the anterior surface, the last opening freely into the cavity.

Case 4.—Charlotte W., æt. 58, had suffered from dyspeptic pains for some years, and hæmatemesis once, in 1887. One day soon after the middle of September she vomited about half a pint of blood, afterwards suffering much from abdominal pain, faintness, and frequent vomiting, which continued till her admission, on October 3, under the care of Dr. Dickinson.

The diagnosis was peritonitis with incomplete obstruction of the bowel. The patient refused to allow an exploratory operation, and died of exhaustion on October 13.

Post-mortem.—There was early general peritonitis with

much gas in the peritoneal cavity. Between the left lobe of the liver, the stomach, and the diaphragm was an abscess containing "a quantity of pus." On the anterior surface of the stomach, just below the small curvature and three inches from the pylorus, was a simple perforation of the stomach of the size of a shilling, communicating with the abscess.

The colon was narrowed at the splenic flexure by inflammatory bands, on freeing which pus escaped from the abscess.

The thoracic organs were displaced upwards, the base of the left lung being adherent to the diaphragm.

Case 5.—Eliza K., æt. 22, who gave no history pointing to old gastric ulcer, was seized with pain beneath the sternum and shivering, a week before admission. There was no vomiting. She took to bed five days before admission, and one day later had sharp pain in the left chest.

When admitted, under the care of Dr. Cavafy, on March 6, 1890, pneumonia seemed the most probable diagnosis. She was in much respiratory distress, and the abdomen was distended and tender. Temp. 103·5°; pulse 150; resp. 48. The right side of the chest was normal, but the left side was too tender for complete examination; however, scodaic resonance was found in front, and behind there was dulness over the lower two thirds, with tubular breathing, bronchophony, and sharp crepitations.

The patient was fed by the mouth, and had no vomiting except occasionally after expectorant medicine that was given.

On March 8 the abdomen was more distended, and a purpuric eruption had appeared upon the left shoulder.

On March 9 she died suddenly in an attack of dyspnœa.

Post-mortem.—An abscess was found between the upper surface of the left lobe of the liver, diaphragm, spleen, posterior surface of the stomach, and anterior abdominal wall.

In the stomach, on its posterior wall, was an old cicatrised ulcer and a large recent perforation into the abscess.

The left pleura contained 1½ pints of thin pus, and there was much lymph on the upper surface of the diaphragm. The left lung was much compressed.

Case 6.—Frances D., æt. 18, a general servant, who had been pallid for long, and had suffered from dyspepsia for fifteen months without hæmatemesis, was seized on November 19, 1890, while walking out of doors, by sudden severe pain in the left hypochondrium. She was unable to walk

home, and during a delay, which ensued in procuring a cab, she suffered exposure to cold.

When admitted on November 21, under the care of Dr. Ewart, she was very nervous, hysterical, and chlorotic. Her chief complaint was of abdominal pain; there was great tenderness in the upper part of the abdomen, and peritonitis was suspected. Next day consolidation of the base of the left lung was found. She was fed by the mouth, and had no vomiting nor pain after food. On November 25 the lower lobes of both lungs were consolidated.

This condition of double pneumonia underwent very slow resolution, the temperature, which had been 104° on November 24, subsiding gradually in the course of three weeks in a manner suggestive of an irregular pneumonic lysis. There was now a return of fever and serious symptoms. On December 17 a careful examination of the chest showed that the right lung had returned to its normal state, but that on the left side, just above the spleen, pure amphoric breathing was audible, and a perfect bell-note could be obtained by percussion with a couple of coins. At the posterior base there was evidence of some effusion of fluid.

These physical signs varied a little from day to day, but those especially characteristic of pneumothorax were always present. Many rigors occurred, and the patient died on January 1, ordinary gastric symptoms having been in abeyance throughout.

Post-mortem.—There was no pneumothorax. There was an effusion of turbid fluid into the left pleura, partially compressing the lower lobe of the left lung. An abscess cavity was found containing air and pus between the diaphragm, spleen, upper surface of the left lobe of the liver, and anterior abdominal wall. Opening into this abscess was a small perforating ulcer on the anterior wall of the stomach, near the cardiac end. There was also a ragged abscess in the substance of the spleen which communicated with that beneath the diaphragm.

Case 7.—Agnes D., æt. 21, had suffered from dyspeptic pains for some years, and these pains had been severe since the beginning of 1891. There was no hæmatemesis. On May 12 she was seized with sudden violent pain in the abdomen, and on May 15 she was admitted under the care of Dr. Dickinson. There was agonising pain in the upper part of the abdomen with general tympanitic distension and fre-

quent vomiting, the vomit containing blood towards the end. She was fed by the rectum and the pain was controlled by morphia, but death occurred on May 19.

Post-mortem.—The abdomen was greatly distended by gas, and the intestines were collapsed. A few coils of the ileum were injected, but there was no general peritonitis. In the left hypochondrium was a recent abscess opening into the general cavity of the peritoneum by an orifice half an inch wide. The walls of this abscess were covered by lymph, and were formed by the cardiac end of the stomach, the spleen, the left half of the diaphragm, and the left lobe of the liver. Although this abscess communicated with the peritoneal cavity, nothing but gas appeared to have escaped into the latter. The stomach was divided into two parts by a contracting ulcer, which had perforated the anterior surface and communicated with the abscess by an opening as large as a sixpenny piece.

There was lymph on the diaphragmatic surface of the right lobe of the liver and at the base of the right lung, the lower lobe of which was partially collapsed. The lower lobe of the left lung was completely collapsed, the diaphragm being much pushed up. The pericardium and heart were normal.

Case 8.—Agnes A., æt. 21, a kitchenmaid, who had suffered from the ordinary symptoms of anæmia and dyspepsia, without hæmatemesis, for a year or more, was attacked by sudden severe pain in the left side of the abdomen at 5 P.M., October 14, 1891.

When admitted at 3 P.M., October 16, under the care of Dr. Cavafy, she was found to be a plump and moderately anæmic girl, with a tympanitic, tender, and motionless abdomen. Temp. 104°; pulse 152; resp. 26. She was ordered to have fluid food and opium pills by the mouth.

Up to October 19 there was little change in her condition, but now there was pain high up in the left hypochondrium, and signs of pulmonary consolidation were present in the left axilla and at the back. Next day there was a large area of tympanitic resonance in the region of the stomach, passing upwards and backwards into the left axilla. This area was very tender, and over part of it a bell-note was obtained. The left pleura was aspirated, and 6½ oz. of sanious serum were withdrawn. Little relief or other change followed, and on October 23 the tympanitic area was rather larger, and

the heart's apex was pushed up into the fourth interspace. There was and had been no vomiting, in spite of the fact that food and stimulants were given by the mouth. The epigastrium was now painfully distended, and the general condition was critical.

A consultation was held, at which it was agreed that the existence of an abscess in connection with a perforating gastric ulcer was probable, and an exploratory operation was advised.

At midnight Mr. Haward performed laparotomy. He found a large gas-containing cavity beneath the abdominal wall, in which were milky fluid and shreds resembling semi-digested curds. This cavity was taken for the stomach, and the edges of the supposed stomach were sewn to the wound in the abdominal wall. The condition of the patient prohibited further operative measures. She was fed by the rectum after the operation. She had no vomiting and no pain, but the temperature rose to 107·6° by 2.30 P.M., October 24. The pyrexia was reduced by sponging, but death occurred at 12.15 A.M., October 25.

Post-mortem.—There was found no general peritonitis. The wound in the abdominal wall led into a cavity lined by lymph and bounded by the falciform ligament, the upper surface of the left lobe of the liver, the anterior surface of the stomach, and adhesions between this and the anterior abdominal wall, the diaphragm, and the spleen. In the neighbourhood of the last-mentioned organ the inflammation was most intense. An ulcer had perforated the anterior wall of the stomach into this cavity.

The lower lobe of the left lung was completely collapsed, the base adhering by recent lymph to the diaphragm, and there was lymph over the whole of this pleura.

The pericardium and heart were normal except that the latter was pale.

Case 9.—Louisa J., æt. 21, a paper bag maker, who gave a history of anæmia and severe dyspepsia of six months' duration, but no hæmatemesis, was seized with severe pain at the front of the chest immediately after eating a small piece of plum pudding on Christmas Day, 1891. She spent the next eight days chiefly in bed, with a continuance of pain, and shivering and sweating at times.

On January 2 she was admitted under the care of Dr. Whipham. At this time she was fairly plump and rather

anæmic, in some respiratory distress, with pain in the left hypochondrium and at the front of the chest, a temperature of 101·5° to 102·5°, and physical signs at the base of the left lung which were thought to be those of pneumonia. The epigastrium was distended and very tender. She was ordered to be fed partly by suppositories and partly by fluids by the mouth; and she took the latter without inconvenience.

On January 6 there were sharp pain and friction over an extensive area on the right side of the chest; and a bell-note was obtained over the epigastrium.

On January 8 the epigastrium was more distended and tympanitic, and there was considerable dulness in the left hypochondriac and lumbar regions. It was decided that an exploratory operation was necessary, and at 8 P.M. Mr. Pick performed laparotomy. He found a large abscess cavity between the stomach and the diaphragm containing much intensely foul gas, and about a quart of pus. When the cavity had been emptied and irrigated a large drainage-tube was inserted.

After the operation food was given by the mouth as before, and the cavity was washed out daily with a solution of corrosive sublimate. The patient progressed fairly well till January 17, when a rigor occurred, and there was great pain near the spleen. For three days she was in a state of great prostration, but then rallied; and it is possible that this was an attack of influenza. However, another rigor occurred on January 23. On January 28 fluid was suspected in the left pleura, but an exploratory syringe failed to find it. The abscess cavity did not contract, the drainage-tube remaining fully four inches long; and the discharge was generally fœtid.

All this time the left lung was very much embarrassed. There was gradual loss of strength with sweating, though the patient took food well.

On February 13, an œdematous swelling having formed over the left lower ribs behind, Mr. Pick incised it, but no pus was found. The breathing at the base of the left lung was very faint and almost cavernous in character. The urine contained pus, and there was soft œdema of the feet and legs.

On February 15 thoracentesis was performed on the left side, 6 oz. of a fœtid mixture of blood and pus being withdrawn. It was found that a probe entering at the abdominal wound could be passed far up into the left chest, and coughing was set up by syringing out the abdominal wound.

The patient died on the evening of February 21.

Post-mortem.—The small sinus remaining from the operation wound was found to run over the left lobe of the liver to the region of the spleen, where it ended in a branching abscess surrounding this organ. There was no suppuration in the spleen itself. At the cardiac end of the stomach on its anterior wall was a small puckered spot where perforation had probably taken place; between this and the under surface of the left lobe of the liver to which it was adherent was some pus.

There was no general peritonitis. The suppuration around the spleen had perforated the left leaflet of the diaphragm, and set up a gangrenous abscess in the lower lobe of the left lung. There were a few shreds of lymph over the base of the right lung. The pericardium was adherent to the left lung, but normal internally. The heart was dilated and fatty.

Case 10.—James G., æt. 40, a harness maker, who had suffered for long from dyspepsia, and for a month from acute dyspeptic pains, was admitted, under the care of Dr. Penrose, at 10.15 A.M., March 12, 1892. Two hours previously he had breakfasted upon bread and marmalade, which was for him an unusual indulgence in solid food. One hour after this repast he was attacked by sudden acute pain in the left upper abdomen.

On admission he was found to be a spare, pale man, with sour breath and heavily coated tongue. At first he was in acute pain and somewhat collapsed, but he rallied in the course of a few hours. When he was now examined carefully, the abdomen was tight from muscular contraction and too tender for satisfactory exploration; there was a tympanitic percussion note extending far up over the front of the chest, and the heart was pushed up, its sounds being audible, though very faintly, above the left nipple. Castor oil and fluid food were given by the mouth and caused no vomiting or pain.

On March 13 percussion over the thorax not being painful, a remarkable tympanitic area was mapped out. This tympanitic area extended from the epigastrium (where its limit could not be accurately defined) upwards over the front of the chest to the third right costal cartilage, where it reached its apex, not extending far either to the right or to the left. A bell-note was obtainable over the lowest part of this area only. See Fig. 1.

On March 14 the patient was in much the same condition,

quiet upon his back, in some dyspnœa, but in little pain and with a non-febrile temperature. At 5.30 P.M., loud friction, with both a cardiac and respiratory rhythm, was heard between the left nipple and the sternum. For diagnostic purposes, and to give relief to a distressing feeling of distension from which the patient suffered, the tube of a stomach-pump was passed down the œsophagus into the stomach. A little bilious green mucous fluid was ejected through the tube, and then the stomach was washed out with warm water. The fluid ejected and the washings were alkaline. After this procedure the patient felt much more comfortable. The area of tympanitic resonance contracted all its boundaries slightly.

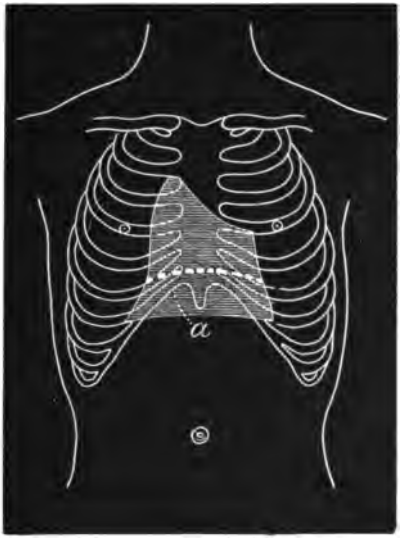

Subsequently the tympanitic resonance extended further towards the left hypochondrium, and the friction disappeared in the course of March 15. Nutrient suppositories not being well retained, food was given almost entirely by the mouth, and was well received.

On March 16 the left lung was found to be greatly compressed. The area of tympanitic resonance extended further into the epigastrium and left hypochondrium; the bell-note was obtainable only below the level of the sixth rib, and at the same level the percussion-note became modified in cha-

racter, being decidedly lower pitched than above. The temperature was still fairly low—99·6° to 100·6°—but the respirations were 48, and the pulse was 126, and febrile in character. Dr. Whipham saw the patient with Dr. Penrose, and an exploratory operation was decided upon.

At 10 P.M. Mr. Turner operated, making an incision in the middle line of the epigastrium. A large quantity of rather foul gas was let out from a cavity beneath the abdominal wall. Beneath the gas were about two pints of thin pus. There was no food in this abscess. The cavity was irrigated with a solution of corrosive sublimate, and a large drainage-tube was passed down in the direction of the spleen.

The patient was supported upon his right side to favour drainage from the depths of the cavity, but he died exhausted at 6 A.M., March 18.

Post-mortem.—The abscess-cavity was found to be bounded by the falciform ligament, the diaphragm, the spleen, the anterior abdominal wall, and the stomach, the left leaflet of the diaphragm being pushed up a considerable distance into the thorax.

On the posterior surface of the stomach was a large ulcer which had perforated and set up this abscess, and in the stomach were two other ulcers which had not perforated.

There was slight recent peritonitis in the dependent parts of the abdomen, possibly set up by the operation.

In the left pleura were 5 oz. of turbid fluid and much lymph over the lower part. The lower lobe of the left lung was much collapsed. The pericardium was inflamed externally on the left side, but internally showed no lymph. The heart showed advanced cloudy swelling.

XIX.—*A case illustrating a more effectual method of removing a Cancerous Breast, Lymphatics, and Glands.* By W. Arbuthnot Lane, M.S. *Read January* 21, 1893.

THE following brief details of a case of amputation of the breast and the removal of the lymphatic channels and glands serves to illustrate sufficiently well for my purpose the method suggested.

E. C., æt. 53, had, for three years, observed a tumour in her breast, which on her admission in August, 1892, was found to be cancerous and to be attached to the skin at one point. Some very small glands could be felt in the axilla.

Two long incisions were made, and the breast with the pectoral muscles and fasciæ were removed, and the several remaining walls of the axilla were freely exposed. The skin about the seat of the tumour was also freely removed. A chain of thickened infiltrated lymphatic vessels was found lying on the chest between the attachments of the pectorals. These then crossed the pectoralis minor very obliquely, and perforated the costo-coracoid membrane. The axillary vessels and nerves were carefully cleaned and the whole of the lymphatic glands and vessels and the areolar tissue of the axilla were dissected away. Some of the glands were enlarged, and obviously contained secondary growth. The skin was brought together accurately with continuous sutures, and a drainage-tube was left in for twenty-four hours. The subsequent progress of the case was very satisfactory.

For some time I have felt very dissatisfied with the results of the ordinary method of removing the breast and clearing the axilla for cancer of that organ, and have attempted to extract the lymphatic glands more effectually by dividing the pectorals in front of the axillary vessels, and, if necessary, cutting through the clavicle also, subsequently wiring the latter and suturing the divided surfaces of the former together.

Although by these means I was able to dissect out,

apparently, every bit of areolar tissue and the lymphatic glands and leave the vessels and nerves cleaned and exposed, I found that recurrence still took place, although at an interval of time that seemed to me definitely longer than after the usual methods.

While operating for the removal of such recurrences I found in every case a chain of thickened cancerous lymphatics extending upwards and outwards in the direction of the costo-coracoid membrane, and obviously continuous with the secondary growths in the apex of the axilla and about the subclavian vessels, and that this chain lay between the pectorals, sometimes partly upon the chest wall between the attachments of the muscles, and upon the pectoralis minor.

It was at once apparent that this must be, in most cases at least, the source of secondary infection, and that—while one imagines that in amputating the breast and apparently effectually clearing the axilla of its lymphatic glands that the lymphatic vessels, which transmit the cancer elements which are infiltrated with them, are also removed—much of the infiltrated lymphatic channels are left untouched and unseen by the surgeon at the operation. The treatment I habitually adopt now, and which I would suggest for your consideration, is the removal of the breast and pectoral muscles at the same time, the careful dissection of the axillary vessels and nerves and the thorough excision of the areolar tissue and lymphatic vessels and glands, and also, if necessary, the division of the clavicle and the dissection of the lymphatic vessels and glands from the neighbourhood of the subclavian vessels.

Sometimes after removing the pectoralis major, dividing the pectoralis minor and clearing the axilla, it may seem safe to suture the portions of the latter muscle together, and again in suitable cases it may be advisable to bring together the upper parts of the pectoralis major also.

Sufficient time has not yet elapsed for obtaining any very accurate information of the increase in the duration of freedom from secondary growth which this method affords, but common sense and experience would lead one to consider that the more efficient removal of the growth and its extension will be followed by a corresponding delay in its recurrence, and that if such an extensive operation be performed early enough the disease may be satisfactorily eradicated.

That the usual method of clearing the axilla of its lymphatic glands and channels, through an incision in the fascia forming the floor of that space, is imperfect in its result is

quite obvious to anyone, if, after he has apparently thoroughly cleared the axilla in this manner, he cuts through the pectorals and the costo-coracoid membrane where they form its anterior axillary wall. He will then find much areolar tissue, with lymphatic glands and vessels which he has failed to take away. I believe that the still more radical treatment for the removal of cancer of the breast, which I have described in this short paper, will be found most serviceable, at least to delay the progress of the disease very considerably, if not to eradicate it completely from the system.

XX.—*On the relative merits of a vertical and of a transverse incision in Supra-pubic Cystotomy. With cases.* By Robert William Parker. *Read January* 27, 1893.

IN the following paper I wish to bring before the Society some interesting cases of disease of the bladder, and at the same time to draw attention to the advantages of a transverse over a vertical incision in opening the bladder above the pubes.

A transverse incision has long been advocated and practised by various surgeons in single instances, Günther and Bruns being amongst the earliest to do so. But I must acknowledge my chief indebtedness for the suggestion to an able and interesting paper on Supra-pubic Cystotomy, by Dr. Eigenbrodt, in the twenty-eighth volume of the *Deutsche Zeitschrift für Chirurgie*. The cases were under the care of Professor Trendelenburg, of Bonn, who appears to be the first surgeon to have systematically adopted the transverse incision.

As the patient lies on his back, the usual position for supra-pubic operations, the edges of a vertical incision between the rectus muscles become quite tense, rendering retractors necessary. But after a transverse incision through the insertions of the rectus muscles and the fibrous tissues behind them, spontaneous retraction of the incised structures takes place, affording not only a ready access for eye or finger, but also in cases needing it, free drainage.

Among the obvious advantages of a transverse incision, in my opinion, is the freer access to the bladder thus obtained; and the bladder can be opened at one of its least moveable points, viz., close behind the pubes—where the opening will longest correspond with the incision through the abdominal wall.

I will record five cases in which the bladder needed opening. Two of these were operated by the older method, a vertical incision, and the remaining three by the newer method, a transverse incision. In some measure I was influenced to adopt the newer method by the difficulties which attended the first two cases.

Case 1. *Perforating wound of rectum and bladder; temporary recovery; six months later vesical calculus, with piece of trowsers-cloth as nucleus; supra-pubic (vertical) cystotomy; recovery.*—John S., æt. 14 years, came under my care in the German Hospital in January, 1891. Some six months previously, he was at work, standing on a ladder about ten feet from the ground, when he fell on to a crowbar which was standing in a hole in the ground near by. The point of the crowbar entered the rectum, cutting its anterior commissure and then passed into the bladder. The boy was very ill, everything passed through the perinæal wound for several weeks without the patient's control. In six weeks some urine began to pass *per urethram*; later on phosphatic concretions were washed out. By November he was greatly improved and was discharged, the urine being fairly clear and healthy and passed without difficulty.

When readmitted, he was suffering from severe cystitis; the urine was very offensive, contained a large quantity of pus and mucus, and was being voided every hour or oftener night and day. The wound through the rectum into the bladder was completely closed and the patient had regained control over both organs; but he was suffering great pain in his perinæum, looked ill, and was exhausted from want of sleep. On sounding the bladder, a stone was at once detected.

Supra-pubic cystotomy was decided upon. When the attempt was made to distend the rectum and push forward the bladder, it was found impossible to do so in consequence, as I subsequently found, of adhesions between these two organs and their fixation in the pelvis by cicatricial growth, the result of the previous accident. For this reason the operation was a difficult one, the bladder being very fixed and very deeply placed in the pelvis. The usual vertical incision in the median line was made. On looking into the bladder, as the boy lay on his back, it was found to have assumed an elongated figure-of-eight shape. The lower portion, that adjoining the urethra, was about as large as a pigeon's egg, and formed the receptacle for urine; the upper portion was more elongated and contained the calculus; the calculus was so tightly gripped by that portion of the bladder, that only after considerable manipulation with the finger, could it be freed. The calculus was soft like half-dried mortar, and crumbled when seized with forceps. As a nucleus there was found a piece of trowsers-cloth, which had evidently been carried into the bladder by the crowbar at the

time of the accident. The greater part of the calculus was removed by irrigation; but 790 grains of calculous material and the cloth-nucleus were preserved.

Remarks.—In this case, owing to the deep position of the bladder, its fixation to the rectum and the impossibility of raising it out of the pelvis, the operation was a difficult one, for the rectus muscles gripped the finger like a sphincter, and required constant and continuous retraction. My later experience convinces me that a transverse incision would have materially lessened these difficulties. I suspect the piece of cloth which formed the nucleus of the calculus, more or less plugged the original opening in the bladder and so facilitated its closing by granulation tissue. Thanks largely to the careful supervision of Dr. Lacher, my then house surgeon, the patient made an excellent recovery, and remains well to the present time.

Case 2. *Recurrent stone in the bladder; supra-pubic (vertical) cystotomy twice; median lithotomy once; permanent recovery.*—J. M., æt. 11, was first admitted into the Children's Hospital, Shadwell, in March, 1889, with symptoms of stone in the bladder. Supra-pubic cystotomy was performed and the boy was discharged well after a somewhat slow convalescence. The most noticeable feature of the case was the tendency to phosphatic deposit upon the tissues forming the boundaries of the wound. Fifteen months later (June, 1890), he was readmitted with further symptoms, and a second stone was removed, also by the supra-pubic method; there was the same tendency to phosphatic incrustation in and about the wound, which again delayed union. He got also some suppurative inflammation about his parotid gland on the right side, associated with abdominal tenderness, but without peritonitis. In June, 1891, he was admitted for the third time. On this occasion his symptoms were much more urgent and serious. After several days of increasing difficulty in micturition, his parents had brought him, on account of almost complete inability to pass urine. There was fulness in the neighbourhood of the old scar, with heat, great tenderness and slight œdema; it appeared as if there was suppuration around the bladder. The temperature varied from 103° to 105° F. Awaiting my arrival at the hospital, a hot bath was ordered but failed to give any relief. On attempting to pass a catheter, a stone could be felt projecting through the neck of the bladder into the urethra, where it was so tightly impacted, that the catheter could not be got

into the bladder, nor any urine drawn off. Under these circumstances, I cut down in the median line of the perinæum, and after some little difficulty, owing to its shape, removed the stone. Next, I incised the abdomen in the median line, close to the symphysis, and let out a large quantity of stinking pus and urine. It was now clear that the bladder had ruptured, probably in consequence of the straining efforts to pass water. I, at first, inclined to think that one or other of the former incisions had given way again. On the other hand, the extent of the pelvic cellulitis, the manner in which the base of the bladder was dissected out by the pus, as also the position and impaction of the calculus, rendered it more probable that there was some ulceration at the neck of the bladder which had permitted the urine to escape.

The abscess cavity was then thoroughly washed out with boracic solution until it returned quite clear; the bladder, also, was washed out. The lad made a slow but complete recovery. There was no phosphatic deposit either in the supra-pubic or perinæal region. During his convalescence, treatment consisted in irrigating the incisions very freely twice every day, and keeping the patient for some hours daily on his face to promote drainage.

Case 3. *Recurrent stone in the bladder; cystitis; supra-pubic cystotomy by means of a transverse incision; irrigation; recovery.* —William W., aged 53, admitted into the German Hospital in June, 1890. He had suffered from cystitis and stone in the early part of 1889, and was operated on by the usual supra-pubic method. The stone was very soft and friable. The incision healed well, and the man left the hospital much improved, but with some cystitis still persisting.

In April of 1891 he applied again, his bladder troubles having become much worse lately. He was out-patient under the care of my colleague, Dr. Ernst Michels, who, on examination, detected another stone in the bladder. The patient has been in the habit of washing out his bladder, but, notwithstanding, the urine was found to contain a large amount of pus and phosphates. The cystitis was treated for some time very systematically by injections of nitrate of silver (2 per cent.), but without very great benefit, so it was decided to admit the man and crush the stone without further delay, and to thoroughly wash out the bladder afterwards.

On June 13, the rectum and bowels having been emptied, and chloroform administered, I attempted lithotrity, but, in

spite of every endeavour, I could not seize the stone with the lithotrite, though the stone could be felt as the instrument came in contact with it. My colleagues were not more successful. Under the circumstances the bladder was washed out, and the man sent back to the ward—it being thought advisable not to do anything further just then.

On June 16 there had been no unfavourable reaction of any kind, either local or general. The man was again anæsthetised, and the bladder was approached through a transverse incision, close above the pubes. The incision was between three and four inches long. There was a good deal of firm, fibrous tissue beneath the rectus, and between it and the bladder—the result of the former operation. The bladder was quickly reached and opened, and, on introducing a finger, a large stone was found. The top of this stone was projecting from a sacculus. When seized with forceps, the stone crumbled. It was removed partly with a scoop, and chiefly by means of free irrigation after it had been broken up. The bladder presented other pouches besides the one containing the stone. The mucous membrane was inflamed, and showed traces of ulceration in places. The prostate was large.

The after-treatment consisted, at first, in washing out the bladder daily; then, later on, hip baths were taken. The recovery was uninterrupted. On his discharge from the hospital, after cicatrisation of the wound, there were still some remnants of cystitis, for which he was again treated by Dr. Michels, under whose care he continues, as the cystitis recurs a little from time to time.

A transverse incision in this case was useful, for, besides giving very direct access to the bladder, it enabled the surgeon to avoid the cicatrix of the former incision. Moreover, the opening into the bladder was a large one as well as direct, and, by remaining open, facilitated the subsequent treatment by irrigation and baths.

The cicatrix is now quite firm. The man (who was shown) is not sensible of any weakness or loss of power, such as might be anticipated after cutting through the attachments of the rectus muscles.

Case 4. *Compound comminuted fracture of the right femur; separation of the symphysis pubis; extensive contusions of perinæum, loins, &c.; rupture of bladder; dislocation of the penis; transverse supra-pubic cystotomy.*—Henry F.,

aged nine years, having been run over by a loaded van, was admitted into the German Hospital on June 27, 1891. The wheel had passed obliquely, from without inwards, over his right thigh, causing a compound comminuted fracture of the femur, with the other injuries noted at the head of the case.

Above the pubes there was swelling, dull on percussion. The perinæum was greatly bruised, much swollen, and discoloured. The skin covering the penis, especially the prepuce, was bruised and empty, the body of the penis having disappeared entirely, its exact whereabouts not being very obvious owing to the swelling and tension in the perinæum. An extra-peritoneal rupture of the bladder was suspected. In presence of such symptoms, I decided to cut down upon the bladder, and I adopted the transverse incision. A quantity of blood-stained urine escaped as soon as the abdominal wall was incised. The bladder was separated from the posterior surface of the pubes, but the urethra proved not to have been torn. I could not find the opening into the bladder through which the urine had escaped. It must have been quite small, for the bladder contained a large quantity of urine; so I proceeded to incise the bladder, regardless of the existing wound. Meanwhile, a considerable decrease in the local swelling had taken place, owing to the escape of extravasated urine through the abdominal incision, as well as through other incisions which I made into the perinæum in different places. As the swelling went down, the position of the dislocated penis became evident, and without much difficulty it was gradually replaced in its skin covering, and retained there by means of a narrow web bandage lightly applied. I endeavoured to pass a catheter into the bladder but failed; so I passed one from the bladder into the penis, and retained it *in situ* for an hour or two. Lest the bruised state of the penis should be followed by swelling and closure of the urethra, I stitched the edge of the incised bladder to the skin, and so secured free drainage for the urine.

As regards the other injuries in this case, I may say that the compound fracture of the femur did very well, healing taking place with some shortening. The external wound in the soft parts was covered with cotton wool soaked in collodion. An extensive ecchymosis on the lower part of the back suppurated; the perinæum did not suppurate.

The boy made an excellent recovery. The transverse wound healed soundly. The boy has experienced no discomfort since. (He was shown to the Members.)

Case 5. *Stone in the bladder; supra-pubic cystotomy by means of a transverse incision; primary union without suture of the bladder; recovery.*—W. G., æt. 12 years, admitted January 22, 1892. The boy had experienced some "difficulty in passing water for the past five years, ever since an attack of typhoid fever;" so his mother stated. For the past three or four weeks there had been pain—referred to the groins—on passing water, especially when standing up to do so. The flow occasionally had stopped suddenly. Blood was reported present by the mother; while in hospital previous to operation, neither blood nor pain was observed. On the day previous to operation, urine was found quite clear, faintly acid, sp. gr. 1025; no blood; no albumen; no pus; no crystals.

On January 27 supra-pubic cystotomy was done, the transverse incision, close to the pubes, being adopted, after previous distension of the bladder with boric acid solution, and inflation of the rectum. An oblong, very rough-surfaced (mulberry) stone was extracted. The incision into the bladder was found to close very well, hence no sutures were put in; the edges of the abdominal incision were carefully closed with several silk sutures. A good dose of opium was administered at once. Late in the evening, a soft catheter was passed into the bladder and about 8 oz. of urine drawn off.

The subsequent history may be very briefly given. Primary union occurred both in the bladder and in the abdominal incision. There was no pain, or trouble, or extravasation. A catheter was passed about twice daily for two or three days. There was some balanitis, due apparently to irritation previous to the operation; after circumcision this quickly disappeared.

I well remember the difficulty I experienced in removing a myomatous tumour from the bladder of a young woman some four or five years ago, in consequence, largely, of the tense condition of the margins of the vertical incision between the rectus muscles. In looking back on this case (which is recorded in a former volume of our *Transactions*) I can now see the advantages which a transverse incision would have offered over the vertical one I then made use of.

I operated also two or three weeks ago, by the transverse method on an old gentleman, in one of the private wards of the German Hospital. He had malignant disease of his bladder, which gave rise to great hæmorrhage. The desire to pass water was almost incessant, so that the patient could get no rest. An opening into the bladder above the pubes

gave me the opportunity of making a thorough exploration of the bladder, and of arriving at an exact diagnosis. The man lived some days after the operation in comparative quiet and freedom from pain and annoyance. The adoption of Trendelenburg's transverse incision greatly facilitated the proceedings.

Remarks.—Any advantage which a supra-pubic incision into the bladder may possess over the sub-pubic methods is increased and amplified by substituting a transverse for the more usual vertical incision. I have opened the bladder above the pubes some twenty or twenty-five times for various purposes, and in all but the later cases, made use of a vertical incision. For the future I shall use the transverse incision entirely, as I am persuaded of its advantages, the chief of which are given at the commencement of this paper.

Quite recently I was assisting my colleague, Dr. Michels, at the German Hospital; he was exploring a bladder through a supra-pubic vertical incision. The pelvis being raised high up as recommended by Trendelenburg, I was again much struck with the rigidity of the edges of the incision, and the difficulty experienced in overcoming it. But a short transverse incision across the attachments of the rectus, quickly overcame the rigidity, and facilitated the operation, as well as the subsequent after-treatment.

The raised pelvis position, recommended by Trendelenburg, is a very useful one; the intestines gravitate towards the diaphragm and away from the bladder region.

The result in my cases shows conclusively that an *à priori* fear (which I confess to have experienced), that there might be some subsequent weakness of the rectus muscles of the abdomen is as ill-founded as that the leg is weakened by section of the tendo Achillis. On the contrary, union took place rapidly and completely, and no sense of weakness was felt afterwards.

A too free division of the muscular attachments, it has been said, might endanger the external ring and so predispose to hernia. This, too, is a danger which can be easily avoided by not making the incision too extensive. If the calculus is a very large one, too large to be removed through a medium-sized opening, the indication, of course, is to break up the stone, rather than enlarge the opening beyond due and proper surgical limits.

In cases where drainage is indicated, the face position, for some hours at a time, especially during the first few days, is

most efficient. If washing out is necessary, either irrigation or a sitz-bath may be used; a transverse incision, which keeps open spontaneously, facilitates the proceeding. The sitz-bath can, if needed, be prolonged indefinitely. A bath fitted with hot and cold taps, and an overflow, secures a constant supply of warm fresh water, which will be found very useful and convenient in cases of chronic cystitis.

In Case 5, I was fortunate to get primary union of the bladder incision, although I did not insert any sutures. The stone was not a large one; the opening into the bladder was no longer than necessary, and its edges fitted very close together. This induced me to close the external wound carefully and to order the use of a soft catheter at short intervals: a plan which answered admirably. It appears to me that an incision in the bladder close to the pubes at a spot where it is least moveable, will help to secure this very desirable result—primary union—in suitable cases. Of course the bladder itself must be healthy, a condition often found in young subjects who have been cut for stone. In old people, whose bladder is inflamed, or otherwise diseased, the object aimed at is free access, free and complete evacuation rather than rapid or early closure. Hence, in such cases, suturing is contra-indicated.

XXI.—*Subserous Uterine Hæmatocele, in a girl of eleven years, simulating acute inflammation of the vermiform appendix: laparotomy: recovery.* By Arthur E. Barker. *Read February* 10, 1893.

IN the following case an error in diagnosis was made which was perhaps pardonable in view of the very unusual features of the case, and the close resemblance which the history of the symptoms showed to those usually met with in typhlitis among children. Fortunately this child bore the laparotomy well (as most children do in my experience), so that no untoward effect followed as the result of the error.

Mabel R., æt. 11 years, admitted into University College Hospital January 26, 1892, is the eighth child of healthy parents, and is a strong healthy-looking girl. In September 1891, the child was first seized with an illness like the present. Sudden pain was felt in the lower part of the abdomen chiefly on the right side, and the patient became feverish; the bowels were confined, and she was sick several times. For this she remained in bed for a day or two. About a month or six weeks later she had a similar but slighter attack. Again during Christmas week there was another slight attack of a similar kind. None of these three illnesses had any relation to indigestible diet.

The present, or fourth attack, which began precisely like the others, was not preceded by constipation. The patient was suddenly seized at 2 o'clock A.M. on January 24, 1892, with severe pain in the lower part of the abdomen, chiefly on the right side. At 9 A.M. before breakfast she vomited for the first time. There was no distension of the abdomen. During the day she was sick several times. She was then seen by Mr. Sworn, of Holloway, who prescribed opium internally and belladonna fomentations over the abdomen. This relieved the pain and the patient vomited only twice the next day, once in the morning and once in the evening. On the 26th, the day of admission, there was no sickness, and no action of the bowels.

On admission on January 26, 1892, the patient was

rather drowsy but complained of pain in the lower part of the abdomen, on the right side. She was flushed; there was no collapse. The temperature was 101·4°, pulse 140, the tongue moist but furred. The abdomen was not distended; it was very tender all over the lower part but chiefly in the right iliac region. There was no distinct fulness in the iliac fossa but in the hypogastrium a moderately distinct firm swelling was evident on deep palpation. There was slight loss of resonance over the right iliac fossa.

Projecting into the anterior wall of the rectum a large roundish swelling was felt with the finger filling up the cavity of the pelvis. Over this the coats of the bowel were felt to be moveable; it was firm but elastic. The state of this swelling was not altered by emptying the bladder with a catheter, and it was not œdematous.

Viewing this case from all its aspects and taking into account the girl's age, the three antecedent attacks of a similar kind, the tenderness, pain and slight dulness in the right iliac region together with a swelling to be felt from the rectum, I regarded this illness as due to typhlitis resulting in an abscess among matted intestines in the pelvis. This view was shared, I believe, by all who saw the case.

Taking this view I immediately proceeded to operate for the evacuation of this intra-abdominal abscess, the idea of a pelvic hæmatocele in a girl of eleven, never having entered my head, I am bound to say.

Operation (January 26, 1892, 9 P.M.).—I made an incision downwards in the right linea semilunaris between two and three inches in length, its upper end being a little above the level of the anterior iliac spine. When the abdomen was opened healthy but slightly injected coils of intestine presented. Turning these aside, I examined the cæcum and appendix, both of which were normal. There was no lymph about, but a considerable amount of brownish, turbid serum escaped from the direction of the pelvis. Passing my hand in this direction I at once felt the tumour discovered from the rectum. This almost filled Douglas's pouch and was quite smooth upon the surface. It could not be raised out of the pelvis, but while endeavouring to bring it into view a convoluted mass was felt which I at first took to be a piece of gut twisted up and bound down by adhesions. On drawing upon it, however, it was brought into view, and was then seen to be the Fallopian tube with the ovary at its extremity. The latter was now seen to be almost black from blood clot extravasated underneath its

serous covering. The same black extravasation was seen round the Fallopian tube and between the layers of the broad ligament, and reached as far as the swelling before alluded to, which proved to be a collection of blood in the subperitoneal tissues of the broad ligament and posterior surface of the uterus, in all about the size of a hen's egg. There was no actual effusion of blood into the peritoneal cavity, but the latter contained in the neighbourhood of the swelling a certain amount of turbid serum as already mentioned. Recognising the condition now as one of subserous, pelvic, or uterine hæmatocele, I concluded that nothing further should be done, and simply dried out the pelvis and closed the abdominal wound in the usual way with silk sutures and without drainage. A salicylic wool dressing completed the operation, which had not lasted long.

While I was dressing the wound a vaginal examination was made by Mr. White, our surgical registrar, who notes that "the mass projected downwards into the posterior fornix, the cervix was pushed forwards and the os uteri was directed towards the symphysis pubis. The os was normal."

There is little further to note about the case except uninterrupted recovery. The temperature steadily fell to almost normal, and the abdominal pain soon disappeared. There was a little sickness on the 28th, and the child looked sallow, with yellow conjunctivæ. On the 29th this yellowness was increased, and the child vomited three times, in all about two ounces of bright green liquid. She also complained of pain in her abdomen. The bowels were opened twice on the 28th, but the stools were not clay colored.

By the 30th the child was practically well, though still yellow in the face. There was no pain or vomiting, and she was bright. Temperature, subnormal; pulse, 76.

On the tenth day the first dressing was removed, and the wound was found united perfectly by first intention. The stitches were then taken out.

About three weeks after operation my colleague, Dr. John Williams, was kind enough to examine the child for me, and found the tumour behind the uterus apparently *in statu quo*. He told me that even then if he had not been told to the contrary he should have thought the swelling was actually in the peritoneal cavity Such a state of things in a girl of eleven years old was unknown to him.

We kept the child in hospital until February 24, *i. e.* until thirty-one days after the onset of the last attack, with a

view to seeing whether a similar attack would come on in the fourth or fifth week after the last, as had occurred on three previous occasions. But the child was quite well, and on Feb. 24, the day of her discharge from hospital, she showed no sign of illness, and the swelling is noted by Mr. White as slowly decreasing, as examined *per vaginam*. We took particular pains to have the child's condition reported upon by her mother for a month or two after she left hospital, but she remained quite well, and without any sign of uterine disturbance.

I venture to think that this case is an interesting one from a pathological, clinical, and surgical point of view, and as such deserves to be recorded.

As to the pathology of uterine hæmotocele it is, I believe, a matter still unsettled among gynæcologists, and we cannot enter upon its discussion here. I will only add one point to the above which has a bearing upon this aspect of the case. This child had no evidence of abortive menstruation except the symptoms recorded in the four attacks described, and she has had none since.

As to the clinical aspect of the case the chief interest lies, I think, in the fact that the symptoms were deceptively like those of acute inflammation of the appendix. If such cases as the above were common they would add another to the many difficulties which already surround our diagnosis of that disease. Fortunately they must be exceedingly rare in children. I have been unable to find any other recorded case of the kind affecting a child.

As to the surgical aspect of the case it is chiefly interesting as showing the benefit of exploratory laporatomy, and also how well children bear abdominal operations, if not too prolonged.

XXII.—*A Case of Lipoma of the Broad Ligament.* By Frederick Treves. *Read February* 10, 1893.

A WOMAN æt. 32, a hospital nurse, was admitted into the London Hospital on September 20, 1892. She was tall, pale, and very thin. She looked delicate, but she had never had any specific illness, and during the two years in which she had been actively engaged in nursing, she had never been a day off duty on account of sickness. Beyond being troubled with constipation she had had no abdominal symptoms of any kind. She was perfectly regular. Fourteen days before admission she began to complain of pain in the lower part of the back. This soon became so severe that she was compelled to take to her bed. She had been in bed for a fortnight with this pain in the back before she was admitted into the surgical wards. It was while thus confined that the tumour in the abdomen was discovered. The patient had long been aware of its existence, but as it did not give her the very least inconvenience, she had refrained from drawing attention to it. She stated that the belly began to enlarge eighteen months ago, that the enlargement proceeded very gradually but steadily, so that she had repeatedly to alter her dresses.

The tumour occupied the right side of the abdomen, and had always been limited to that side. It was very clearly seen through the parietes, and appeared to be the size of the adult head. It occupied the right iliac region and reached upwards to the level of the umbilicus, and on the left extended to a little beyond the middle line. It had all the characters of a typical ovarian tumour, but was remarkable by its prominence and the ease with which its outline could be seen through the parietes. It was dull on percussion and had a rounded and very well-defined outline. There was no lobulation. It did not fluctuate and at the same time it did not appear to be wholly solid. It was described in notes taken before the operation as "tense, elastic, and semi-solid." It was moveable. It could not be reached on vaginal examination, but it was readily made out that the uterus moved with the tumour. The loin was resonant. There was no ascites. The thinness and pallor of the patient and the physical characters of the

growth gave rise to suggestions as to the possibility of the tumour being malignant.

I removed it on September 20, through a median incision which had to be extended from the symphysis to the umbilicus before the mass could be delivered. The tumour was found to be a lipoma growing between the layers of the broad ligament. The right ovary and Fallopian tube were stretched over the growth and were displaced towards the median line. The right ovary was in fact to the left of the median line. The peritoneum over the tumour was divided horizontally and the shelling out of the mass proceeded with. It was quite clear of the wall and brim of the pelvis and in this direction was the least adherent. As the region of the ovary and Fallopian tube was approached the attachment of the tumour became more and more close, and it soon became evident that it would be impossible to remove the growth without at the same time excising the ovary and its tube. This was carried out. The Fallopian tube had to be divided close to the uterus, and the distal part of it together with the ovary was removed with the tumour. No adhesions of any kind existed. Besides the ovarian vessels, three small arteries were secured by ligature. The operation was carried out with some difficulty. No drainage-tube was introduced after the cavity left by the tumour had been washed out, the abdominal wound was closed in the usual way.

The patient made an uninterrupted recovery and left the hospital at the end of four weeks.

The tumour when examined after removal proved to be composed wholly of fat. It was fairly well encapsuled at all parts, and was growing between the layers of the broad ligament. It had no structural connection with either the ovary or the Fallopian tube. It appeared to have been entirely limited to the broad ligament, as it did not encroach upon the retro-peritoneal tissue about the wall of the pelvis. Although it had mounted up into the abdomen, it was entirely free from the retro-peritoneal tissue of that cavity. The peritoneum lining the iliac fossa and covering the brim of the pelvis was wholly undisturbed by the operation. The tumour was quite homogeneous on section. It weighed 72 oz. Its greatest circumference was in the vertical direction and measured 26½ inches. Its least circumference was in the horizontal plane and was represented by 21 inches. The specimen is preserved in the London Hospital Museum.

So far as I have been able to ascertain, lipomata of the

broad ligament are exceedingly rare. The marked absence of fat in the subserous tissue of the mesometrium would serve to explain this rarity.

The literature of retro-peritoneal fatty growths is not inconsiderable, but it contains no account of such a growth between the serous layers of the broad ligament.

Terrillon (*Arch. Gén. de Méd.*, t. i, p. 257, 1886) has collected fifteen recorded cases of subperitoneal lipoma, but the tumours all concern the district of the abdomen.

Terrier and Guillemain, in a recent monograph (*Revue de Chirurgie*, No. 9, 1892, p. 747) upon retro-peritoneal lipomata, speak of them as usually arising from the subserous tissue about the posterior wall of the abdomen, and as spreading thence between the layers of the mesentery or mesocolon. They give an account of two cases in which laparotomy was performed, but in each instance no removal of the tumour was attempted. In one of these cases the lipoma appeared to have arisen in the right loin: it extended to the diaphragm, filled the iliac fossa, and entered the pelvis. The authors quote eleven cases of this kind of growth in which removal by operation was effected. In four of these examples a cure followed, viz. cases by Madelung (*Berl. klin. Wochens.*, 1881, p. 75), Péan (*Bull Gén. de Ther.*, 1887, p. 420), Meredith (*Lancet*, 1887, vol. i, p. 881), and Lauwers (*Acad. de Méd. de Belg.*, 1891, p. 311).

Mr. Bland Sutton, in his excellent work on "Surgical Diseases of the Ovaries and Fallopian Tubes," makes no mention of these growths in connection with the broad ligament. In the *Transactions* of the Obstetrical Society, part i, 1892, p. 7, he describes a case in which the mesosalpinx and adjacent parts of the broad ligament were infiltrated with rich granular fat. He shows that this was associated with a dermoid cyst, the capsule of which had ruptured, and the tissues within the cyst, especially the fat, had burrowed along the lines of least resistance and had made their way between the layers of the broad ligament. He alludes to a like case reported by Mr. Doran (*Trans. Path. Soc.*, vol. xli, p. 202). The cysts met with in the broad ligament are common enough, and have been very elaborately described. The solid tumours in this region are certainly uncommon.

The least infrequent appear to be myomatous growths which develop between the layers of the broad ligament, and arise either in the ovarian or round ligament or in the connective tissue of the district.

Sarcomata have been met with in this part. Such a case is described by Dr. Playfair (*Trans. Obst. Soc.*, 1874, vol. xv, p. 217). The tumour filled nearly the whole of the abdomen. The uterus and ovaries were healthy.

Duplay (*Gaz. des Hôp.*, 1880, p. 625) gives an account of a case of cystic sarcoma of the broad ligament. But as no operation was performed and no post-mortem examination made, the diagnosis was founded solely upon clinical bases.

A somewhat peculiar tumour, described as a cyst with enormously thick fibrous walls, has been examined by Boussi (*Bull. Soc. Anat. Paris*, 1878, p. 368). It was the size of an adult head, was discovered post mortem, and arose from the broad ligament of an insane woman aged eighty-five. It was possibly a myoma which had undergone some central softening.

Parona (*Ann. di Obstet.*, 1892, No. 2) gives an account of a lipoma connected with the broad ligament which was the size of a pear. The Fallopian tube was embedded in the growth so that only the fimbriated extremity was visible. From this tumour—which Parona assumes had developed from one of the fimbriæ—a normal ovary was pendent.

Lastly, a short but distinct account of a lipoma of the broad ligament is given by Peyrot (*Bull. Soc. Anat. Paris*, 1875, p. 178). It was discovered post mortem in the body of an old woman. It was about the size of the fist and was kidney-shaped. It was quite moveable, and is indeed described as floating. A small cyst, the size of a lentil, was found near the neck of the uterus; but for this the organs concerned were normal.

This is the only case I have been able to find which is described under the heading of lipoma of the broad ligament.

XXIII.—*A case of Diaphragmatic Hernia, in which Death was caused by Vomiting.* By C. D. B. Hale, M.D., and J. F. Goodhart, M.D., F.R.C.P. *Read February* 10, 1893.

N. P., æt. 49, the subject of a double inguinal hernia, after much exposure and hard work in India, came to England at the end of 1891 on account of ill health. He complained chiefly of waterbrash and acid eructations, with occasional vomiting. He was seen by Sir Joseph Fayrer, who could detect no organic disease. When I first saw the patient, in January, 1892, he was lying in bed, and constantly bringing up mouthfuls of dark-coloured mucus, while about every week or ten days he vomited enormous quantities of fluid of a similar character. He complained of heat and pain at the ensiform cartilage. His bowels were obstinately confined. His diet was at first restricted to milk and rusks, with only temporary relief; he was then given nothing but peptonised milk, and for a whole month vomiting ceased; as, however, it returned as copiously as ever, his stomach was washed out daily with decided benefit for about a fortnight; milk, farinaceous food, and eggs were then given him, but copious vomiting of yeasty-looking, most fœtid fluid immediately resulted. He had been losing flesh throughout his illness, but emaciation now became rapid and extreme. He was seen by Dr. Goodhart (whose description of the post-mortem appearances follows) with me two days before death. Tympanitic resonance posteriorly as high as the middle of the left scapula and retraction of the abdomen were the only abnormal signs observed. He was thought to be dying of cancer of the stomach.

Dr. Peacock, in vol. xiv, *Path. Soc. Trans.*, divides diaphragmatic hernia into two classes: the true, in which a sac formed by the peritoneum or pleura exists; and the false, in which no sac is present. The present case is an instance of the first named. It is remarkable that this patient had enjoyed good health, and had been able to undergo severe hardships without apparent harm until a few months prior to his

death. Some portion of his stomach must have passed through a congenital opening in the diaphragm at an early stage of his illness, and probably the frequent vomiting, aided by the negative pressure within the thorax, which, according to Mr. Morrant Baker (*Path. Soc. Trans.*, vol. xxvii), is a factor in the production of these herniæ, had the effect of finally forcing the whole organ, with some neighbouring structures, into the thorax, where they were found lying after death.

Report of the inspection.—On the removal of the front of the thorax and abdomen nothing remarkable was apparent. The heart and lungs occupied their usual positions, and seemed in all respects normal. But when we next proceeded to determine the position of the stomach it could nowhere be found. A piece of the splenic flexure of the colon was taken up in mistake for it, and on tracing this along it was found to enter the thorax through an aperture between the crura of the diaphragm underneath the liver. A small part of the cardiac end of the stomach was then seen to be in its natural position below the diaphragm, and, following it along, it also disappeared through the diaphragm with the transverse colon. On now making pressure on the viscera in the epigastric region an impulse was communicated to the thorax in front of the spine, pushing up the heart, and showing also in the pleuræ by movements communicated to the lungs. The stomach was enormously dilated ,and lay in the posterior mediastinum across the spine, and a large part of it was free in the bottom of the left pleura; but it seems probable that this was only a recent occurrence, if, indeed, it did not occur in the making of the inspection, for there was no compression of the lung nor signs of inflammatory action, as has generally been the case where the abdominal viscera have been found to occupy such a position as this.

The parts were removed for more careful examination when it was found that the condition was one of the rarer forms of phrenic hernia; that is to say, the hernial contents were enclosed in a distinct sac which lay across the spine immediately above the diaphragm, and the orifice of which extended from the œsophageal opening on the left to the opening of the vena cava on the right; and I should suppose that it is a congenital weakening, and perhaps subsequent bulging, of the midrib between the crura.

The sac contained two thirds of the stomach, and with it a large loop of the transverse colon, the lesser omentum, the greater part of the pancreas, and the duodenum. The stomach

was twisted somewhat, so that the omental fat got upwards, and the posterior wall, towards the pyloric end, was forwards. The pyloric orifice was within the sac, and was unusually thin. The stomach itself was thick.

The viscera except for the displacement were normal. The pancreas was elongated from stretching.

XXIV.—*Two cases of Generalised Vaccinia.* By T. Colcott Fox, M.B. *Read February* 10, 1893.

CASE I.—William N. was born in a lying-in hospital on May 21, 1892, and on the 25th of that month was vaccinated, with a number of other infants, from a baby selected at the National Vaccine Establishment in Lamb's Conduit Street. In William N. only did anything unusual occur. The mother was discharged from the hospital at her own request on June 2, and on that day her infant was examined in the usual course by the authorities at the hospital, and the vaccination had apparently run a normal course. The mother, however, states that at this time a very small vesicle was present on the scalp. From this date, the ninth day after vaccination onwards, lesions appeared day by day. On the 8th June, *i. e.* on the fifteenth day, the baby came under my observation at the Westminster Hospital, and then the vaccinated arm was swollen, reddened, covered with a dense aggregation of varioliform vesicles rather smaller than perfect vaccine vesicles, surrounding the primary lesions. Other typical vaccine vesicles, perhaps thirty or forty, were disseminated sparsely and far apart over the trunk (back and front), the limbs, and especially the scalp. The child did not appear to be very ill, only peevish and fretful: the skin temperature was 99·4° F. On June 12, the nineteenth day, the vaccinated arm was completely covered with a crust, and a few additional lesions had developed on the trunk and limbs. The mother pointed to a small *pustule* recently evolved, and remarked that the later lesions did not attain the size of the earlier ones. On June 15, *i. e.* on the twenty-second day, the eruption was subsiding rapidly, but Dr. Gossage, the house physician (to whom I am indebted for careful observation of the case), noticed the evolution of a few abortive *pustules* for a few days longer. These later small lesions attained the pustular stage very rapidly, and were not characteristic of vaccinia. The earlier typical vaccine vesicles tended to leave scars, though very slight ones.

On the brother's scalp was an irregularly-rounded large pus bulla, characteristic of those seen in Pediculosis capitis, and unlike a vaccine vesicle.

Case II.—Alice G., born on the 13th July, was kindly sent to me by Dr. W. C. Grigg on August 4, 1892. The baby was vaccinated with humanised lymph in four places on the left arm, on July 20. The vaccination took well, and ran a normal course. On July 26, the baby was examined and nothing unusual was apparent. On the 28th, the ninth day, supplementary lesions were noticed by the mother to be making their appearance. On the 30th, the vaccinated arm was covered with them, and others had appeared elsewhere. When I saw the baby on August 4, the sixteenth day, I noted some miliary dome-shaped pustules, without any solid base or areola, on the scalp. On the right forehead was a larger pustule, with a red areola. On the outer side of the right arm was a larger, perfectly rounded, umbilicated lesion, quite typical of a vaccine vesicle, but not quite full size. A perfect, fully-developed vaccine lesion was present on the inner side of the left arm, on the right ring finger with a brown colour, on the flexor aspect of the left wrist, on the chest; two or three on the lower part of the back, two on the right shoulder and middle back, three on the inside of the right foot and ankle, two on the left calf. On the vaccinated arm the dried-up primary lesions were surrounded by a great multitude of confluent vaccine vesicles, still preserving their individual outlines. The confluent lesions in this situation were, according to the mother, the first of the secondary ones to appear. The temperature was normal, but the mother asserted that the child had been feverish, and very restless. After this date a few abortive miliary pustules appeared for a few days, and the earlier lesions all ran a natural course of involution. They turned brown in the centre, then became discoloured all over, dried up into scabs, and finally separated, leaving a red tache or in some places a faint scar. Sixteen other babies were vaccinated from the some source as Alice G.: all the sixteen took in four places, and all did well.

We have here again a similar sequence of events to that seen in Case I. The primary vaccination ran a normal course till about the ninth day, when the site of the primary vaccination became surrounded by a multitude of confluent secondary vaccine lesions. These were quickly followed by a

few others distributed singly and in twos and threes over the general surface, which was sound and unbroken. Fresh lesions continued to evolve for two or three days, and then for some days longer a few miliary abortive pustules, until about the eighteenth day in the second case, and the twenty-fifth day in the first case.

I may add that I exhibited the first case to the Dermatological Society, and, as the drawings I hand round show, there can be no doubt as to the character of the lesions.

Remarks.—A good many similar cases have been noted, and a slight reference is made to them in some of the treatises dealing with vaccination, such as those by Warlomont and Parola, but the more complete discussion will be found in a Thèse pour le Doctorat en Médecine, sustained by Dauchez at Paris in 1883, entitled, *Des Eruptions Vaccinides Généralisées (Vaccinides) et de quelques dermatoses suscitées ou rappetés par la Vaccination,* and in the article by Longet published in 1886 in the *Dictionnaire Encylopédique des Sciences médicales.* I append* also a few references bearing on the subject and not noticed by these authors. In this country such an eruption has attracted very little attention, and the only case coming within my own experience previously was a child under the care of Dr. D. B. Lees. Judging by the amount of literature existent the condition does not appear to be at all common; nevertheless I doubt its great rarity. Both Dauchez and Longet are careful to separate these eruptions of supplementary true vaccine vesicles from other eruptions following vaccination, and they further draw a distinction between a generalised vaccinia appearing concurrently with the local primary vaccine vesicles, and believed to be of spontaneous origin, and secondary lesions appearing at a later date (but whilst the system is still susceptible to vaccine inoculation), and believed to be due to auto-inoculation. Most writers are in agreement with them, though it is often difficult, if not impossible, to say into which category a given eruption should be placed. Dauchez admits that in exceptional cases the supposed true spontaneous generalised vaccinia may be tardy in appearance, and that the course of events may approximate to that seen in inoculated variola. It has been

* *Lyon Méd.*, 1889, August 18 (Lacour); *Ann. de Derm. et de Syph.*, 1891, January 8 (Gaucher); *I. Cut. and Gen.-Urin. Dis.*, vol. i, 1883 (Smith); *Med. Record*, April 15, 1882 (Martin); *I. Cut. and Gen.-Urin. Dis.*, vol. i, March, 1883 (Morrow); *Brit. Med. Journ.*, December 13, 1890, p. 1362 (Darling), accidentally inoculated from a cow; *Traité pratique de la Vaccination animale*, 1889, pl. xx (Layet).

shown that auto-inoculation may occur from the eighth to the eighteenth day or even later, but that it is very rare beyond the ninth day after the primary vaccination.* It is usual to find the later lesions more rapid in evolution and maturation, and less typical in form.

In many of these cases of generalised vaccinia the vesicles developed exclusively or more copiously on eczematous or inflamed surfaces. This may be explained by supposing that auto-inoculation occurs more readily on such surfaces, or that an eczematous area is a *locus minoris resistentiæ*, as seen in variola. Thus in Padieu's case 200 vaccine lesions developed on an eczematous face and scalp on the fourth day after vaccination, *i. e.* contemporaneously with the primary vaccination lesions. In somewhat similar cases the early appearance of the supplementary lesions, the probable absence of such an agency as rubbing and scratching to be inferred from the tender age of the infant, and the condition of the vaccination lesions, or the site of some lesions, or the protection by dressing of an inflamed part on which supplementary lesions arise, render an explanation by auto-inoculation somewhat unsatisfactory. If auto-inoculation be the explanation, then vaccine matter must have been conveyed either at the time of the operation, or shortly afterwards in washing or otherwise tending the infant. On the other hand, Martin's case appears to illustrate the remarkable manner in which inoculation can occur.† He vaccinated a mother with bovine lymph and on the sixteenth day her unvaccinated infant, seven months old, commenced to exhibit lesions, so that eventually at least 400 typical vesicles might be counted. A heifer was successfully vaccinated from them. In cases where the supplementary vesicles arise at a later period the course of events may approximate very closely to that seen in inoculated variola in man, except that the latter is infectious. My cases illustrate this point. Other symptoms do not afford us great help. Fever may be present, often to a considerable degree, but nothing distinctive in the character or course of the febrile symptoms is of service in elucidating the point. Perhaps this fact rather tells for the auto-inoculation theory, as does the constant freedom of mucous membranes from attack. On the

* Layet, from experiments, determined that in infants immunity was, as a rule, established after the completion of the seventh day, in adults one day later. Some latitude must be allowed in accordance with the varying rate of evolution of the pustules.

† Dr. Theodore Acland has pointed out to me that the infant might possibly have contracted vaccinia through the mother's milk.

other hand, there are several circumstances which make a spontaneous generalised vaccinia appear possible. Thus Chauveau found that by introducing vaccine matter into the lymphatics, veins, subcutaneous tissue, digestive tract, or trachea, a generalised eruption on the skin was produced, and the contents of the vesicles were capable of vaccination in cows and infants with the ordinary results of vaccine inoculation. Cazalas administered a pinch of powdered vaccination crusts in soup to a child of four years, who appeared to be insusceptible by the ordinary methods. On the fourth day general symptoms, *e. g.* nausea, vomiting, violent fever, declared themselves, and at the end of six days a general eruption of 180 vaccine lesions appeared. Pritchard and Etienne have recorded cases in which multiple disseminated lesions evolved, and apparently spontaneously, in a child who had sucked a vaccine vesicle. There is also a remarkable case, quoted by Longet, in which a generalised vaccinia evolved, though no results were produced at the site of the primary vaccination.

Lastly, I may refer to the well-known fact that many successful inoculation experiments with variolous matter in cows confirmed Jenner's belief that the cow-pox of the cow and the smallpox of the human subject were essentially the same disease.* This view, temporarily upset by Chauveau, has lately been resuscitated.† If, therefore, vaccinia is a form of smallpox modified and rendered non-infectious by transmission through the cow, it is not unlikely that a generalised non-infectious eruption of vaccinia may occasionally occur in specially susceptible subjects.

From these considerations, and after a careful survey of all the recorded cases, I find a difficulty in reaching any very definite conclusion as to causation of the two cases I now recite, *i. e.* in deciding for or against auto-inoculation. I must confess, however, that I am strongly impressed with the analogy between such cases and inoculated variola. Some cases of generalised vaccinia no doubt arise from auto-inoculation, and it is difficult to exclude positively the operation of this cause in perhaps the majority of the recorded cases. On

* Seaton's article in Reynold's *System of Medicine.*

† Simpson, reported *Pract.*, July, 1892; Hine, *Brit. Med. Journ.*, 1892; King, reported *Brit. Med. Journ.*, 1892, p. 1191; *Variolo-Vaccine: Contribution à l'Étude des Rapports qui existent entre la Variole et la Vaccine*, par Ch. Haccine, avec notes originales de MM. les Docteurs Voigt, Fischer, et Hime (Bradford), Geneva and Paris, 1892.

the other hand, the occurrence of so-called spontaneous generalised vaccinia is, as I have pointed out, extremely probable. It is to elicit the experience of this Society that I have ventured to bring forward the two cases, which are, I think, not without interest.

XXV.—*A case of Generalised Vaccinia.* By T. D. Acland, M.D., and C. H. Fisher, M.D. *Read February* 10, 1893.

Vaccination with humanised lymph forty-second remove from the calf. Confluent eruption round the points of inoculation by fourteenth day. Secondary eruption over trunk and extremities. Pocks continuing to appear until the sixth week after vaccination. Death on forty-ninth day. Inoculation of mother's breast.

H. J. was vaccinated when three months old with humanised lymph stored in tubes. The vaccination was performed with every care by a vaccinator of long experience. The child had previously been in good health, and was free from any eruption on the skin. The lymph was obtained from a typically healthy child in the north of England, whose vaccination, which was normal and without complication, was the forty-first remove from the calf. In five whole generations of vaccinees, besides two other individual cases in the direct line, nothing unusual was found in the course pursued by vaccination, with the exception that in one case, the fourth remove from the subject of this report, and the forty-sixth from the calf, numerous supplementary vesicles formed round the points of inoculation.

In three of the six co-vaccinees no result followed vaccination, whilst in three vaccination was normal and without complication.

In the case of the child under consideration, nothing was noted amiss on the eighth day, and three children were successfully vaccinated with lymph taken from its arm. Vaccination in all three cases was without complication. On the fourteenth day, when Dr. Fisher again saw the child, the four vesicles had coalesced and were covered with a scab, while innumerable small pocks had formed round the points of inoculation. These secondary vesicles soon became pustular, and the scab that had formed over the four vaccination wounds which had coalesced came away, leaving a large open sore.

DESCRIPTION OF PLATE II,

To illustrate Drs. Acland and Fisher's Case of Generalised Vaccinia.

The figures were drawn on the forty-third day after vaccination The pocks on the cheeks, lips, and forearm were about fourteen days old, that above the left eyebrow about fifty-six hours.

The sore on the upper arm measured $4 \times 4\frac{1}{2}$ inches. The isolated pocks measured $\frac{1}{8}$ to $1\frac{1}{2}$ inches in diameter.

.pinxt

Danielsson & Co., lith.

Scattered pocks commenced to form on the back of the head, face, lips, arms, legs, and trunk; there were in all twenty-eight on the forty-third day, varying from one sixth inch to four inches in diameter, the latter being at the seat of vaccination. These pocks commenced as minute shotty papules rapidly becoming vesicular, spreading apparently by peripheral extension, and in some cases coalescing. When fully developed they closely resembled mature vaccination pocks, with semi-translucent ivory-yellow margin and a small central depressed scab.

At the seat of the original confluent eruption and in two other places where the pocks had been rubbed by the clothes, one on the thigh, and the other on the abdomen, shallow central ulcers formed, which were covered with a thin layer of healthy pus, and surrounded by a raised margin similar in appearance to that of the smaller pocks.

The eruption continued to make its appearance over a period of nearly five weeks, the last pock which formed having been first noticed forty-two days after vaccination.

During the course of the child's illness Dr. Fisher did not note any pyrexia. The axillary glands were not inflamed or indurated.

Up to the seventh week the child, although irritable and feeble, seemed to be doing fairly well, though it suffered much from restlessness and sleeplessness, which, notwithstanding all treatment, increased, and the child died exhausted on the forty-ninth day after vaccination.

It was not found possible to make a post-mortem examination.

The mother, who had not been re-vaccinated, suckled the child, and a pock formed on one of her breasts, which ran through the ordinary stages of a vaccination vesicle. It was not followed by any complication or constitutional disturbance.

The previous family histories throw no light on the case. There is no evidence to show that the child had been exposed to the infection of varicella, variola or any other contagious disease.

Dr. Fisher has known the parents for thirteen years, and does not even suspect the presence of any syphilitic taint, and not one of the six vaccinifers in the direct line who have been examined shows any evidence of congenital or inoculated syphilis.

The clinical history and the appearance of the eruption lead to the conclusion that the case is an unusual one of

Scattered pocks commenced to form on the back of the head, face, lips, arms, legs, and trunk; there were in all twenty-eight on the forty-third day, varying from one sixth inch to four inches in diameter, the latter being at the seat of vaccination. These pocks commenced as minute shotty papules rapidly becoming vesicular, spreading apparently by peripheral extension, and in some cases coalescing. When fully developed they closely resembled mature vaccination pocks, with semi-translucent ivory-yellow margin and a small central depressed scab.

At the seat of the original confluent eruption and in two other places where the pocks had been rubbed by the clothes, one on the thigh, and the other on the abdomen, shallow central ulcers formed, which were covered with a thin layer of healthy pus, and surrounded by a raised margin similar in appearance to that of the smaller pocks.

The eruption continued to make its appearance over a period of nearly five weeks, the last pock which formed having been first noticed forty-two days after vaccination.

During the course of the child's illness Dr. Fisher did not note any pyrexia. The axillary glands were not inflamed or indurated.

Up to the seventh week the child, although irritable and feeble, seemed to be doing fairly well, though it suffered much from restlessness and sleeplessness, which, notwithstanding all treatment, increased, and the child died exhausted on the forty-ninth day after vaccination.

It was not found possible to make a post-mortem examination.

The mother, who had not been re-vaccinated, suckled the child, and a pock formed on one of her breasts, which ran through the ordinary stages of a vaccination vesicle. It was not followed by any complication or constitutional disturbance.

The previous family histories throw no light on the case. There is no evidence to show that the child had been exposed to the infection of varicella, variola or any other contagious disease.

Dr. Fisher has known the parents for thirteen years, and does not even suspect the presence of any syphilitic taint, and not one of the six vaccinifers in the direct line who have been examined shows any evidence of congenital or inoculated syphilis.

The clinical history and the appearance of the eruption lead to the conclusion that the case is an unusual one of

Scattered pocks commenced to form on the back of the head, face, lips, arms, legs, and trunk; there were in all twenty-eight on the forty-third day, varying from one sixth inch to four inches in diameter, the latter being at the seat of vaccination. These pocks commenced as minute shotty papules rapidly becoming vesicular, spreading apparently by peripheral extension, and in some cases coalescing. When fully developed they closely resembled mature vaccination pocks, with semi-translucent ivory-yellow margin and a small central depressed scab.

At the seat of the original confluent eruption and in two other places where the pocks had been rubbed by the clothes, one on the thigh, and the other on the abdomen, shallow central ulcers formed, which were covered with a thin layer of healthy pus, and surrounded by a raised margin similar in appearance to that of the smaller pocks.

The eruption continued to make its appearance over a period of nearly five weeks, the last pock which formed having been first noticed forty-two days after vaccination.

During the course of the child's illness Dr. Fisher did not note any pyrexia. The axillary glands were not inflamed or indurated.

Up to the seventh week the child, although irritable and feeble, seemed to be doing fairly well, though it suffered much from restlessness and sleeplessness, which, notwithstanding all treatment, increased, and the child died exhausted on the forty-ninth day after vaccination.

It was not found possible to make a post-mortem examination.

The mother, who had not been re-vaccinated, suckled the child, and a pock formed on one of her breasts, which ran through the ordinary stages of a vaccination vesicle. It was not followed by any complication or constitutional disturbance.

The previous family histories throw no light on the case. There is no evidence to show that the child had been exposed to the infection of varicella, variola or any other contagious disease.

Dr. Fisher has known the parents for thirteen years, and does not even suspect the presence of any syphilitic taint, and not one of the six vaccinifers in the direct line who have been examined shows any evidence of congenital or inoculated syphilis.

The clinical history and the appearance of the eruption lead to the conclusion that the case is an unusual one of

Scattered pocks commenced to form on the back of the head, face, lips, arms, legs, and trunk; there were in all twenty-eight on the forty-third day, varying from one sixth inch to four inches in diameter, the latter being at the seat of vaccination. These pocks commenced as minute shotty papules rapidly becoming vesicular, spreading apparently by peripheral extension, and in some cases coalescing. When fully developed they closely resembled mature vaccination pocks, with semi-translucent ivory-yellow margin and a small central depressed scab.

At the seat of the original confluent eruption and in two other places where the pocks had been rubbed by the clothes, one on the thigh, and the other on the abdomen, shallow central ulcers formed, which were covered with a thin layer of healthy pus, and surrounded by a raised margin similar in appearance to that of the smaller pocks.

The eruption continued to make its appearance over a period of nearly five weeks, the last pock which formed having been first noticed forty-two days after vaccination.

During the course of the child's illness Dr. Fisher did not note any pyrexia. The axillary glands were not inflamed or indurated.

Up to the seventh week the child, although irritable and feeble, seemed to be doing fairly well, though it suffered much from restlessness and sleeplessness, which, notwithstanding all treatment, increased, and the child died exhausted on the forty-ninth day after vaccination.

It was not found possible to make a post-mortem examination.

The mother, who had not been re-vaccinated, suckled the child, and a pock formed on one of her breasts, which ran through the ordinary stages of a vaccination vesicle. It was not followed by any complication or constitutional disturbance.

The previous family histories throw no light on the case. There is no evidence to show that the child had been exposed to the infection of varicella, variola or any other contagious disease.

Dr. Fisher has known the parents for thirteen years, and does not even suspect the presence of any syphilitic taint, and not one of the six vaccinifers in the direct line who have been examined shows any evidence of congenital or inoculated syphilis.

The clinical history and the appearance of the eruption lead to the conclusion that the case is an unusual one of

months it was found that there was but little movement in the hip-joint, but what movement there was was unaccompanied by any pain. The boy was able to walk and run with only the inconvenience consequent upon the limited flexion which the new joint permitted. The case was admitted under my care into Guy's Hospital, and was diagnosed as one of fracture through the epiphysial line, with the formation of an amphiarthrodial joint between the neck of the femur and the anterior inferior spine, the head having united with the lower and back part of the stump of the neck. The thigh was rotated outwards beyond the position of rest. There the general characters of this fracture were marked, the presence of which is, I believe, frequently overlooked in the young subject. That this is an advantage to the patient is very obvious, since such cases do remarkably well, and the fragments unite with a minimum of shortening if the patients are left at rest on their backs, since the resistance offered by the front of the capsule, and possibly to some extent by the rectus tendon, oppose the ascent of the femur and retain it in contact with the bone below the anterior inferior spine.

As the patient was most anxious that an attempt should be made to restore to the joint its original freedom of movement I explored it, and found that the condition was as diagnosed, the head of the femur having become attached to the lower and back part of the neck, and taking apparently but little share in the transmission of superjacent weight. As there was obviously nothing to be done the wound was closed.

The second case, a lad, G. C., æt. 9, was under my care in the Hospital for Sick Children. In his case the rotation of the femur outwards had not been so complete as in the last case, and there was but slight displacement of the lower fragment; the stump of the neck had united to the upper and anterior part of the head.

I have seen other similar cases, where the resulting good union was owing to the non-recognition of the fracture by the surgeon.

The following case illustrates very well the relative merits of an articulation on the dorsum ilii, and an articulation beneath the anterior inferior spine.

P. C., a boy nine years of age, was admitted into the Hospital for Sick Children under my care in September, 1892,

with ankylosis of the left temporo-maxillary articulation and a dorsal dislocation of the right hip, the latter joint being very loose and insecure, and during locomotion there was very great lordosis and deformity of the trunk. When the child occupied the supine position the right leg was found to be two inches shorter than the left, and when the erect posture was assumed the length of the left leg exceeded that of the right by three inches.

The dislocation resulted from a fall received three years before, and the ankylosis of the jaw was observed for the first time six months after the fall. I excised the head and neck of the jaw on the left side, and found that the joint had been completely ankylosed by a depressed fracture of the zygoma, a traumatic arthritis having been set up.

The head of the femur could be reduced into the acetabulum by flexing and adducting the thigh, but on diminishing the flexion of the hip-joint to any extent the head glided out of the cavity.

I therefore first divided subcutaneously as much of the adductor muscles as I could at their pubic attachment, and then, making a couple of incisions over the outer part of the joint, cut through the tensor vaginæ femoris, the greater part of the glutei muscles, the psoas and iliacus at their attachments to the lesser trochanter, together with the muscles inserted into the upper part of the linea aspera. After dividing the capsule I was then able to feel the head of the bone, which was very much increased in breadth, so as to be mushroom-shaped. It articulated with a smooth surface on the dorsum ilii, which had no defined limit above, but below was continuous with the acetabular cavity (see Fig. 1). It was obvious that upward displacement of the head of the femur was only opposed by the anterior part of the capsule of the joint.

I forcibly rotated the shaft of the bone outwards till the head and neck projected forwards and inwards, instead of backwards and inwards as before.

A cavity was then cut with a gouge beneath the anterior inferior spine and the rectus tendon, and the large mushroom-shaped head of the bone was shaved down to about one third of its bulk, till it fitted comfortably in the depression made in the innominate bone (see Fig. 2). A silk suture was passed through the two portions of the anterior part of the capsule, which were cut to a proper length, and through the rectus tendon, in order to retain the head in its place. The leg was

put up in a Thomas's splint in such a position of rotation that the inner margin of the foot formed with the vertical an angle of 45°. A very firm arthrodial joint developed, and

Fig. 1.

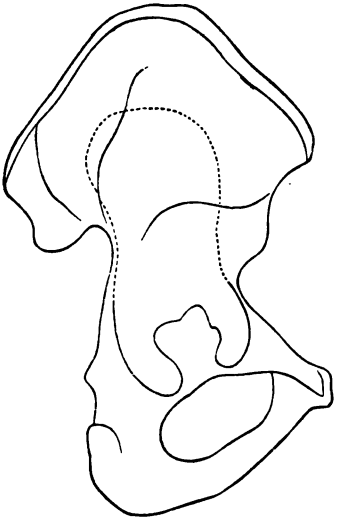

Fig. 2.

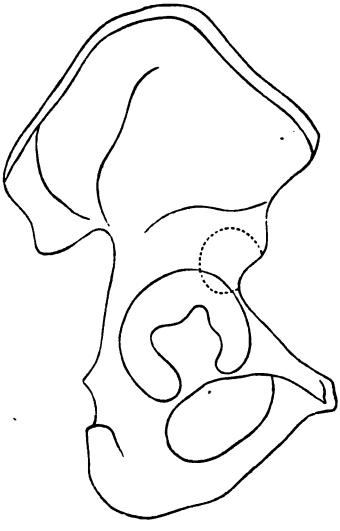

allowed of very considerable flexion, extension, and abduction, the movement of abduction being least marked. There was no movement whatever in a vertical plane; there was no lordosis, and the shortening only amounted to 1 inch. Weight was transmitted perfectly and securely through the newly-formed joint.

I could illustrate by numbers of other cases the several points I have indicated briefly in this paper, but I feel that those which I have described are sufficient for my purpose.

XXVII.—*Sequel to a case of Excision of the Head of the Femur and Erasion of the Hip-joint through the anterior incision, and with immediate and permanent closure of the wound.** By Charles Barrett Lockwood. *Read February* 24, 1893.

On January 24, 1890, I showed a child whose hip-joint had been excised by the anterior incision, with subsequent repair of the wound under a single dressing. It was then said that the pathology of the case was not clear, and that without further evidence I was indisposed to attribute it to tuberculosis. The sequel of the case has, however, removed my doubts upon this point. The original operation was performed on March 13, 1889, and resulted in a freely moveable and very useful hip-joint. All the usual movements could be performed with facility, and the child walked easily and rapidly without any apparatus, without even a walking stick. He limped, however, and might be considered to have been about in the condition of a child with a slight congenital absence of the margin of the acetabulum, with some displacement of the head of the femur. Indeed, when he stood upon the leg there was from $\frac{1}{2}$ to $\frac{3}{4}$ of an inch of shortening, but this disappeared when he lay down. After living happily and attending school for more than two years he was attacked with influenza, which was followed by acute general tuberculosis, of which he died on July 12, 1891; two years and three months after the operation.

The hip-joint was obtained, and has been dissected.† The specimen fully explains the success of the operation. At first glance it might be supposed that the head of the femur was still in existence, inasmuch as the end of the neck is quite smooth, rounded, and shining like an articular surface. The interior of the acetabulum, too, is smooth, and its upper part united to the neck of the femur by strong fibrous bands. Thus the femur and acetabulum were admirably adapted for movement in any direction, and as they were both enclosed in a very strong and firm fibrous capsule the small amount of

* *Clin. Soc. Trans.*, vol. xxiii, p. 98.

† The specimen is in the Museum of St. Bartholomew's Hospital.

displacement is fully explained. But although the condition of the joint is so satisfactory there is a small focus of caseous material upon the inner aspect of the ischium, just behind the hip-joint. This was, perhaps, the original focus of disease, and explains both the arthritis, for which the operation was performed, and the subsequent attack of acute general tuberculosis.

This is the first time that a specimen has been shown to exemplify the morbid anatomy of a hip-joint which has been treated by excision of the head of the femur with immediate and permanent closure of the wound, and I venture to submit that the result is satisfactory and encouraging.

XXVIII.—*A note on the prognosis in cases of Sacro-iliac Disease.* By G. H. Makins. *Read March* 3, 1893.

NOTWITHSTANDING the interest which of late years has centred in cases of tubercular disease of the joints, and the large amount of recent literature that has accumulated on the subject, little has been written on the sacro-iliac articulation, and the same sombre records still continue to occupy their place in the text-books of surgery as to the prognosis in disease of this joint.

This is no doubt the result of the comparative rarity of the disease, and this has led me to bring before the notice of the Society a short account of three cases which have been under my treatment during the past five years, one in the wards of St. Thomas's Hospital and two in the Evelina Hospital for Sick Children.

The first point to be noted in these cases is that two were children under five years of age, and the authorities generally state that the disease is rare in childhood. With the view of testing this general opinion I have looked through the surgical records of St. Thomas's Hospital for the ten years between 1881—1890 inclusive. I find thirteen cases of the disease, the ages ranging as follows:

-5	5-10	10-20	20-30	30-40	40-50	50-60	+60	Adult.
*0	2	4	4	1	2	0	0	
†0	7	7	18	7	5	0	1	12
	9	11	22	8	7	0	1	
	12·6 %	15·49 %	30·98 %	11·2 %	9·8 %		1·4 %	16·9 %

* St. Thomas's cases. † Dr. Poore's cases.

Mr. Barker,* in thirteen cases collected from the records of University College Hospital, found the ages to vary between fifteen and fifty-two, with an average of twenty-seven.

These collations, however, contain cases of every kind of joint affection, particularly gonorrhœal, puerperal, and pyæmic, mostly diseases of adult age, so that the probabilities are in favour of an even larger average percentage of cases of tubercular disease in childhood.

As to the rarity of the disease, in the same decade at St. Thomas's Hospital I find 1622 cases of joint disease of all kinds were under treatment as in-patients, the distribution being as follows:

Sacro-iliac	13
Hip	660
Knee	593
Ankle	127
Tarsus	58
Shoulder	37
Elbow	102
Wrist	32
	1622

Thus the relative frequency of sacro-iliac disease to that of all other joints appears as 8 per cent.

This, however, bears no actual relation to the whole number of cases of joint disease treated at the hospital, since the large number treated as out-patients is not included.

Mr. Barker's† thirteen cases were also the whole number met with at University College Hospital in the same period of time, and Mr. Marsh‡ states that only three or four were met with among 1000 cases applying for treatment at the Alexandra Hospital for diseases of the hip.

All three of the cases under consideration were males, but numbers seem to show that the disease occurs fairly evenly in either sex. Thus:

		M.	F.
Mr. Barker	13 cases	5	8
St. Thomas's	13 „	6	7
Poore	57 „	30	27
Total	83	41	42

It must be borne in mind, however, that these statistics include diseases of all kinds; the puerperal cases alone may

* *Holmes' System*, vol. ii, p. 397. † Loc. cit.
‡ *Diseases of Joints*, p. 361.

make a considerable difference, and hence tubercular cases may be more common in males.

I have made a short *résumé* of the prognosis assigned to this disease in the various text-books.

Mr. Erichsen* says, "The prognosis is *always* most unfavorable. I am not prepared to say that it is of necessity fatal, but I have never seen a patient recover after the full development of the disease, and after suppuration has set in." Two cases of recovery are, however, quoted (Sir B. Brodie and Mr. Golding-Bird).

Mr. Gant† says, "The course is most unfavorable, the termination being nearly always fatal" (Sir B. Brodie's case also quoted).

Nélaton‡ gives a better prognosis. He says, "Happily the disease has not always so funest a termination; it sometimes heals, leaving little trace, at other times leaving deformity or anchylosis."

Professor Hahn,§ in a paper on the subject, styles the affection a "fatal disease."

Mr. Barker‖ says, "Recoveries are in the long run rare, so far as we know."

Mr. Marsh¶ says, "If the diagnosis is made early, and rest is at once secured, the disease will undoubtedly subside, and recovery will ensue; but when caries of the bones has taken place the disease has entered a very intractable stage: with rest and free drainage recovery may still ensue, but the probability is against this."

Mr. Moullin** says, "The prognosis is always unfavorable, but so long as caseation does not occur it is by no means hopeless. A large amount of bone may be removed by fungating caries, and cicatrisation follow, leaving even a certain degree of deformity, without of necessity suppuration ever taking place. If, however, caseation and liquefaction do make their appearance, the prospect of recovery is more than doubtful. In only one case (Hilton's) is recovery known to have taken place without operation after suppuration had occurred."

Mr. Warrington Haward†† also expresses a bad prognosis.

* Erichsen, 9th ed., vol. ii, p. 456.
† Gant, *Science and Practice of Surgery*, vol. ii, 2nd ed., p. 825.
‡ Nélaton, *Pathologie chirurgicale*, vol. ii, 2nd ed., p. 813.
§ *Allg. medin. Zeitung*, Oct., 1883.
‖ *Holmes' System*, vol. ii, p. 398.
¶ *Diseases of Joints*, p. 366.
** Moullin, *Surgery*, p. 678.
†† *Heath's Dictionary*, vol. ii.

Treatment.—As to the result of treatment, again the authorities hold out small prospect of advantage. Until the eighth edition of *Erichsen's Surgery* the dictum "No operative treatment is admissible" appeared; in the ninth edition a case of trephining of the joint by Mr. Golding-Bird is quoted.

Mr. Gant says, "Removal of the diseased articular surfaces by excision is of course out of the question."

Hueter,* in his work on the joints, recommends incision and scraping, but not, however, in very warm terms. He says, "Still such operations are well borne, and if they lead to little good in some cases, yet they do no harm."

Mr. Marsh† recommends rest and the actual cautery in the early stages; in the later stages, when caries is established, he says, "Nor can any operative treatment be depended on to do material good generally, although the surgeon is induced to operate frequently; and although on each occasion he removes carious fragments, he fails to secure repair. *Synovial cases,* treated by gouging and laying open of sinuses, may heal soundly." (One case, in a female æt. 32, is quoted as so treated by himself, and she was able to return to her household work in four months.)

Dr. Poore‡ says the question of removal of bone has been queried, but it should be done; and Mr. Moullin§ recommends scraping, &c., but says it should not be done if there is evidence of phthisis or tubercular disease elsewhere.

I will now advert to the special features of the cases I relate, in so far as the prognosis is affected by them.

It is noteworthy that two cases in such a small number occurred in children, and this I think must be regarded as a favorable prognostic point, since in the case of all other joints we know treatment of the nature adopted is likely to give good results. Again, in the case of this joint especially, the light weight of the trunk must be a matter of the first importance in obtaining a permanent result.

As to the origin of the disease, in all three the bones were the parts primarily affected; and this I think is likely to be usually the case when the limited extent of the synovial cavity is borne in mind. In two of the cases the mischief consisted in ostitis and caries, both sacrum and ilium being affected. In No. 3 distinct sequestra were removed from the ilium, and

* *Klinik der Gelenk Krankheiten,* Auf. ii, p. 17.
† Loc. cit., p. 360.
‡ *American Journ. of the Med. Sciences.*
§ Loc. cit., p. 678.

the sacrum was unaffected; this child was also the subject of cervical caries.

As to the stage of the disease, in all three suppuration had occurred. In the adult case, however, there was no abscess at the time of operation, and this no doubt contributed to the success of the treatment. In both the other cases abscesses were present, and the removed granulations were caseating; but here an important point is to be noted; both the abscesses presented externally, and neither burrowed deeply into the pelvis. It is generally considered that for the abscess to point at the posterior aspect is unfavorable in so far that it indicates more or less destruction of an important bond of union—that afforded by the strong posterior ligaments. On the other hand, however, such abscesses are less intricate and more readily thoroughly healed by erasion than those extending into the pelvis; and hence this must, I think, be considered an all-important point in the probable success of an arthrectomy or an arthrotomy with erasion of this articulation. As to the weakening due to destruction of the posterior ligaments, this is of comparatively little moment, as a cure here is probably only to be effected by firm anchylosis. The result obtained in these cases is supported by the experience gained in Trendelenburg's operation for ectopion vesicæ, where the division of the posterior and inter-osseous ligaments in children does not seem to have been followed by any marked weakness in maintaining the erect position.

In the adult case the progress of healing was slow, extending over a period of ten months, and was unfortunately complicated by an anchylosis of the hip, which I was unwilling to meddle with, since he could walk fairly, and any attempt at forcible treatment might have resulted in injury to the healed sacro-iliac joint.

Case No. 2 left with a discharging sinus, and I have been unable to trace him, but he walked well.

Case 3 I have had under constant observation, and the joint is still healed and sound. The cervical caries is apparently quiescent, or at any rate not progressing rapidly.

With regard to the method of treatment adopted, I have little to say as to the two children; it differed in no way from that usually adopted in the case of other articulations affected by tubercular disease. In the case of the adult I adopted the method which has been described by Mr. Mayo Collier, and I believe performed by Mr. Golding-Bird and other surgeons. Its advantages are sufficiently obvious, since it

leaves the ligamentous structures of the joint practically untouched, while free access is afforded to the cavity of the articulation.

The sole object of the present communication is to render prominent the fact that the prognosis—perhaps particularly in children—is better than is generally stated, and to urge that the treatment of disease of this articulation should run on exactly the same lines as does that of disease of the joints in general, since cures may undoubtedly be effected, even when the disease has reached a fairly advanced stage.

Case 1.—William M., æt. 25, carpenter. Always had good health until six years ago. No evidence in family history of tubercular diathesis.

Six years ago an abscess formed spontaneously over the dorsum ilii. He was then under treatment at the Sussex County Hospital, and left cured. Subsequently he returned to work, and was well until nine months ago, when he was seized with severe pain in the right hip, accompanied with weakness, and he has since been unable to work.

On admission, July 18, 1888.—Complains of pain in right hip, and shooting up thigh from knee in line of sciatic nerve. Can only turn in bed with great difficulty.

A large scar exists over the ilium just external to the right sacro-iliac joint. Pain is caused by pressure on trochanter, or on compression of the iliac crests. The right anterior superior spine is raised and tilted somewhat forwards, causing an apparent hollowing in the groin; the hip is slightly flexed and adducted, giving rise to lordosis when the patient lies on his back. There is no difference in measurement between the two limbs. Careful movement of the hip causes no pain. The limb is considerably wasted, the girth of the right thigh measuring one inch less than the left. There is impulse on coughing over both the sciatic notches, and this is especially well marked on the right side. Rectal examination reveals no fulness within the pelvis. The patient remained in much the same condition, suffering very considerable pain, especially of a neuralgic character, in the course of the sciatic nerve, and it was decided to explore the sacro-iliac joint.

August 27.—A crucial incision, involving the old cicatrix, was made over the upper and posterior part of the ilium; the bone was exposed, and there was evidence of subperiosteal thickening. A three-quarter inch trephine was applied one and a half inches before and below the posterior superior

spine, and the sacro-iliac joint opened; the joint-cleft was not wide, but granulations existed throughout the synchondrosis, and were removed with a Volkmann's spoon; the sacrum was found to be soft and carious, and a pit three quarters of an inch deep was scooped out of it: there was no pus met with or well-marked caseating tissue. A drain was introduced, and the wound dressed with perchloride of mercury gauze. A plaster-of-Paris spica and a long outside splint were then applied to the limb. The pelvis was carefully explored again with a view to detecting a pelvic abscess, but nothing was discovered.

The wound did perfectly well, but the drain was retained three weeks on account of the deep pit in the bones. There was never any rise in temperature, and the patient complained little of pain.

On October 9 the sinus still required dressing, but the patient was so much improved that the splints were discontinued. It was then found that he could turn over in bed without much difficulty, but he still complained of the neuralgic pain at times, and both his right hip and knee were very stiff.

The sinus proved a chronic one, and did not heal until April, 1889; for three months prior to this date, however, he was up daily in a wheel-chair, his principal trouble consisting in stiffness of the right hip-joint. He then left the hospital and went to Margate for three months. On his return I saw him, and he was able to walk with a stick and a high boot, but the hip-joint was firmly anchylosed in a slightly flexed position. The wound had remained closed, and a thick somewhat depressed cicatrix existed over the site of the trephine opening.

Case 2.—Nyman K., male, æt. $3\frac{8}{12}$; admitted into the Evelina Hospital on April 24, 1890. Family history good. The boy enjoyed good health until ten months ago, when he was run over. Since then he has been "delicate," and complained of pain in the right lower limb. A swelling was noticed over the joint one month prior to admission. He was walking daily until brought to the hospital, but was restless at night.

On admission.—Well nourished; walks with a limp. A large abscess exists over left sacro-iliac joint. There is no sign of spinal caries, and the movements of the hip-joint are free. Pain is caused by pressing the ilia together, and this

is still more marked on attempting to separate the anterior superior spines.

Two days after admission the abscess was aspirated; it rapidly refilled, and a week later chloroform was given, and the joint was freely opened by a posterior incision. About one ounce of pus was evacuated, and the tip of the little finger could be readily passed into the joint-cleft. The joint and abscess cavities were scraped freely; fragments of bone and cartilage and abundant caseating granulations were removed. The wound was then sutured and dressed with bicyanide dressings. No rise of temperature followed, and on the seventh day the wound was dressed and the sutures removed, as primary union was complete.

He remained in the hospital six weeks, and was then discharged, with a long Sayre's jacket applied. One month later he returned; the jacket was filthy, and when removed the wound was found to have broken down. He was then sent to a convalescent home, where he remained for two months; but as the sinus persisted, he was readmitted in October, and the sinus was thoroughly scraped. It healed completely in fourteen days, and he was again discharged with a plaster-of-Paris belt. He had no pain or tenderness, and walked well. The sinus, however, reopened a few weeks later, and remained *in statu quo* during the next two months. Since then I have been unable to trace him.

Case 3.—A. J., male, æt. 3; admitted April, 1891.

Consumption in father's family. Has suffered with signs of cervical caries for eighteen months.

A swelling has been noticed in the right loin during the last seven months, but the boy has not complained of pain until the last fortnight, during which time the swelling has increased rapidly. He has been able to stand and walk throughout. Sleeps well.

On admission, a delicate-looking boy; complains of pain in the back of the head and behind ears. Holds head stiffly, and frequently supports it with his hands. Moderate movements or pressure on head causes little pain.

A fluctuating swelling the size of a hen's egg is situated over the posterior extremity of the iliac crest. There is no impulse on coughing. There is no pain on manipulation of either hip-joint or pelvis, but the abscess is tender. No sign of any visceral disease.

One week after admission chloroform was administered

and the abscess opened by a vertical incision. Half an ounce of pus was evacuated, and several sequestra were found lying loose, and corresponding to the posterior part of the ilium. These were removed, and some carious bone and caseating granulations were scraped away. The wound was closed and dressed with bicyanide gauze.

Five days later the wound was dressed, and an opening was made to allow the escape of some pus which had reaccumulated.

On the seventh day the sutures were removed, and a small quantity of pus was let out.

A fortnight later the wound was firmly healed, and he was discharged cured with a long leather jacket from pelvis to shoulders, and a head support.

Six months later he could walk, run, and jump without pain, and the wound was firm and strong.

The boy is still under treatment for the cervical caries, which now seems stationary.

XXIX.—*Lympho-sarcoma of Tonsil: removal by external incision, with preliminary ligature of the external Carotid Artery.* By Raymond Johnson, M.B., B.S. *Read March* 3, 1893.

SARAH L., a married woman æt. 53 years, was admitted into the Great Northern Hospital under my care on June 13, 1892. She first began to experience slight soreness in the throat and difficulty in swallowing shortly before Christmas, 1891. In April, 1892, the throat trouble was so slight, that the patient only incidentally mentioned it to a medical man, whom she had consulted for some other trivial ailment. The duration of the glandular enlargement in the left side of the neck was doubtful.

On admission the patient was very thin, and her appearance confirmed her statement that she had lost much flesh lately. Her speech and deglutition were very difficult. The position of the left tonsil was occupied by an oval tumour, its longer vertical diameter measuring 1½ inches. The surface was very irregular, and formed of stunted papillary projections, which seemed to be superficially ulcerated. The outline of the growth was well defined and surrounded by a ridge of mucous membrane, which was firm and evidently infiltrated. The other parts of the mouth and pharynx appeared to be normal. Below and behind the angle of the jaw on the left side of the neck was a visible swelling, due to a mass of enlarged glands. The glands were soft in consistence, and were not adherent to one another or to the surrounding parts. Other smaller glands, similar in character, lay along the posterior border of the sterno-mastoid.

There were no signs of disease in any other part of the body.

The case was obviously one of malignant disease of the left tonsil, with somewhat extensive deposit in the lymphatic glands of the neck. The characters of the primary growth and of the glandular enlargement supported the view that the case was one of lympho-sarcoma. The question of the advisability of operation presented itself.

The primary growth was so circumscribed that the case seemed so far a favorable one. The extent of the glandular infection was the unfavorable element, but it did not seem to me sufficient to contra-indicate operative interference. After consultation with my colleague, Mr. Herbert Allingham, it was decided to remove the primary growth and the affected glands through an incision in the neck, and, as a preliminary step in the operation, to apply a ligature to the external carotid artery. Accordingly on June 20 the patient was anæsthetised with chloroform administered by Junker's apparatus. A slightly curved incision was made from below the lobule of the left ear to a point on a level with the hyoid bone. Further room was obtained by subsequently carrying a short incision downwards along the anterior border of the sterno-mastoid to the extent of an inch. After dividing the deep fascia in the whole length of the incision, several soft glands were very easily shelled out. The external carotid artery was now exposed in the lower end of the wound, and a silk ligature was applied to it below the origin of the lingual. The next step in the operation consisted in separating the parotid and submaxillary salivary glands, and turning them respectively upwards and downwards. The wall of the pharynx was thus exposed, and by means of the finger and a director the structures lying on it were turned backwards and held in a retractor. They included the internal carotid artery, jugular vein, and glosso-pharyngeal nerve, the vein being the only one actually seen. A free exposure of the lateral wall of the pharynx was thus obtained. The mouth was now opened with a gag, and Mr. Allingham, who kindly assisted me, made the last part of the operation easy by firmly pushing the tumour outwards with a finger in the mouth. The wall of the pharynx was snipped through with scissors above the upper border of the growth, and then completely around it until it was removed. Examination showed that the section had been made well beyond the outline of the growth except below, and here an additional strip of the wall of the pharynx was therefore cut away. The bleeding was altogether trivial, and so little blood entered the throat that scarcely any sponging was necessary. At an early part of the operation a small tributary of the internal jugular vein was divided close to the main trunk and gave some trouble, but was eventually secured and tied with fine silk.

The whole wound was thoroughly sponged with 1 in 500 sublimate solution, and powdered with iodoform. No attempt

was made to close the opening in the wall of the pharynx. The edges of the skin incision were adjusted with silk sutures and a drainage-tube inserted into the lower angle. The dressing consisted of alembroth gauze and wool.

The patient stood the operation well. For two days rectal feeding was adopted, and afterwards liquid food was given through a tube attached to a feeder, and passed to the back of the throat. The mouth was frequently washed out with Condy's fluid.

The drainage-tube was removed on the second day. At the next dressing half an ounce of offensive pus was evacuated from the lower end of the wound.

This accident no doubt arose from premature removal of the drainage-tube, and the consequent collection of fluids from the mouth in the deep part of the wound. On the seventh day healing was complete, except in the position of the tube.

Transient paresis of the lower part of the face on the left side and of the left half of the tongue followed the operation.

On July 14 the enlarged glands behind the sterno-mastoid were removed by a free incision along the posterior border of the muscle. They were soft, pinkish white in colour, and easily shelled out.

The patient left the hospital on July 23. There were no signs of recurrence. The parts removed by operation consisted of the primary growth and numerous diseased lymphatic glands. The former was oval in shape, measuring $1\frac{1}{2}$ inches by $\frac{7}{8}$ inch; the surface was formed of stunted papillary processes, rising to a height of $\frac{3}{4}$ inch above the surrounding mucous membrane. The growth presented the typical microscopic structure of a lympho-sarcoma. The largest of the glands removed exceeded an inch in length; all were soft in consistence, pinkish white in colour, and presented a microscopic structure similar to that of the primary growth.

Numerous cases are on record in which lympho-sarcomata of the tonsil have been easily enucleated from the mouth after division of the mucous membrane with the cautery. The possibility of this method depends upon the fact that these tumours show a peculiar tendency to remain encapsuled, even whilst they infiltrate the surrounding parts. The absence of recurrence *in situ* has, in some such cases, indicated that the removal has been complete. It seemed to me, however, that this object was more likely to be attained by attacking the growth from outside rather than from within the mouth. The

procedure adopted resembles in principle Kocher's operation for removal of the tongue: through one incision the glands are removed, the supplying artery ligatured, and finally the primary growth excised. The ligature of the external carotid artery adds very little to the severity of the operation, and by so doing we are freed from the necessity of performing a preliminary tracheotomy, and are enabled to quietly remove the growth with scissors, a method far preferable to the use of the cautery. The incision used in this case resembles that employed by Cheever (*Boston Med. and Surg. Journal*, 1871, vol. i, p. 390) and Golding-Bird (*Clin. Soc. Trans.*, vol. xvi); but I was able to dispense with the second incision used in each of these cases,—in one along the horizontal ramus of the jaw, and in the other from the angle of the mouth to the angle of the jaw. Ample room was obtained, and it was found quite unnecessary to resort to the division or partial resection of the jaw practised by Langenbeck, Mickulicz, and Czerny. The prognosis in cases of malignant disease of the tonsil, be it sarcomatous or epitheliomatous, is most grave. Thus Mr. Golding-Bird, in his remarks upon the case above referred to, says, "I am inclined to think the plan adopted in my second case referred to—namely, feeding by a soft œsophagus tube, with the alternative eventually of performing gastrostomy—more likely to meet all the real requirements of these cases, unless seen so early that there can be no suspicion of the growth having extended beyond the tonsil, nor of having invaded the lymphatic system except to a very limited and remediable extent."

Mr. Butlin finds that of twenty-three operations for malignant disease of the tonsil three died from the operation, three were lost sight of, ten died from rapid recurrence, and four from later recurrence; three were alive at periods of four, twelve, and twenty-four months after the operation.

The patient was exhibited eight months after the operation. She was in good general health, and free from recurrence in the mouth, although the right tonsil was now considerably enlarged, and there were some slightly enlarged glands in each side of the neck.

XXX.—*Intestinal Obstruction of six weeks' duration: inguinal colotomy: removal of malignant growth from the inguinal incision: recovery.* By HERBERT ALLINGHAM. *Read March* 3, 1893.

IN October, 1892, I saw Mrs. S—, æt. 54, in consultation with Dr. William Neale. The patient gave the following history,—she had always been subject to constipation, this having been most obstinate the last year. About six weeks prior to our seeing her the bowels ceased to act, and had for a month before only acted with difficulty and after taking powerful purgatives. Her doctor in the country administered enemata and purgatives, but without avail, only a little flatus at times passing, and on one occasion a little liquid motion. She had never passed blood or slime. When I saw her with Dr. Neale she had rather an "abdominal" aspect. Tongue dirty and slightly dry. The last few days she had vomited at times. Pulse was rapid and small. Abdomen greatly distended, not tender, tympanitic in front, dull in the loins. No growth was to be felt. Examination *per rectum* revealed nothing. No ballooning or obstruction to be made out. Operation was decided upon at once; from the length of time of the obstruction it was thought the stricture must be low down in the large intestine, so it was agreed to make an incision in the left inguinal region to examine the colon, and if found distended to open it there.

An incision 3 inches long was made about an inch inside the left antero-superior spine of the ilium, the peritoneal cavity opened, and the large intestine found distended. The gut was pulled up to the inguinal opening, and on inserting my hand (the abdominal incision being slightly enlarged) into the peritoneal cavity a mass was felt down in Douglas's pouch; this I seized and brought to the inguinal opening, and discovered to be a malignant growth in the sigmoid flexure. The growth and about 14 inches of the gut were pulled through the inguinal incision. The parietal peritoneum was stitched to the skin all around the abdominal incision, and then the large mass of sigmoid and the growth was forced outside the belly wall. I then proceeded to open the gut

above the cancerous mass, but, to our surprise, no fæces came away. I accordingly then opened the intestine below the malignant mass, and fæces at once were discharged. A Paul's drainage-tube was then inserted, and for three days fæces were discharged through this into a basin under the bed. After three days the tube was removed, being no longer required, as by that time any communication with the abdominal cavity was completely blocked off by lymph, and there was no fear of fæces leaking into the peritoneal cavity.

The abdomen rapidly diminished in size, and on the tenth day after the operation chloroform was again given, and my spiked clamp applied to the base of the protruding sigmoid.

The mass of gut and cancer was then cut away, the clamp being left on. The mass removed weighed 10½ oz. The clamp was left on thirty-six hours. Once in that period, as the stump contracted, there was a little oozing, necessitating the clamp being screwed up more tightly. At the end of thirty-six hours the clamp was removed; no bleeding whatever occurred.

In a week a small slough, caused by the clamp, came away, and in about a month's time the patient was quite recovered, the bowels acting daily from the opening in the inguinal region. I have to thank Dr. Neale most sincerely for the kind help he gave me in bringing the operation to a successful issue.

As this case is full of interesting points, I will tabulate them.

1. The length of the obstruction—six weeks.

2. Bringing the malignant growth through the inguinal opening outside the belly, and fixing it there.

3. The curious fact that I first opened the gut on the apparent proximal side of the growth, and no fæces were discharged, but on opening the gut on the apparently distal side of the growth, motion poured out; thus showing that when the growth and sigmoid flexure were pulled into the inguinal wound the gut was twisted one half-turn on itself, and so sutured to the opening.

4. The use of Paul's tube, and the great advantage of it in that no fæces flowed over the wounds until all communication with the peritoneal cavity was shut off by lymph.

5. The usefulness of my spiked clamp, and the amount of gut and cancer removed without hæmorrhage.

6. No prolapse of gut after the operation—a good sign, and the fact that the bowels acted from the lower of the

two orifices in the inguinal region, the reasons for which have been already explained.

It may be asked why the growth was not removed at the first operation, and the ends of the bowel sutured together and returned into the abdomen. My reply is that the intestine was too distended to allow of this being done; and again, the patient was too ill to stand a lengthy operation. Moreover, from the great distension, I felt sure the suture would not hold, and there would have been some leaking of fæces into the peritoneal cavity.

XXXI.—*Two exceptional cases of Peripheral Neuritis, one septicæmic, the other due to lead, and presenting unilateral faucial paralysis and other rare symptoms.* By W. Hale White, M.D. *Read March* 24, 1893.

CASE 1. *Septicæmic neuritis.*—Stephen O., æt. 33, admitted into Stephen Ward, Guy's Hospital, under my care, November 21, 1892. (Clinical clerk, Mr. G. S. Hovenden.)

The family history is unimportant. Four years ago he was laid up for six weeks with rheumatic fever. He got quite well after it, and he does not know that his heart was affected. Three weeks ago he noticed that his feet were swollen, and that he could not get his boots on. This swelling increased, and three days ago, when he got up in the morning, he noticed that there was a small ulcer on the middle part of the left leg, and rather to the inner side of the anterior border of the tibia.

On admission.—Temp. 100·4°, pulse 124, resp. 25.

Both legs are extremely swollen, and pit on pressure. The œdema extends up the thighs and over the lumbar cushion, but there is none of the face or arms. The left leg is more swollen than the right, and in the position just indicated there is an unhealthy-looking ulcer 4 inches in diameter. For an inch round the ulcer the skin is of a dirty blue colour, and beyond that there is a red areola, over which the skin is glossy. On the right leg there are several patches covered with scales, and one on the outer side has already begun to break down and form an ulcer. There are no enlarged glands in the groins.

In the position of the apex of the heart there is a loud blowing systolic murmur conducted into the axilla; the position of the cardiac apex cannot be defined. The rest of the body appears healthy. The diagnosis made was mitral regurgitation and septicæmia from the ulcers on the œdematous leg.

November 22.—Morning temp. 100·2°, evening 102·8°.

November 23.—Morning temp. 102·4°, evening 103·8°. The ulcer is still very unhealthy-looking, and it has spread, especially backwards on the inner side. The skin below it, particularly over the internal malleolus, is very red and inflamed. In

the afternoon, for the first time, the patient noticed that he could not bend his hands, and on examination it was found that he had wrist-drop on both sides, with great weakness of grasp, but no loss of sensation.

November 24.—Morning temp. 100·2°, evening temp. 103°. The wrist-drop is more marked to-day. It is worse on the right side than on the left. On the right side the whole arm is weak, but extension of the elbow, of the wrist, and pronation are entirely lost. Supination and flexion of the fingers are both weak. Flexion of the elbow is the strongest movement. There is no loss of sensation nor pain on pressure. The ulcer on the leg, which has been treated with hot boracic lint and iodoform, is still foul.

November 25.—Morning temp. 101·6°, evening temp. 102°. The following movements of the upper extremity are affected:

Right hand: flexion of fingers weak.	Left hand: flexion of fingers weak.
„ wrist: flexion weak.	„ wrist: flexion weak.
„ „ extension paralysed.	„ „ extension paralysed.
„ supination weak.	„ supination weak.
„ pronation paralysed.	„ pronation paralysed.
„ elbow: flexion weak.	„ elbow: flexion weak.
„ „ extension very weak.	„ „ extension weak.
„ shoulder: adduction weak.	„ shoulder: adduction fairly strong.
„ „ abduction weak.	„ „ abduction fairly strong.
„ „ extension weak.	„ „ extension weak.

The supinator longus on both sides is paralysed.

There is no loss of sensation, but there is tenderness on pressure over the muscles of the forearm and hand on both sides, and some over the ulnar and musculo-spiral nerves. The ulcer on the left leg is larger and looks very angry; the foot is swollen, and the skin over it is red and glossy. The ulcer on the right leg has healed.

November 26.—Morning temp. 101°; evening temp. 102·4°. The ulcer on the left leg is still larger; otherwise the patient's condition is unchanged.

After a consultation with Dr. F. Taylor and Mr. Lane, it was decided that, as the ulcer was spreading very rapidly and had nearly reached the knee and the ankle, it was necessary to amputate the leg. The patient was accordingly transferred to a surgical ward. The paralysis remained as in the last note, but the tenderness of the muscles increased.

December 5.—The stump is healing slowly. There are no fresh developments of paralysis, but the parts already

paralysed are even weaker. The tenderness of the muscles of the forearm is very marked. There is no perversion of sensation.

February 17.—Patient left the hospital to-day. The wound had healed, and the grip of the hands, which during the last few weeks has been increasing, was almost normal.

As this neuritis supervened while the patient was suffering from the extremely unhealthy ulceration of the leg, there can, I think, be no doubt but that it was septicæmic. Such cases are rare, but references to others will be found mentioned in Gowers' *Diseases of the Nervous System*, 2nd edit., vol. i. Some have also been recorded by Ross and Bury in their *Treatise on Peripheral Neuritis*, p. 291. It is interesting to observe that the present case did not show the interval of two or three weeks between the septicæmia and the onset of the neuritis, which has often been observed.

Case 2. *Unusual form of saturnine peripheral neuritis.*—Ed. G., æt. 45, admitted into Stephen Ward under my care, November 20, 1890, for colic and pain in the limbs. (Clinical Clerk, Mr. H. E. Durham.)

From October 8 to October 14, 1889, he was in John Ward under Dr. Pavy for colic, giddiness, constipation and vomiting, cramp in the right hand and left leg and foot, and weakness of right wrist. He then had a faint blue line. He had been painting for a month.

Thirteen years ago he worked in lead for two years, had colic twice, and then gave up the work. He had rheumatic fever at the age of twenty-three, and for three years after had palpitation of the heart. No gout.

Since his leaving the hospital he has worked in lead, and for the last two months in white-lead works. Three weeks ago he had an attack of colic and vomiting for three days, after which he felt quite well.

He felt queer on November 19. On November 20 he was taken suddenly ill with very acute pains, both in his limbs and his body, and especially in the lower part of the spine.

On admission.—Is of a pale ashy colour, with grey hair. He is suffering from great pain in the abdomen and limbs, which is so severe that it is unadvisable to make a very minute examination, but the following points are noteworthy:

Sensation.—There is severe pain across the umbilicus and in the loins, running down to the anus and the testicles.

There is pain in the limbs of an acute aching character,

referred chiefly to the ankles, knees, shoulders, and wrists—the left wrist is slightly swollen. The left arm and leg are more affected than the right.

In the arm the pain is most intense along the musculo-spinal nerves, extending especially to the thumb and index fingers in the left hand, and the middle and ring fingers in the right. Slight pressure on the musculo-spiral and extensor muscles of the forearms causes severe pain, that on the ulnar nerve causes less pain. In the lower extremities the pain is most acute along the external popliteal nerves and over the peronei and tibialis anticus muscles, which are themselves very painful and tender to the touch. Slight pressure on the external popliteal nerves causes severe pain in the heel and the two outer toes. The quadriceps muscles are also tender and painful.

Motion.—He has marked wrist-drop, and cannot raise the hand by the extensors, and can only extend the fingers very slightly. The flexors are also very weak. Supination is normal. The supinator longus and the extensor ossis metacarpi pollicis muscles are not affected.

The entire leg can hardly be raised from the bed. The knees being supported, the legs cannot be extended on the thigh. The flexion of both ankles is weak. The feet remain in a slightly extended position. The knee-jerks are lively.

The pupils are equal, the reaction is normal; both the optic discs are swollen, slightly blurred, and the vessels are a little obscured.

The larynx cannot be satisfactorily seen because of the want of tone in the epiglottis, but the patient's voice is very suggestive of some paresis. There is occcipital headache.

The heart, lungs, and urine are all normal. Pulse 60; temp. 98·4°.

There is a blue line on the gums, otherwise the mouth and palate are normal. There is vomiting after food, and the bowels are constipated.

Treatment.—Opium and belladonna pills thrice a day. Castor oil ℥j, with Tinctura Opii ♏xv, at once. Ten-grain doses of iodide of potassium thrice a day. Lotio Spiritûs to the arms and legs. The pain made a subcutaneous injection of gr. ¼ of morphia necessary, and this had to be continued daily for several days.

November 23.—He is rather better; there is less pain and tenderness, and the wrist can be a little better extended.

The blurring and swelling of the optic discs has quite disappeared. The vomiting, constipation, and headache continue. The urine gives a slight darkening with sulphide of ammonia.

November 25.—Bowels slightly opened. The abdominal pain is better. The limbs are free from pain, but still tender.

November 26.—Bowels well opened. Abdominal pain better. There is extreme tenderness of the left gastrocnemius (this was not previously affected), and there is hardly any power of extension of the left foot, but this movement is vigorous on the other side. Both plantar reflexes are very lively, and the knee-jerks are active. The other muscles, which were previously tender, are still so. The feet are cold and numb. Up to this time the urine has given a distinct darkening with ammonium sulphide, after this date it did not.

November 27.—When the joints are moved there is considerable pain in the extensors of the arms. The metatarsophalangeal joint in each toe is painful, and acutely so on passive movement. The left knee-jerk is more marked than the right. Both temporo-maxillary joints are very painful and tender, and there is pain radiating along the auriculotemporal nerves.

November 29.—The pain and tenderness in the temporomaxillary articulations is better. Both shoulder-joints are painful, especially the right. A creak can be felt in the left on passive movement. The tenderness of the musculo-spirals and arms is better. The left gastrocnemius and left external popliteal nerves are still tender. The knee-joints are painful, and there is marked grating in the left.

December 1.—He complains of numbness of the forearms, especially the left, where it is found to correspond in distribution to the posterior and external branches of the musculo-spiral and the radial nerves, extending over the back of the throat and index fingers and over the radial half of the back of the middle finger. The skin over the deltoid is also numb. There is very slight numbness over the same nerves in the right arm, but it is too slight to localise exactly. There are some signs of bronchitis.

Electrical examination.—All the muscles tested acted normally to faradism. They also acted normally to galvanism, except that the flexors of the left forearm gave the reaction KOC > KCC > AOC > ACC. The KCC reactions were generally elicited with a current of 4 m.a.

December 2.—There is some paræsthesia on the left leg,

limited internally by the anterior border of the tibia and forming a narrow strip which spreads out on the foot, the two outer toes being normal, and also the inner side of the foot and great toe up to the metatarso-phalangeal joint—that is to say, the outer branch of the musculo-cutaneus and the internal saphenous are unaffected. The paræsthesia extends irregularly on to the thigh. The knee-jerks are not so lively as they were. The right optic disc is a little blurred.

December 3.—The tenderness is less and the power is more all over the body. The patient can stand up rather shakily. The left wrist is painful, but not swollen. There is no abdominal pain. A perimetric chart was taken; it will be seen that both eyes, especially the left, show a diminution of the field of vision.

December 4.—There is paræsthesia in the left supra-orbital region, over the left side of the thorax, the right side of the abdomen, and the lower part of the face on the right side. The muscle sense was tested with weights put on a card, and was found to be considerably impaired. The numbers represent ounces.

Right hand.	*Left hand.*
Increase 4 to 5 not felt.	Increase 4 to 5 not felt.
Decrease 5 to 4 not felt.	Decrease 5 to 4 felt.
Decrease 3 to 2 felt.	Decrease 3 to 2 felt.
Increase 2 to 3 not felt.	Increase 2 to 3 felt.

Temperature sense tested with warmed and unwarmed spoons, and was found to be considerably blunted. Thus—

	Right.	*Left.*
Dorsum of hand	Positions and difference unidentified	No discrimination, or answers given wrongly.
Forearm (front) and Palm of hand	Difference not discriminated	

The vocal cords could not be seen, as they were hidden by the epiglottis, but it was noticed that the left side of the palate was distinctly higher than the right, but the uvula was in the middle line.

The discs were now normal, except that the veins of the right side were dilated. There was no colour-blindness. Mr. Brailey thought that, judging from the limitation of the fields (*see* Fig. 3) in their peripheral part, there might be some degeneration in the peripheral fibres of the optic nerves extending in from the sheaths.

December 5.—There is still numbness in both legs, but that in the left is more marked than that in the right. Plantar reflexes and knee-jerks present. Grating and pain still present

Fig. 3.

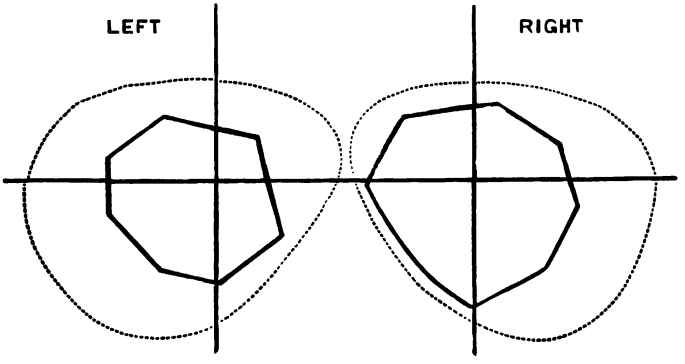

Fig. 4.

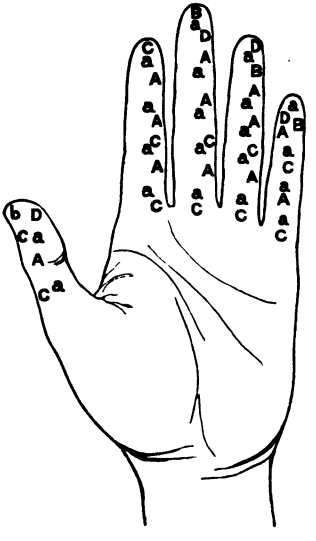

in the left wrist. None of the nerves or muscles are as tender as they were, but some are still tender, and they are not yet as firm as they should be. There is a very good grasp with the right hand.

The appreciation of taste was tried; it was sluggish everywhere, but ultimately the different tastes were distinguished.

December 6.—His finger tips were tested with the object of seeing how far apart he could distinguish points (*see* Fig. 4). It was found that his power was very deficient. Two points, 4 mm. apart, could not be distinguished. When 5 mm. apart they were distinguished at *a* always. When 6 mm. at *b* always; at *b'* sometimes. When 8 mm. apart at *c* always. When 9 mm. apart at *d* always.

December 8.—Patient is altogether better. The grating in the left wrist is less, and there is no pain in it. The various muscles that were painful and tender are hardly so at all. The paræsthesia has diminished. The muscular power is everywhere improved; the knee-jerks are normal. The optic discs appear healthy. The left foot is a little everted. The patient gets up.

December 10.—There is great pain in the right ankle, but no tendo-synovitis nor fluid in the joint can be made out. He also says that the left elbow is painful when he moves it. The pain in the left wrist is very slight.

December 11.—This evening there were shooting pains down the outside of the left leg and ankle. There is similar but slighter pain in the right leg.

December 16.—Patient has a headache, especially over the left temple. The left ankle is painful, especially on movement; there is some fulness about it, but no fluctuation. Left peroneal nerve much more tender than during the last few days. The left knee is rather painful on movement, but there is no effusion nor grating. The left elbow remains tender. Both the ulnar and musculo-spiral nerves are also tender.

December 18.—Left ankle still swollen and painful and tender, but no fluctuation. The left knee is painful and tender. The left great sciatic nerve and the two popliteal nerves are tender on pressure. The left calf muscles are tender. The other joints and the right side of the body are free from pain. On the right side the arch of the soft palate is much lower than on the left. The right posterior pillar of the fauces projects inwards more than the left. Both posterior pillars approach the uvula when the patient says "Ah," but the

right does not return so far outwards as the left. His food does not regurgitate through his nose. He was ordered methylacetanilide for the headache and pain in his leg.

December 20.—Headache better. Left ankle still swollen and painful, and left lower extremity still painful. The left musculo-spiral nerve is not very tender, but there is great tenderness where the left posterior interosseous nerve passes through the supinator brevis. Pronation and supination are painful, but flexion does not hurt. Calf measurements five inches below the patella: left, 12 inches; right, 12½ inches. The condition of the palate and its posterior pillars is unaltered.

December 22.—To-day and for some few days he has complained of great pain in the throat, but there is no injection nor swelling. The condition on inspection is unchanged.

December 23.—Last night he complained of burning pain in the fauces and back of the nasal cavity, especially left side, and there is acute pain running to the lower part of the back of the left ear (Arnold's nerve) and up the occipital region (great occipital). There is also running of the eyes and nose, and a large amount of salivary secretion. (Has omitted his iodide of potassium for some time.) The left wrist is very tender.

December 24.—The accompanying sketch (Fig. 5) shows

FIG. 5.

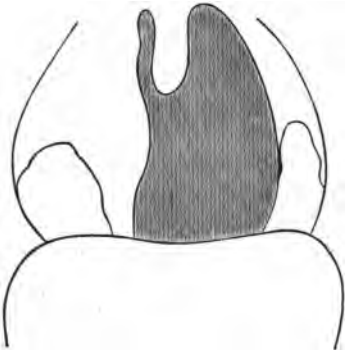

the condition of the posterior pillars of the fauces. It will be seen that the chief abnormality is that the right posterior pillar remains drawn inwards quite close to the middle line.

This is no doubt due to paralysis of the opponents of the palato-pharyngeus. There is now no difference in height of the arch of the palate on the two sides. The uvula is hardly more deflected than is often the case in health.

January 9, 1891.—Since the last note the patient has been improving steadily in all respects. He can now walk well, and he has little if any pains anywhere. The right posterior pillar of the palate has almost regained its normal position, and it moves much better on phonation. The knee-jerks are equal and normal. He can bear considerable pressure on the left external popliteal nerve. The left musculo-spiral nerve is slightly tender, and there is slight numbness in the left forearm and hand over the area indicated on December 1. On the face there is still numbness, but very slight. Temperature sense on the legs and arms is normal except once or twice on the back of the left arm, when the spoon was just at the bodily temperature no contact was appreciated, but he always discriminated when the spoon was distinctly warm. Muscle sense as follows; the figures indicate ounces:

	Right hand.	*Left hand.*
2+1, 3−1, 4+1, 5−1	Always appreciated correctly	Always appreciated correctly.
6+1, 7−1	Always appreciated correctly	One or two failures, but also one or two successful discriminations.

His fields of vision were practically normal. Except for the points above mentioned he was in all respects healthy. He left the hospital.

This case of lead-poisoning has seemed to me worthy of record because of the large number of unusual symptoms presented by it. They are the following:

1. The extremely sudden onset. This is by no means unknown, but it is exceptional.

2. The very acute pain in the limbs and marked tenderness in the muscles and nerves. These symptoms, although often present, are rarely so severe as in this case, and according to Dr. Oliver they do not commonly persist long, but in my patient as soon as the tenderness and pain had disappeared in one part it reappeared in another, so that ultimately almost all the body was affected.

3. The unusually wide extent of the muscular paralysis. I have only once before seen so many muscles paralysed by lead,

and in that case—which was, however, chronic—all the muscles of the body, even those of respiration, were implicated.

4. The retinal changes have been fully described by Gowers and Oliver, but it is interesting in my case to observe the peripheral limitation of the fields of vision, as that suggests that the peripheral part of the optic nerve was affected by neuritis.

5. It is exceptional in peripheral neuritis for the knee-jerks and plantar reflexes to be lively, as in this case. Probably it is to be explained by the condition of hyper-excitability of the peripheral nerves.

6. The tenderness and swelling of several joints has been described, but it was in my case a remarkably extensive symptom. Possibly it is due to trophic changes in the joints, dependent upon the neuritis. My patient had never had gout.

7. Oliver mentions sensory symptoms, but they are unusual. Nevertheless the case under consideration showed numbness, coldness, perversions of sensation of touch and pain, which I have called paræsthesia, and perversion of muscle sense and temperature sense.

8. Perhaps the most remarkable symptom in the patient was the paralysis of the posterior pillar of the fauces. Unilateral paralysis of the palate, although rare, is described, but I do not know of any description of paralysis of the posterior pillar on one side only.

XXXII.—*Infusion (or Transfusion) of normal Saline Solution in severe Shock.* By A. W. Mayo Robson. *Read March* 21, 1893.

TO the operating surgeon nothing can be more distressing than that, after the apparently successful performance of some extensive operative procedure which has involved much thought and care and no little anxiety, he should find his patient, though very little blood has been lost, in a state of collapse, which, despite stimulants by the rectum or by the mouth, ether injections and warmth to the surface, shows no sign of passing off, but gradually tends to a fatal termination. Every surgeon accustomed to perform operations of any magnitude must have had experiences of such a kind; and, speaking for myself, some of my most anxious moments have been spent by the side of several cases of this nature.

My paper is brought forward with the view of showing what has been the effect of saline transfusion in cases of intense shock, the result of severe injury.

Possibly the same idea has occurred to others, and I should not wonder to hear that it has been a regular custom with some surgeons to employ transfusion in such cases where loss of blood does not enter into the question; if so, I am unaware of their views having been published, and in none of the text-books or other works of reference to which I have had access can I find that transfusion for shock has been suggested as a means of treatment.

Out of a number of cases I will relate two which will serve to illustrate my views.

Case 1.—Miss P., æt. 43, was sent to me by Dr. Woodcock, of Boston, on account of a large fibro-myomatous tumour of the uterus, which, having completely filled the pelvis, had produced retention of urine and almost complete obstruction of the bowels. The operation for the removal of the tumour was performed on the 26th October, 1892, Dr. McGregor Young administering ether, and Dr. Woodcock assisting me in enucleating the mass. The operation occupied about an hour and a half. Very little blood was lost, but the pulse, which was about 100 before commencing to operate, was 180 at the finish, and Dr. Young told me that I ought to conclude

as quickly as possible, as the patient's pulse was failing. She was removed into bed, hot water bottles were applied, and brandy was administered by the rectum.

Anæmic before, she now looked pale and pinched, as if she had had a severe hæmorrhage; the pulse was extremely feeble, and could just be felt at the wrist. The foot of the bed was raised, warmth was applied to the head, and ether and digitalis injections were given. The patient soon regained consciousness, but the pulse, instead of improving, steadily got worse, and at the end of three hours I received a message to say that she was gradually sinking. On my arrival the radial pulse could barely be felt and could not be counted, although there had been no loss of blood since the operation. There was that long-drawn sighing with restless but feeble lifting and dropping of the arms, and weary turning of the head from side to side, which so often precede death.

With some little difficulty a vein was found at the bend of the elbow, and about three and a half pints of normal saline solution was injected. The patient at once began to look better, the colour returned to the lips, the pulse could be felt distinctly at the wrist, beating 150 to the minute. From this time improvement continued until she was able to return to her home, at the end of the third week after operation.

Case 2.—Mrs. L., æt. 28, was sent to me by Dr. Reader, of Wakefield, suffering from a large sarcoma involving the upper half of the right thigh. As the tumour impinged on the pelvis, and as the femoral vessels could be traced into its substance, it was clearly useless attempting its removal without being prepared for amputation at the hip-joint.

Ether was administered by Dr. McGregor Young, and I was ably assisted by Mr. H. Littlewood and Dr. Reader. An Esmarch's bandage was applied as high as the upper end of the lower third of the thigh, so as to render the limb exsanguine, and prevent venous hæmorrhage. An incision was then made in the course of the femoral vessels down to the tumour, which it was soon manifest could not be removed without amputation at the hip-joint. The common femoral artery and vein were then ligatured in their continuity, and the amputation was completed without material loss of blood. The patient's pulse was fairly good when she was removed into bed, but it rapidly began to run down, and half an hour after the operation it could not be felt at the wrist, and the patient looked as if she were about to die.

Four pints of normal saline solution was injected through an opening in the vena salvatella, and immediately the patient's pulse returned at the wrist and colour came to the lips. The pulse remained quick for several days, but no further trouble was experienced, and beyond delayed healing owing to a portion of flap sloughing, there was nothing special to record.

Were it necessary, I could relate several other cases where severe shock has been successfully combated by transfusion: since in these, however, there had been material loss of blood, which would increase the collapse, it is scarcely right to attribute the recovery after transfusion solely to relief of shock; I prefer, therefore, to relate simply the two cases where very little blood was lost, and to base my arguments on them.

The reason for relief by infusion or transfusion in some forms of shock is not far to seek,—I say some forms because "shock has many varieties," as Furneaux Jordan says, and it may be that the treatment here suggested will only prove useful in certain cases not yet well defined, and a greater number of cases will be required before any generalisation can be even attempted.

In Sir William Savory's article on "Shock," in the *System of Surgery* edited by Messrs. Holmes and Hulke, it is stated, "The signs of syncope are those of collapse;" and again, "So far as they extend, the symptoms of an ordinary fainting fit are analogous to those of collapse." Travers says, "A fit of syncope, and the recovery from it, present an epitome of the phenomena of shock."

Brunton shows that shock is mainly due to paralysis of the heart and vaso-motor paralysis of the abdominal vessels, and the sudden dilatation of the abdominal vessels may simulate sudden hæmorrhage.

In cases of shock without serious hæmorrhage the blood is driven into the large abdominal veins, where for the time being it is useless, leaving the head and the extremities in a state of anæmia. Now if, by injecting several pints of bland fluid into the vessels, we can force the dormant blood into circulation again, the effect should be at once manifest by a filling of the vessels in the head and extremities; and although the blood will be diluted, the increased quantity, three to four pints, will be sufficient to fill the dilated and partially paralysed abdominal vessels, as well as the vessels

supplying parts essential to life; the heart, moreover, will be likely to be stimulated by the blood being driven into it.

The cases I have related would seem to bear out these suggestions.

The subject is one which should be capable of experimental proof, and if my suggestions are considered to be worthy of further prosecution, I have no doubt that proof can be furnished in this way.

My own conviction from personal experience is so distinct that it has become my practice, whenever I go to perform a capital operation, to include among my instruments a transfusion apparatus, and a packet of salt sufficient to make four pints of normal saline solution.

This practice I venture to recommend to others, and I think it will be the means of saving some lives that would otherwise be lost, not only after operation, but after other serious injuries.

XXXIII.—*Gastro-enterostomy for Cancer of pyloric end of Stomach.* By HERBERT ALLINGHAM. *Read April* 14, 1893.

J. R., æt. 47, was admitted into the Great Northern Central Hospital, February 24, 1892.

On admission the patient stated that her illness had commenced in the previous October (1891) with occasional sickness and pain in the epigastric region. The pain was aggravated by taking food, and had obliged her to avoid certain articles of diet. The attacks of sickness were of daily occurrence, and recurred every evening after her tea-time (5 P.M.). The vomiting was preceded by a burning sensation at the epigastrium and at the back of the mouth. There was no excessive straining, for the contents of the stomach welled up into the mouth, and the vomiting relieved the epigastric pain for a time. The matter vomited consisted of her meals, and was of a frothy appearance, light yellow (sometimes greenish) in colour, and non-offensive. It had never been observed to contain blood. She first noticed a "lump" in the epigastric region, immediately below the costal margin and slightly to the left of the xiphoid cartilage. This lump was hard and not tender, and all the epigastric pain seemed to be localised in that region.

As to the patient's personal history, she was a single woman, and her periods had been regular, having, however, been affected by her illness. For three years previously her health had been less good than formerly, for she had had occasional bilious attacks, which were always amenable to treatment. Constipation had been her chief trouble. In March, 1891, she had been in a county hospital for gout in the stomach, and had been benefited by her stay. She had also had rheumatic pains in the knees, ankles, and great toe-joints, but had never suffered from a severe attack. For eighteen years her occupation had been that of cook and housekeeper. There was no family history of any malady.

The patient was a fairly well-nourished woman, weight 8 st. 2 lbs., but stated that she had lost a considerable amount of flesh. Her complexion was clear, not anæmic; the skin was dry and not harsh. She was feeble, and her muscles generally were flabby, and the skin of her body could

readily be picked up in folds. The expression of her face was anxious and betrayed pain. The tongue was clean and moist, but the bowels were obstinately confined; her chief complaint was of daily sickness and considerable epigastric pain and tenderness. For three weeks she had kept her bed, her symptoms having become aggravated while she was at the sea-side for a change of air.

The abdominal walls were thin, but the abdomen was not distended, and there was no enlargement of the superficial veins, no local prominence, and no visible peristalsis. The patient referred pain of a gnawing character to the epigastric region, immediately below the xiphoid cartilage and to the left side. The pain was for the most part constant, and was relieved, for a short time only, after vomiting; it was aggravated by food, milk and iced water occasioning the least discomfort. When the pain was most intense it was associated with gnawing pain in the back, between the shoulders, and in that situation it was diffuse, not localised as it was in the epigastric region.

On palpation there could be felt in the epigastric region, below and to the right of the xiphoid cartilage, a hard nodular growth of the size of a Tangerine orange. It was not rounded, appearing to be square in outline, with well-defined abrupt edges. In this situation the lower limit of the growth was easily felt; immediately below the ensiform cartilage and to the left, beneath the costal margin, as far as the outer border of the rectus, was a resisting hard mass. This appeared to be deeply seated, was dull on percussion, and had a communicated impulse. But there was no bruit or lateral expansion, and it did not descend with deep inspiration. The mass was tender on palpation, an examination causing pain, which lasted for some time. This pain was aggravated by pressure on the epigastrium. According to the patient's account this lump had gradually increased in size, and was stated to "move." At times, when she was lying on the left side, it had been felt in the left hypochondriac region. When she stood erect it did not descend to the umbilicus. The rest of the abdomen was resonant, and there was no dulness in the flanks.

In spite of her constant sickness she had no actual distaste for food, and felt hungry. Though weak she was not exceedingly debilitated, and there was no tingling or numbness in the extremities. She seldom perspired, and the skin was always dry, but she was never feverish.

On the night of February 20, after a large enema, the bowels acted for the first time for twelve days, the motion being constipated, light brown in colour, and not scybalous. She was obviously wasting, and in spite of her being anæmic, her face flushed each evening when the nausea set in.

On March 2, the stomach having been previously washed out, an *operation* was performed. The abdomen was opened by a 4-inch median incision, commencing above at the ensiform cartilage. There was no free fluid in the peritoneal cavity. The stomach was then explored, and its pyloric end was found to be occupied by a growth the size of a Tangerine orange, which was very dense and not moveable. The anterior wall of the stomach was drawn up into the wound, and sponges were well packed around it. An incision, 1½ inches long, was therefore made into the stomach, which was practically empty, only a little clear fluid escaping. A coil of jejunum about 22 inches from the duodenum was similarly isolated, and was incised to the same extent, having previously been emptied and commanded by india-rubber cord passed through the mesentery in two places. The bowel was empty, a slight amount of succus entericus passing. Into the incision in the bowel and stomach bone plates were inserted. The bone plates were opposed, taking with them the apertures into the stomach and bowel. These were tied together by three threads. Numerous points of sutures, Lembert's, which were passed through the peritoneal coverings of the stomach and bowel, were afterwards put in. The abdominal wall was closed by silkworm gut sutures, and an alembroth dressing was applied.

The patient suffered from shock, but was not sick. She passed a fair night. On the next morning she was twice sick before noon, the vomit being watery and like coffee grounds, with some mucus. She was fed by nutrient enemata.

On the morning of the 4th she complained that the brandy in the enemata caused nausea and a burning sensation at the pit of the stomach. In the afternoon the wound was dressed. There was flatulence, and there was some dulness in the left flank, but the abdomen was not distended or tender. Later in the afternoon, immediately after an enema, there was another attack of vomiting.

On the 5th the vomit was for the first time bile-stained and of a greenish colour.

On the 8th the wound was dressed and three sutures were removed. Later on two more sutures were taken out. An

enema was given, which at first had no effect, but later on in the day, for the first time since the operation, there was a copious action of the bowels, the motion being light brown and bilious in appearance.

During the four days before the 14th the bowels acted three times after a liquorice powder. The patient had been free during the week from sickness and from the evening nausea. Nutrient enemata had been discontinued, and light food was given by the mouth.

Between the 10th and 18th the bowels required purgatives to make them act. On the latter date the wound was quite healed and firm. That evening she was sick again.

For several days there was loose action of the bowel, the dejecta being of a light brown colour and containing partially digested food. The patient was able to be up on a couch.

On the 21st there was some sickness, but the vomit was only watery. On this day she was allowed to take her first stimulant, a little port wine.

Through the first fortnight in April the patient was free from sickness, eating light food, and being in comparative comfort; but on the 14th she had some nausea (though no actual sickness) in the evening, and complained of the old burning sensation at the back of the throat. On the 17th the same occurred, together with some greenish watery vomit, which contained little food.

On the night of May 10 she was sick, the vomit consisting of digested food, but being free from blood and not frothy. For some days after this there was pain in the left hypochondriac region, which was stabbing in character and shot through the back.

On the 14th the pain still continued.

On the 15th there was some sickness after tea, the vomit being composed of altered food, bile-stained and frothy. The patient had had much regurgitation of hot and acrid watery fluid into the back of pharynx. This was worse on lying down, and she therefore sat up during the night.

On May 20 pain in the right supra-clavicular region drew attention to a lump in that situation. The swelling was tender, but the skin was not reddened. The pain shot down the arms, and the finger-tips of the right hand were livid, but there was no marked œdema of the right limb. Hot fomentations, &c., were applied, but gave no relief. On the 28th the lump was still stationary; there had been much pain in the neck and shoulders.

Her weight was 8 st. 10 lbs. as against 8 st. 2 lbs. at the time of the operation.

May 31.—She left the hospital.

About a month later, June 29, I saw her, and she informed me that liquid food was taken with comfort, but with solids she occasionally vomited. She at the same time complained of pain in the left chest, and the mass in her neck had enlarged and was more tender.

She went to the north of England, and died about the end of July, and I regret to say I did not hear of her death until about a week after it occurred, so was unable to obtain a post-mortem. The patient lived about five months after the operation.

XXXIV.—*A Sequel to some cases showing Hereditary Enlargement of the Spleen.* By CLAUDE WILSON, M.D., and DOUGLAS STANLEY, M.B. *Read April 14, 1893.*

THREE years ago a paper was read by one of us before this Society, entitled "Some Cases showing Hereditary Enlargement of the Spleen."* That paper, which referred to six patients belonging to three generations of the same family, opened with the statement that, as far as could be ascertained, no cases of a like nature had been described; and while it entered into the history, symptomatology, and physical condition of the patients, it was incomplete, as, though one death had been recorded, no material was available on which to found a pathological report.

Four of these patients are still living, and while one of our objects will be to briefly bring their histories up to date, the justification of the present paper lies in the fact that one of the patients died in March, 1891, and that though no complete autopsy was permitted, leave was obtained to make a somewhat hurried examination of the abdominal contents. The spleen was removed entire, along with portions of the liver, kidneys, and pancreas, and sections of these organs have been subjected to careful histological scrutiny.

The object of our present communication will be, then, to describe the last illness of the lady who was referred to in the previous communication as "Mrs. T.," to report upon the pathological changes found in the abdominal viscera; to allude to certain points connected with the other cases, and to inquire how far this additional knowledge may help us in arriving at the true nature of these cases.

"Mrs. T.," as previously stated, was born in 1857, became sallow when five or six years old, and certainly showed enlargement of the spleen when she was seven years of age. She was born when her mother was thirty-one years old, and it was not till two years after this that the mother's spleen was found to be enlarged; how long the condition may have existed is not known.

* *Clinical Society's Transactions*, vol. xxiii, p. 162.

Mrs. T. married in 1878, and two of her four children were found to have large spleens when they were seven or eight years old; they have both been sallow since infancy, and probably their spleens were enlarged for some years before they were discovered.

Unlike her brother, A. P., jun., Mrs. T. had never suffered much from ailments which could be very distinctly referred to the spleen, but she used to have occasional attacks of jaundice and pain, which we ascribed to small biliary concretions. Her youngest child was born in 1884, and since then she had up to 1889 two miscarriages and a stillborn child. In the summer of that year she again became pregnant, and as her confinement drew near her health began seriously to fail. She slept badly, became very short of breath on slight exertion, and at the end of February, 1891, developed decided jaundice, with nausea, retching, vomiting, and complete anorexia. She was confined to her room, and gradually became so weak and feeble that she could hardly walk unaided from the bed to a chair. Careful feeding was had recourse to at frequent intervals, and a good deal of nourishment was retained. She became extremely anæmic but not emaciated. We regret that we have no further notes of her physical condition at this time.

It is needless to say that her confinement was looked forward to with apprehension, both by herself and her medical attendants. On March 20, about a week before term, she said that the child had ceased to move, and that it was dead, and on the next day labour was heralded by a slight discharge. Pains came on and the waters escaped at 4 A.M. on the 22nd, and this was followed by a period of quiescence which lasted until evening; but at 3 A.M. on the 23rd the pains returned strongly, and at 5 A.M. a dead child was born, the placenta following at once, and without any hæmorrhage whatever. The patient was left in a state of collapse, gasping for breath, and with a very irregular and almost uncountable pulse. Ether and digitalis were administered hypodermically, as well as brandy and champagne by the mouth, and by 7 A.M. she had distinctly improved (breathing laboured and rapid, pulse 140, small and compressible, temp. 99·5° F.). In the afternoon extreme restlessness came on, and by midnight there was some delirium, with screaming and attempts to get out of bed. In lucid intervals she recognised those around her, and complained of great pain in the abdomen (no tenderness). At 1 A.M. on the 24th the ex-

treme restlessness, coupled with her exhausted condition and irregular and uncountable pulse, seemed to augur death within an hour or two, and a hypodermic injection was given (morphia gr. $\frac{1}{6}$, atropine gr. $\frac{1}{120}$, hyoscine gr. $\frac{1}{100}$, and digitaline gr. $\frac{1}{100}$). This produced within fifteen minutes deep and quiet sleep, which lasted, with intervals for being fed and stimulated by mouth and rectum, for ten or twelve hours. At 4 P.M. the pulse was slightly better, but the cardiac impulse was impalpable, and a loud blowing systolic murmur was heard at the apex. The pupils were moderately dilated, and reacted well to light. The tongue was clean and fairly moist. The temperature was 101° F. Next day (25th) the temperature again fell to normal, the general condition remaining unaltered, while nourishment and stimulant were well taken. In spite of this, and of the fact that a fair amount of sleep was obtained, the general exhaustion rather increased, and in the afternoon of the 26th fæces and urine were passed unconsciously, and there was a good deal of wandering delirium. The pulse varied between 120 and 140. On the 27th the condition was the same; and again on the morning of the 28th, when the temperature was 99° and the pulse 130, small and easily obliterated. Shortly after twelve (noon) she rose in bed, crying, "Oh, what a pain!" and fell back gasping and pulseless. Ether was injected, but within five minutes she was dead.

Five hours after death the abdomen was opened, and the specimens we have referred to were removed. The peritoneum was healthy, there was neither fluid nor lymph in its cavity, nor were any organs found glued together. The uterus was firmly contracted, and felt like a cricket-ball. The liver was decidedly enlarged, and projected fully 1½ inches below the costal arch, while the left lobe extended to the ribs of the left side, thus somewhat depressing the spleen; it was firm and smooth, without irregularities, and rather pale in colour. The gall-bladder was unfortunately forgotten in the hurry to get the examination quickly over. The pancreas was normal in size, but very firm and tough, almost like a piece of india-rubber, but with a somewhat gritty feeling. The kidneys were normal in size, the capsules stripped easily, and the surface was finely irregular. No enlarged lymph-glands were found.

The spleen was much enlarged, weighing almost 2 lbs., and measuring 6½ × 5 inches, being 12 inches in circumference at the middle. This enlargement was symmetrical,

the shape being preserved. The organ was extremely firm and of a dark purple-red, the capsule greatly thickened, and presenting at the upper extremity a large cartilaginous patch of old perisplenitis. There had been no adhesion to any other organ. On section it was firm and dark red, and from the capsule greatly thickened trabeculæ extended through the substance. There were no infarcts to be found, and the Malpighian corpuscles were not prominent, being apparently smaller than usual; there was certainly nothing resembling the "suet-like" appearance of these as seen in lymphadenoma.

Microscopic examination.—Spleen: There is great thickening of the capsule and trabeculæ, and all the tissue is engorged with blood-cells. Here and there are irregular patches, consisting almost entirely of red blood-corpuscles crowded together, evidently minute hæmorrhages. The meshes of the reticulum are also thicker than normal, while the venous sinuses are somewhat dilated. Several apparently normal Malpighian corpuscles are to be seen, but not so many as in a healthy spleen, while some seem to have undergone a process of sclerosis, being converted into small round masses of fibrous tissue. The central arteriole has become obliterated in these; while in others, where the process is not so far advanced, the lumen of the vessel is much contracted and the walls thickened. There is no deposit of pigment round these altered Malpighian corpuscles, but here and there through the section a few minute granules having a golden-brown colour may be seen, lying apparently free in the interstices of the reticulum. The blood and lymphoid cells appear normal. There is no lardaceous reaction.

Liver: The lobules are not mapped out distinctly, nor is there any apparent increase of connective tissue. The capillaries are much dilated. In a considerable number of the liver-cells are fat-globules, and the majority of those not so altered contain a large quantity of golden-brown pigment, though in some parts of the section cells containing both are to be seen. There are very few unaltered liver-cells to be found.

Kidney: The renal vessels show some thickening of their walls, as do also the capsules of Bowman here and there, and at one or two points there is considerable fibrous change. The epithelium appears healthy on the whole.

Pancreas: Everywhere throughout the section there is to be seen a great increase of interstitial material; the periacinar

lymph-spaces are somewhat dilated. The glandular epithelium appears perfectly normal.

Lymph-glands: One examined microscopically appears quite healthy.

Turning now to the other cases, we will deal first with the late Mrs. T.'s two sons, N. and R., whose spleens in 1890 projected, in each case, 2½ inches beyond the ribs. They were born in 1880 and 1881 respectively, and have never been strong. For the last three or four years they have been taking arsenic and iron steadily, and while their general health has improved, it is more especially to be noted that they have been much more free from febrile attacks, N. having had only two, and R. only one during the past twelve months. In spite of this their spleens have increased in size, and now (January, 1893) each projects for 3¾ inches beyond the costal arch.

In neither case is the liver enlarged. During the course of a febrile attack (in the case of N.), which apparently resulted from a slight chill, the boy showed no symptoms beyond those common to feverish conditions generally, and though the spleen enlarged to the extent of projecting for 4½ inches it was not tender. A faint mitral systolic murmur was developed, which disappeared as the fever subsided. The urine was clear, of a deep amber colour; it presented a very fine and persistent froth on the surface, and deposited ¾ inch of amorphous and knife-rest phosphates. The reaction was faintly acid, the sp. gr. 1024, and there was neither albumen nor sugar. An opportunity was taken to count the blood-corpuscles, but as it was getting dusk the hæmoglobin was not estimated.

Red corpuscles	3,150,000
White „	5,000

Directing our attention next to the case of A. P., jun., the uncle of the two boys N. and R., a brother of the deceased lady, Mrs. T., we shall find some points worthy of record.

His history and condition were fully described in our previous paper, and it will suffice now to recall the facts that he was not born till two years after his mother was known to have a large spleen, and that his own was palpable when about four years old.

His health during the past three years has varied very much, and while he has had fewer of the "attacks" previously described he suffered in the early months of 1892 from

a severe attack of inflammation of, and effusion into, the right pleura. He was very ill, and his temperature frequently ran up to over 105° F. In spite of strong counter-irritant measures the condition persisted for some weeks, but cleared up after a few ounces of clear serum were drawn off. Since then this patient has become an almost hopeless victim to alcohol, and it has been too obvious to escape notice that there is less tendency to suffer from chills when he is taking large quantities of spirits. His spleen remains *in statu quo*, and his general physical condition is not obviously altered. His complection is dark sallow, and this tends to mask his really anæmic state. It was owing to the absence of obvious pallor that he was noted in 1890 as being "free from anæmia," but two examinations of the blood made last year gave the following results:

March, 1892.—	Red corpuscles . .	3,820,000
	White „ . .	12,000
	Hæmoglobin . .	50 per cent.
October, 1892.—	Red corpuscles . .	3,300,000
	White „ . .	16,000
	Hæmoglobin . .	60 per cent.

The first examination was made while suffering from pleurisy, and the latter when fairly well and out of doors every day, and this probably accounts for the actual and relative increase of hæmoglobin in the latter case. A. P., jun., has been found since our last paper was written to suffer from intermittent attacks of albuminuria, but no blood or casts have been found. The urea was estimated last autumn for five periods of twenty-four hours each when he was confined to his room by a slight accident. The average quantity per day was 340 grains. No albumen was being passed at that time. The urine now seldom contains urates or shows deep pigmentation suggesting the presence of bile. The febrile attacks seem for the present to be in abeyance; this often noticed condition of the urine has disappeared with them. Had this not been so, our intention was to have made a fuller examination of the urinary pigments to see if some colouring matter other than bile did not account for a part at least of the deep colour.

Turning next to A. P., jun.'s, daughter A., a child of ten: she is a big girl for her age, well nourished, of a lively disposition, and active both in mind and body. She is distinctly sallow, but not strikingly anæmic, though a careful examination of the nails and eyelids reveals a paler tint than is natural.

When her blood was examined, however, the following result was obtained:

October, 1892.—Red corpuscles	.	3,800,000
White „	.	20,000
Hæmoglobin	.	60 per cent.

Her spleen in 1890 projected for 2 inches below the ribs; it now projects for 2½ inches. She has no marked splenic symptoms, but occasionally complains of a pain in her left side, which always means, her mother says, that she will be out of sorts for a day or two. Her younger sister, now aged five, is decidedly sallow, but her spleen is not palpable.

Having now completed our record, it remains for us to consider how far we are justified in modifying our previous estimate of the true nature of these cases. That estimate was that leucocythæmia and Hodgkin's disease being excluded, and syphilis and rickets being in the same category, or at any rate excludable as causes, any one of our cases seen singly would, though anomalous, probably be regarded by most medical men as malarial; and, further, that the series were either examples of a true hereditary malarial taint (a view which we did not favour), or else that we were dealing with something wholly different of which we practically knew nothing. The paper elicited but little discussion, and no opinion was hazarded by any member of this Society.

We would point out that since 1890 we have become possessed of further knowledge relating both to the cases and to the functions of the spleen: two points only demand notice now. Firstly, we have found that all of our patients are really the subjects of a pronounced corpuscular anæmia, and no doubt can be entertained that the splenic disease is accountable for this. Secondly, the description we have given of the last illness of Mrs. T., and of the pathological appearances discovered, will, we think, be found, if read in the light of recent knowledge respecting the functions of the spleen,* to point to her death being really due to a rapidly progressing anæmia, dependent upon an active hæmolysis of splenic origin. We consider that the "attacks" which A. P., jun., has so often suffered from, accompanied by fever, engorgement of spleen and liver, and highly coloured urine, also point, whether this pigmentation be due to bile or not, to short periods of active destruction of red blood-corpuscles.

Having briefly alluded to these points, we may proceed to

* Hunter, "Lectures on the Physiology and Pathology of Blood Destruction," *Lancet*, vol. ii, 1892, p. 1209, *et seq.*

state the view which we have been led to adopt; and in the first instance we will say that in our opinion the idea of the cases being malarial may be definitely excluded. Their recent history does not favour that view; several very careful examinations of the blood have failed to show pigment granules, and the pathological report which we have given lends no encouragement to the idea.

We are thrown back, then, on the unknown, or upon finding some likeness to the group of anomalous anæmias accompanied by enlarged spleens, but not by leucocytosis or glandular enlargements which have from time to time been described. There are numerous records of such cases occurring in children, but as rickets or syphilis is probably accountable for the greater number of these, no notice will be taken of them. Several cases also have been described from time to time under the name of "splenic anæmia," but most of the records are so incomplete and leave so much doubt as to the actual conditions present, that we have looked upon the majority as irrelevant. A careful search through the literature of our own and other countries has, however, resulted in our finding a limited number of cases which, though lacking the hereditary element so noticeable in our own, and though in many respects differing from each other, present with ours many cardinal points in common. We may refer to the three cases described by Bauti* as "Anæmia Splenica," and the one by Bruhl† as "Splenomégalie primitive," as furnishing perhaps the most complete records. All of those cases present hypertrophy of the spleen without glandular enlargements, together with a globular anæmia without leucocytosis. All, too, have run a somewhat chronic course which has in many cases extended over a number of years, and in all those in which the excretion of urea has been determined this has been found to be below the average. In many cases there have been febrile exacerbations, and in many (including one of our own) fits of epistaxis. Pathological records have been obtained in only a few instances, but what results there are, though differing in some points, tend rather to cement the series than to throw it into discord.

It will be noted that in each of the cases making up this group we have to do with some disease of the hæmopoietic system occupying a position midway between leucocythæmia

* *Dell, Anæmia Splenica.*
† *Archives générales de Médecine*, vols. i and ii, 1891.

and lymphadenoma, having certain points in common with both, but being quite distinct from either. Whether we are dealing with different manifestations of a single malady, or whether we have to do with a group of allied disorders, we are not prepared to say. We would, however, point out that our own cases, which are evidently all examples of the same disease, have shown very great differences in their clinical history; and, further, that it is possible for near relatives of some of the cases alluded to to suffer unknown from a similar condition; cases such as ours may certainly run on for years without producing any symptoms, and when seen by a medical practitioner their pecular nature is not appreciated without considerable investigation. Finally, our opinion is that, for temporary purposes at least, it may be well to look upon the family factor which enters into our own cases as not necessarily implying a radical distinction, and to group the whole series together; and we would suggest that the name "chronic splenic cachexia" is more properly applicable than any of those which have been employed. We wish it to be understood that we have entered very superficially into the consideration of this subject, as it would be out of place to trespass upon the time of this Society with speculative matter which may or may not prove to be relevant. Should we see reason to pursue the subject further, we shall hope, with the Society's permission, to deal with it at greater length elsewhere.

XXXV.—*Case of Psoas Abscesses, fatal through Renal Complications.* By F. Lucas Benham, M.D. *Read April* 28, 1893.

W. H., a boy æt. 8. Father and mother, and a brother rather older than himself, were all alive and healthy.

He was first seen by me in the beginning of August, 1886. He was suffering from an abscess in the left buttock, which had been slowly forming, and had attained some size, but he had been able to get about in spite of it till quite recently. No injury or any other cause could be assigned to produce it. At first the origin of the abscess was not quite manifest; it was opened, and a large quantity of pus escaped. It became evident, however, before long, that it came (passing through the sacro-sciatic notch) from the spine, the disease affecting the lumbar vertebræ.

Later on abscesses developed and burst in both groins and the right hip; altogether there were five sinuses, constantly discharging more or less for a long time.

The boy was soon sent into the Victoria Hospital for Children, and afterwards to the Sea Bathing Infirmary at Margate; but no surgical treatment was resorted to besides continuous rest in the horizontal position, and he returned home in course of time with the disease progressing.

In the summer of 1887 I asked Mr. Silcock to see him, in order to see if it would be possible to apply a Sayre's plaster-of-Paris jacket. This treatment was carried out forthwith at St. Mary's Hospital, and proved very successful, as in consequence the boy was soon able to get about. He wore the jacket, which occasionally had to be renewed, continually for nearly five years, *i. e.* until the summer of 1892, by which time the spine had completely healed, the sinuses had all dried up, and he could walk and run about with ease and without fatigue; and in the autumn, after a few weeks in the country, he had fully regained flesh, had a very good appetite, and looked well and strong.

But meanwhile he had not been altogether free from other troubles. In July, 1889, he developed some degree of dropsy, there being œdema of the lower extremities. The urine was pale and contained albumen; and I ascribed the symptoms to amyloid disease of the kidneys resulting from prolonged suppuration. Under treatment the

dropsy disappeared in two to three months, and never returned. In 1890 his mother complained to me also that he had acquired the habit of wetting his bed at night, and this habit continued, with intermissions, for the rest of his life.

For some time I could not explain this, and no treatment seemed of much avail to check it; but, gradually, symptoms developed which showed that there was more disease of the kidneys than I had hitherto suspected, for presently mucus and pus were found in the urine, though not always; also small pieces of gravel were occasionally passed; but there was never any hæmaturia, as far as I know.

Early in 1891 a small flattened smooth ovoid calculus was brought to me that he had passed, without renal colic or other difficulty; and in the summer a similar but rather larger one also descended into the bladder and obstructed the passage of urine by sticking in the urethra near to the meatus; it had to be removed under an anæsthetic.

No further trouble of the sort happened until the end of July, 1892, when after he had been passing urine containing a good deal of mucus he had an attack of renal colic on the left side. There were vomiting and diminished secretion of urine; and on examining the region of the kidney, I was surprised to find a large tense rounded tumour there; for it seemed impossible for the kidney to become so much distended with a single occurrence of obstruction of short duration. Suspecting that the obstruction might be due to a plug of mucus in the ureter, I administered small doses of turpentine; and very soon the obstruction gave way, a large quantity of mucus was passed, containing some tough mucus, but no calculus, the diuresis continuing for a few days; and the renal tumour subsided so as to be almost imperceptible.

After this very little of importance took place. For some time mucus and pus continued to be passed, and now and then a little calculous matter.

The patient had regained so much health and strength that I seldom saw him until January 5, 1893, when I found that another attack of left renal colic had set in the day before and laid him up. There was vomiting at first, which abated and was succeeded by anorexia; very considerable pain, which was relieved by hot baths and fomentations; a large tumour in the region of the left kidney, as before, but this time there was almost complete suppression of urine, only a few ounces being passed from the 4th to the 7th of January. He was said to be rather delirious each night, but when I saw

him in the daytime of the 5th, 6th, and 7th he was quite conscious and his mind was quite clear, and he did not appear to be in immediate danger. On the 7th, however, he complained of feeling faint, and died suddenly that afternoon.

A *post-mortem* examination was made next day, seventeen hours after death. Body well nourished. Rigor mortis marked in all limbs.

Lungs quite healthy. No consolidation or pleuritic adhesions.

Heart healthy. Right cavities full of firm, partly decolourised clot.

Liver much enlarged, firm and hard; on section showed the glistening surface of amyloid change.

Spleen also enlarged and amyloid.

Bladder empty, firmly contracted; no calculus.

Left kidney enormously enlarged, the size and shape of a large cocoa-nut. It was almost reduced to the condition of a thick bag distended by blood-stained urine. Capsule easily stripped. Surface smooth, very pale, but here and there intensely congested. Pelvis and ureter dilated, thickened, and deeply congested. About three inches down, the duct was blocked by a firm mass of gritty, inspissated mucus. Internally the configuration of the kidney was quite altered into a series of communicating cysts or sacculi, into which the shrunken and flattened pyramids projected; in places no kidney tissue at all was found, but only thick fibrous tissue. The sacculi contained some calculi, one as large as a walnut, two or three smaller ones, and much inspissated mucus, gritty with calculous fragments.

There was a good deal of tough cicatricial tissue, with enlarged lymphatic glands, over the left psoas, which involved the ureter, binding it down tightly by the side of the spine, and bending it sharply backwards, forming an angle or kink in its course, where the plug of mucus was arrested. It required rather careful dissection to trace it here. Above this angle the duct was considerably dilated; below this it was also dilated and thickened, but less so, and was pervious as far as the bladder.

Right kidney.—On attempting to remove this organ its capsule and coverings were so thin as to be punctured and give way, giving exit to one or two ounces of purulent mucus. The organ was slightly enlarged; cortex smooth, pale, flattened; from within, the gland seemed little more than a large abscess containing about four ounces of greenish-yellow

muco-pus, partly inspissated, partly gelatinous (closely resembling the pulp of grapes), and somewhat gritty. Ureter normal. No connection was traced between the pyonephrosis and any spinal abscess, which seemed to have all healed up.

The calculus was found, on chemical analysis, to consist of urate of ammonium and phosphate of calcium, with traces of uric acid.

Weight of the large calculus, 2¾ drachms.

Remarks.—There are several points of interest about this case.

1. The successful surgical treatment, by means of Sayre's jacket, of spinal disease situated so low down in the back.

2. The difficulty of diagnosis of the renal mischief when it first appeared. When mucus and pus began to appear in the urine I was inclined to think that one of the abscesses must have opened into the kidney on that side, or that one or both of the kidneys had become the seat of scrofulous deposit. But when calculi came to be passed I considered that there was most probably calculous pyelitis, independent of the spinal disease. The plaster-of-Paris jacket prevented proper physical examination of the abdomen, so that a renal tumour, if it existed, was overlooked, and as the tumour which was noted during the attack of obstruction in July, 1892, subsided directly afterwards, I looked on it as a temporary product, and did not recognise any permanent obstruction of the ureter.

3. The cause of this obstruction was shown plainly by the necropsy to be that the ureter was entangled in cicatricial tissue remaining from the psoas abscess. This condition is, I believe, very rare if not unique. I cannot find any record of a similar case, though it is hard to say why it should not happen oftener. Perhaps the extensive area of the abscesses in this case, which burrowed and discharged in so many directions, promoted the liability to extensive cicatrisation with attendant contraction.

4. I am not sure how the disease of the right kidney originated. There might perhaps have been some slight pressure below on the ureter, causing gradual dilatation of the pelvis of the kidney, but as the duct at its origin looked healthy I did not trace its course to the bladder.

5. The contents of this kidney were very peculiar. Though it seemed to consist in part of thick mucus and pus, the greater portion was a clear soft gelatinous substance, perhaps of the nature of the colloid material described by Dr. Dickin-

son in a case of hydronephrosis, reported in *Trans. Path. Society,* vol. xiii.

6. The reason why the attack of colic in January, 1893, proved fatal, whereas that of the previous July was easily recovered from, is probably because the right kidney had become disorganised in the meantime. Death took place principally, I consider, from uræmia, yet it is unusual for death to take place so quickly from suppression of urine, even if complete, and sudden death in such conditions is very uncommon.

XXXVI.—*On a bloodless method of removing the Tongue.* By CHRISTOPHER HEATH. *Read April* 28, 1893.

I WISH to bring before the members of the Clinical Society a method of removing one half or the whole of the tongue, which I have adopted for more than twelve months with advantage. In common with most surgeons I have long abandoned the use of the *écraseur* in tongue operations, and ordinarily have divided the organ down the middle with a straight blunt-pointed bistoury and the finger, and the sublingual tissues with scissors. When one half of the tongue is thoroughly isolated and the extent of the epithelioma ascertained, the healthy tissues have been divided with scissors, and the lingual artery picked up with forceps when, or even before, it was divided. Now if one has a good light, and a good assistant, who will be sure to catch the artery skilfully, everything will probably go straight, and the operation may be completed in a very few minutes with little or no loss of blood. But accidents happen even to the best assistants, and every now and again I have had to pause in my operation in order to hook up the hyoid bone with the forefinger, so as to arrest the hæmorrhage, whilst I picked up the artery myself. In order to get over this difficulty I have now provided myself with a large pair of Spencer Wells' angular forceps, the blades being 2 inches and the handle 6 inches in length.

FIG. 6.

Having isolated one half of the tongue, and ascertained the extent of the disease, I divide the healthy mucous membrane transversely with the bistoury, and tear through the muscular fibres with the finger to some depth. Slipping one blade of the forceps beneath the tongue, I bring the other blade into

the transverse cut already made, and by forcibly closing them I grasp the lingual vessels, with a few muscular fibres, firmly in the forceps. With the scissors I then cut off the half of the tongue close to the forceps, and, if necessary, proceed to deal similarly with the opposite side. Then, provided I am satisfied with the healthy appearance of the section, I pass a hempen ligature behind the forceps, and tie as tightly as possible the structures held in this instrument with a double knot. Lastly, remove the forceps and cut the ends of the ligature short.

In one very extensive case of epithelioma of the entire tongue I was not satisfied with the section, and found no difficulty in making a second transverse cut further back, and in applying the forceps a second time. I think it right to state that in one case I had a little secondary hæmorrhage, probably from not having tied the ligature sufficiently tight or from having included a little too much muscle.

XXXVII.—*A case of Perforating Gastric Ulcer treated by abdominal section.* By W. Lee Dickinson, M.B., and Warrington Haward. *Read April* 28, 1893.

Record of case by Dr. Lee Dickinson.—Mary N., æt. 26, a parlourmaid, had suffered from dyspeptic symptoms, sometimes severe, without hæmatemesis, for more than two years before her admission into St. George's Hospital. She was able to perform her ordinary duties till the afternoon of December 11, 1892, though the dyspeptic pains had been worse than usual during the previous two days. She walked out in the evening, and partook of a light supper before going to bed. On December 12, at 12.30 A.M., she was seized by sudden agonising pain "under the heart," so that she rolled out of bed. About an hour later she was seen by Dr. Des Vœux, who diagnosed perforation of the stomach and injected morphia subcutaneously to allay the pain till she could be brought to the hospital, which was at 11 A.M. the same day.

When examined in the ward she was found to be a plump young woman, less anæmic than most subjects of gastric ulcer, gravely ill with the symptoms of acute peritonitis. She was vomiting bilious material and was in great pain, referred to the right lower ribs in front, the right shoulder and subclavicular region; with a rigid and full, though not greatly distended abdomen, acutely tender in the epigastrium. There seemed to be some compression of the base of the left lung, as indicated by partial dulness with deficient entry of air; and the heart's apex was pushed up into the fourth interspace, the heart-sounds being fairly natural.

Dr. Owen, acting for Dr. Cavafy, under whose care the patient had been admitted, called Mr. Haward into consultation, and it was quickly agreed that her life could be saved only by surgery.

At 2.50 P.M. the patient was etherised, and Mr. Haward operated. The abdomen being opened by an incision in the linea alba from just below the ensiform cartilage to just above the umbilicus, a more or less localised collection of turbid fluid was found coming from above the stomach and below the left lobe of the liver, some bubbles of gas escaping

with this fluid. There was lymph in this neighbourhood, but no general peritonitis. A gaping perforation of the stomach was found, of the size of a threepenny piece. Around this perforation, which was obviously the apex of a simple ulcer, the gastric wall was thickened over an area fully as large as the palm of a hand; and by reason of this thickening it was impracticable to invert the gastric wall so as to close the perforation by sutures. Accordingly the stomach was attached by a few stitches to the abdominal wall after the manner of a gastrostomy, and the edges of the perforation were sewn to the upper part of the incision, forming a gastric fistula, and a drainage-tube was passed into the stomach. It was difficult to say exactly on what part of the stomach the perforation was. All that was known definitely was that a considerable amount of rotation of the stomach downwards and forwards had to be exercised before the perforation could be brought into apposition with the laparotomy wound. When the stomach had been thus dealt with the general cavity of the peritoneum was washed out, and the wound was closed, the operation being completed at 5 P.M.

For the first forty-six and a half hours after the operation no food was given, the patient being kept to some extent under the influence of morphia. Then fluid food was given by the rectum, and on December 15 a little peptonised beef-tea was given by the mouth in addition. Feeding by the mouth was proceeded with cautiously at first, but before the end of December she was swallowing a couple of pints of fluids and a little pounded meat in the course of the day, and early in January rectal feeding was discontinued altogether. The wound healed well; the tube in the stomach was removed on December 16, the stitches in the laparotomy wound on December 18, and those in the stomach on December 21. Except for some cutaneous irritation around the fistula, kept up by the escape of a certain amount of food and gastric secretion, the condition of the abdomen gave no anxiety.

On December 15, the third day after the operation, a hard swelling appeared in the place of the right parotid gland, to be followed next day by a similar though less severe condition on the left side of the face. These swellings assumed a considerable size, and after some days pus began to discharge from the ears. Accordingly, as it was evident that the parotids were suppurating, on December 23 an incision was made into each, from which curdy pus oozed out. Syringing these incisions produced a discharge from the ears, showing

that the suppuration had opened into the external auditory meatus.

The swellings gradually subsided, but a little pus continued to discharge from the right parotid till the death of the patient. The parotitis was not septicæmic in its origin—at least, there was no other sign of septicæmia at the time.

The patient was, no doubt, somewhat depressed by the parotitis, which may account for some of the fever shown on her temperature chart; but in the latter part of December a far graver complication made its appearance—she began to cough with some expectoration of pus, and the pulse was never less than 120. On December 31 there were dulness, crepitation, and tubular breathing over both lungs behind—the lower third of the right lung, the lower half of the left. It was hoped that these were merely the indications of hypostatic pneumonia, and the patient was henceforth propped up into a sitting posture as much as possible.

In the course of the next week these physical signs cleared up to a considerable extent, the right lung returning to a comparatively normal condition, some consolidation at the base of the left lung remaining. This improvement was not maintained, and the expectoration became more copious, though never fœtid.

On January 15 the patient's condition had become very serious, and there were dulness, intense tubular breathing, and large metallic râles over the whole of the back of the lower lobe of the left lung.

Having regard to the especial liability of the left pleura and the left lung to be involved in cases of subdiaphragmatic abscess,* and to the possibility of a subdiaphragmatic abscess forming after laparotomy for perforation of the stomach,† it was anxiously considered whether there might be an abscess beneath the diaphragm or at the base of the left lung. At a consultation which was held there was some difference of opinion as to whether the symptoms pointed to some form of chronic pneumonia with fluid in the pleura, possibly purulent, or to abscess in the lung. As, however, the area of dulness continued to increase upwards, it was decided to explore the part.

On January 20, ether being given, Mr. Haward cut down upon the pleura in the tenth interspace and posterior axillary line. No fluid was found here, and neither the finger nor a

* Penrose and Lee Dickinson, *Clin. Soc. Trans.*, vol. xxvi.

† Taylor, *Birmingham Medical Review*, 1888.

director passed further inwards discovered any abscess. While this was being done there was so much collapse that further exploration was impossible.

The immediate effect of the operation passed off, but the state of the patient was more serious than before. The pleura contained air, as shown by a tympanitic percussion note under the clavicle, and two days later friction sounds resembling those of pericarditis were heard over the heart. On the morning of January 24 she called out suddenly that "something had given away," and became cyanosed and pulseless. Partial consciousness was restored by energetic stimulation and inhalation of oxygen, but death occurred about three hours later, on the forty-second day after the first operation.

The immediate effect of the first operation was a fall in the temperature. A rise occurred coincidently with the parotitis, followed by a slight diminution after the incision of the glands. Then, with the appearance of the pulmonary complication, the temperature rose to its highest point, and, with some variations, remained persistently high till death.

The autopsy was made by Dr. Rolleston. The scar of the laparotomy wound was firm and healthy, except for a little suppuration in its upper part. The walls of the fistula leading into the stomach were firm and fibrous, the track was completely shut off from the peritoneal cavity. There was no evidence of general peritonitis having existed, but there were old filamentous adhesions all over the convex surface of the right lobe of the liver, uniting it to the diaphragm, and a small patch of lymph on the peritoneal surface of the right kidney.

The perforation in the stomach was on the anterior surface, near the lesser curvature, and about three inches from the pylorus. The thickening round the perforation observed at the operation had disappeared; the size of the aperture had not altered appreciably. There was no other ulcer or cicatrix. Between the ulcer and the pylorus the stomach was firmly adherent to the liver in the region of the quadrate lobe.

The spleen was adherent to the left leaflet of the diaphragm, but there was no perforation of the diaphragm nor suppuration beneath it.

Between the left leaflet of the diaphragm and the base of the left lung was a circumscribed abscess, filled with about four ounces of non-fœtid pus. The lower lobe of the left lung contained many small purulent cavities, from which a probe readily passed into the diaphragmatic empyema, but

direct communication between the bronchi and the empyema was not made out. The lung tissue around the abscesses was consolidated, grey, and œdematous. There were adhesions between the lower and upper lobes, but the upper lobe was normal, and the rest of the pleura was free from adhesions.

The bronchi and trachea contained pus from the lower lobe of the left lung.

The right lung and pleura were normal, as were also the heart and pericardium.

Remarks by Mr. Haward.—On January 13 of the present year a paper was read before this Society by Dr. F. G. Penrose and Dr. Lee Dickinson on "Abscess beneath the Diaphragm in Connection with Perforating Gastric Ulcer," in which, besides describing the anatomy of such abscesses and the symptoms by which they may be recognised, the authors raised two surgical questions, namely, the best manner of draining the abscess, and the possibility of closing the hole in the stomach wall.

The case now related is another illustration of perforating gastric ulcer and its treatment, and in spite of its fatal end affords very decided encouragement to prompt surgical interference.

In the interesting paper* by Mr. J. W. Taylor of Birmingham, alluded to by Drs. Penrose and Lee Dickinson, it is shown that if a patient with gastric ulcer is seized with symptoms of perforation, and no surgical means are used for her relief, she will probably be dead within twenty-four hours.

There can be no doubt, I think, that this patient would have been no exception to that statement, and that by the prompt opening of the abdomen she was rescued from impending death. The commencing peritonitis was at once stopped; any further escape of the contents of the stomach was prevented, and what had escaped was removed from the peritoneal cavity, and the condition of collapse was quickly recovered from. In fact, after the completion of the operation the condition of the abdomen gave no further anxiety.

But then, on the third day after operation, came that curious complication which has been observed in connection with so many cases of gastric ulcer,—inflammation and suppuration of the parotid glands.†

* *Birmingham Medical Review*, vol. xxiii, p. 155.

† See a paper by Mr. Stephen Paget, *Med. Soc. Proc.*, 1887

This gave rise to much pain and fever; and on both sides, although free external incisions were made, pus was discharged through the auditory meatus—a route which it seems often to take in these cases. After a time, however, this trouble subsided, and it had nearly come to an end before the patient died.

The really serious complication, that which caused the patient's death, was the inflammation and suppuration in the lower part of the left lung and pleura.

This does not appear to have been part of a general septicæmia, but rather a direct conveyance by the lymphatics from the under to the upper surface of the diaphragm of some irritating material which had escaped from the stomach in the interval between the giving way of the ulcer and the opening of the abdomen.

This is evidently what occurs in many cases of subphrenic abscess, there being no general septicæmia, but a local extension of the inflammatory process through the left leaflet of the diaphragm to the pleura above. In seven of the ten cases recorded by Drs. Penrose and Dickinson, there were signs of inflammation, more or less intense, in the lower part of the left pleura or lung.

Cases of perforating ulcer of the stomach may be divided into two classes: one class in which an ulcer, around which no adhesions have taken place, suddenly opens into the cavity of the peritoneum, and gives rise to the acute peritonitis which is rapidly fatal unless treated at once by abdominal section; in this class the ulcer is probably upon the anterior wall of the stomach. The other class includes those cases in which protective adhesions have been formed around the ulcer, and only a slight and intermittent leakage of the contents of the stomach takes place, leading to the formation of a subphrenic abscess, and perhaps a diaphragmatic empyema. In this class the ulcer may be either on the anterior or posterior wall of the stomach.*

It seems to me that there must be a material difference in the surgical treatment of these two classes of cases.

In the first, of which the case related is an example, abdominal section should be performed at the very earliest possible moment after the occurrence of symptoms of perforation; the peritoneal cavity should be washed out with great care, so as to remove everything that has escaped from the stomach;

* Of the cases recorded by Drs. Penrose and Dickinson, in four the perforation was on the posterior wall, in six on the anterior wall.

and an attempt should be made to close the hole in the stomach.

The chance of saving the patient's life will depend greatly upon the promptitude of surgical interference; for every hour that passes after the giving way of the ulcer increases the severity of the collapse, and brings the patient into a condition less able to bear the additional shock of an operation, —and besides this, gives time for the absorption of irritating material which has escaped from the stomach.

This last consideration is of great importance, for it is difficult to explain in the case under consideration the localised empyema just above the part of the diaphragm corresponding to the situation of the ulcer, and the suppuration in the adjacent part of the left lung, except by supposing that some harmful material which had escaped from the stomach was taken up by the lymphatics during the fourteen hours which elapsed before the abdomen was opened.

It is evident, moreover, for the same reasons, that too much care cannot be bestowed upon the cleansing of the peritoneum.

With regard to the surgical treatment of the perforation, it seems to me that the best plan would be to excise the ulcer, sew together the inner coats by a continuous stitch, and then bring the peritoneal surfaces into close apposition over this by Lembert's sutures. In the case here related the infiltration of the stomach wall around the ulcer seemed to make it imprudent to attempt to close the opening by stitches; but I believe such thickening to be exceptional in the cases wherein no adhesions have formed, and at the post-mortem examination it was seen to have almost entirely disappeared.

The incision opening the abdomen should, I think, be made in the middle line and above the umbilicus, as was done in the present case. This gave easy access to the stomach, and allowed a thorough examination of the organ.

In the second class of cases to which I have alluded the ulcerative process is accompanied by a protective inflammation which leads to the formation of adhesions around the ulcer, fixing the stomach to adjacent parts. These adhesions may either be incomplete or may be disturbed, and thus a slight and intermittent escape of fluid and gas may take place, giving rise to the formation of a subphrenic abscess, or it may be to a general peritonitis. In these cases there will have been pain and other signs of local inflammation for

some time before the occurrence of symptoms of perforation or of the formation of subphrenic abscess. Either of these events would call, however, for abdominal section, and the same incision recommended for the first class of cases (*i. e.* between the ensiform cartilage and the umbilicus) would in most instances be the best. But the difficulties attending any attempt to close the ulcer would be much greater in this than in the first class of cases. The fixation of the stomach by adhesions might make it impossible to find or examine the ulcer without a disturbance of the parts, which would not be justifiable.

If, however, the adhesions had completely given way, or a large opening into the general cavity of the peritoneum was found, it would, I think, be right to treat the ulcer by excision and suture; or if that seemed impracticable to attach the margins of the ulcer to the edges of the abdominal wound and thus make a gastric fistula, as was done in the case here related.

If the adhesions were firm and the opening small or inaccessible, it would probably be best to be content with washing out the peritoneum and keeping the stomach at rest by rectal feeding, watching carefully at the same time for any symptoms of subphrenic abscess, a sequence which would not be improbable.

The anatomy and symptoms of subphrenic abscess have been so recently brought before the Society that I will say but little on that subject. Having regard, however, to the great importance of complete drainage of such an abscess, I am inclined to think that, whenever the anatomical limits of the abscess permit, it would be well to have, in addition to the opening in front, a counter-opening in the lower and posterior part of the cavity.

It is notable that in the case here related the local infection spread by the same route that has been so frequently observed in connection with subphrenic abscess, giving rise in the same way to a localised empyema immediately above the diaphragm.

I failed to find this by my exploration of the pleura, the condition of the patient not warranting a prolonged search; but in all such cases the probability of this complication should be borne in mind, and the empyema evacuated as soon as possible.

We are indebted to Mr. F. C. Kempson, Demonstrator of Anatomy in the Medical School of St. George's Hospital, for

the accompanying drawings, showing the relations of the empyema as seen at the post-mortem examination.

FIG. 7. FIG. 8.

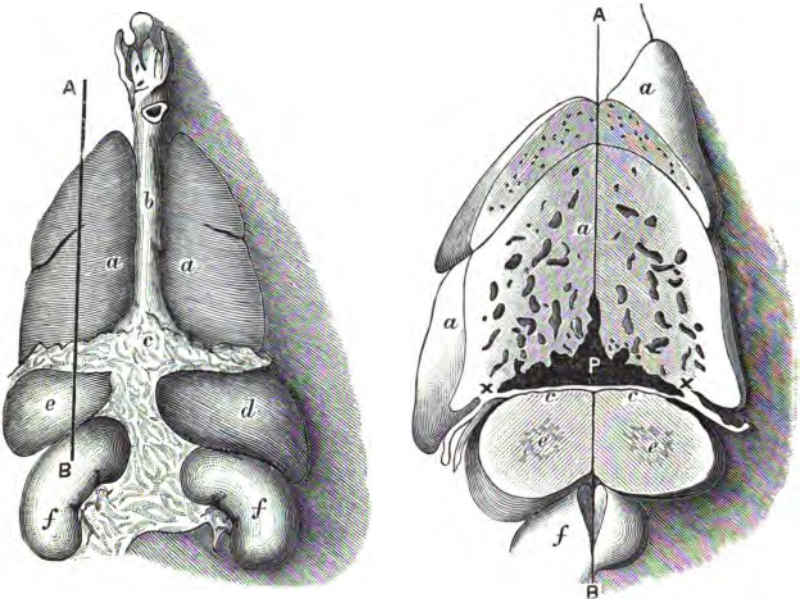

FIG. 7.—Viscera of M. N., as removed from the body and seen from behind. A, B. The line of section through the viscera of the left side. *a, a.* Lungs. *b.* Œsophagus. *c.* Diaphragm. *d.* Liver. *e.* Spleen. *f, f.* Kidneys.

FIG. 8.—Surfaces exposed by section through line A, B. *a, a.* Left lung. *c, c.* Diaphragm adherent to lung at × and to spleen. *e, e.* Spleen. P. Cavity containing pus.

Addendum, July, 1893.

An ultimately successful laparotomy for perforated gastric ulcer has been recently reported by Kriege* (operation by Heusner). The perforation was into the general peritoneal cavity, and it was closed by sutures about seventeen hours after its occurrence. The patient did well at first, but at the end of the fifth week an empyema developed insidiously in the left pleura. This was opened, and six months after the laparatomy the patient was in good health.

* *Berl. klin. Woch.*, December 5, 1892.

Such an operation has been attempted or carried out more than once previously, but without marked success.*

Since this paper was written Mr. Gilford, of Reading, has published a partial success, the patient dying at the end of a month from septicæmia after many complications.†

* Barling, *Brit. Med. Journ.*, January 9, 1892; Parsons, *Dublin Journ. of Med. Sci.*, vol. ii, 1892; Anson, *Lancet*, March 4, 1893.

† *Brit. Med. Journ.*, May 6, 1893.

XXXVIII.—*A case of Pulmonary Abscess communicating with the Posterior Mediastinum.* By Alexander Morison, M.D. *Read May* 12, 1893.

Mrs. W., æt. 32, short, stout, and not known to be suffering from any noteworthy disease, was delivered naturally of her second child on December 4, 1890, and made an uneventful recovery. Towards the end of the same month she had a gumboil, which was not brought to my notice, as she did not wish to direct attention to the fact that she had a nearly complete set of false upper teeth, a fact which she had concealed from her husband for nearly two years by having retained them in her mouth frequently when their condition required their removal. On January 1, 1891, a cough, which she had had for some time, even previous to her accouchement, became more troublesome, and was now for the first time accompanied by an exhalation of a very offensive character. On examination, however, beyond some reddening of the fauces, nothing abnormal was detected, but her pulse became accelerated, and her temperature rose until, on the 6th, it reached 101°, and on the 7th 104°. This continued pyrexia without localisable mischief caused me to investigate her surroundings, and, although the patient was in luxurious circumstances, sewer-gas contamination from a defective drain under the house was discovered. Typhoid fever was consequently suspected; there was, however, no characteristic eruption, and the stools, while they became liquid, retained, as a rule, a normal colour. One circumstance in the case, though difficult to explain at first, proved to be important. The cough was troublesome, and the patient found that on turning on to the left side it became much worse, and a greenish purulent discharge seemed without any effort to well up into her mouth, while the overpowering stench which accompanied it was such as to convert expectoration into retching. Vomiting, however, did not follow, and neither gaseous eructations nor alvine evacuations partook of the offensive odour in question. I therefore suspected that the nauseating material, wherever it came from, lay at the root both of the fever and subsequent sweating. On one occasion, moreover, there was some shivering. Having discovered that the patient had false teeth, very much to her annoyance, I in-

sisted upon their removal, and found they concealed a row of fœtid stumps, embedded in a soft spongy gum tissue, and surrounded by some alveolar suppuration. The temperature soon after reached 105° F., and was, in my opinion, partly emotional, as the patient was apparently quite as anxious that the falseness of her teeth should be concealed from her husband as alarmed about her own condition. The mouth was then thoroughly and continuously cleansed.

On one occasion I found large râles in the bronchial tubes anteriorly, especially to the right of the sternum. Next day all such had disappeared.

On January 17 I found comparative dulness at the right apex, with large crepitations both above and below the clavicle, and also in the upper scapular region posteriorly. On the evening of the same day these signs had vanished.

On January 18 percussion over the right clavicle was slightly impaired, as also was vocal resonance at the right apex, and the only moist sound was a fine crepitation immediately below the clavicle at its outer portion. Cough and expectoration were now much less, and the material expectorated no longer so offensive and nauseating; diarrhœa ceased, the patient felt much better, the temperature was normal, and perspiration no longer excessive.

This may be said to have been her condition on January 24. At 3 P.M. on that day her chest is noted as "clear," and "cough less." At 8 P.M. on the same day, however, the cough became more troublesome, but there was no expectoration. On the 25th the temperature was still normal, but on the 26th it rose very slightly; on the 27th rather more, when the cough was troublesome, and there was some mucopurulent expectoration, and on the 28th the temperature stood at 101°; on the 31st it was 101·8°, the cough troublesome, but the chest clear, and on February 1 the temperature was still 101·8°, there was a return of the offensive discharge with crepitation at the right apex, and next day (February 2) the temperature again fell to normal, the expectoration became less offensive, the crepitation less marked, and while the percussion note was doubtful, there was an increase of vocal resonance at the right apex. The patient was also slightly hoarse. The temperature remained normal until the 5th of February, when the right apex is noted as clear, and all offensive expectoration as gone. This was, however, but the prelude to a return of fever. At 2 P.M. on the 5th the temperature stood at 99°, slowly rose to 100° on the

FIG. 9

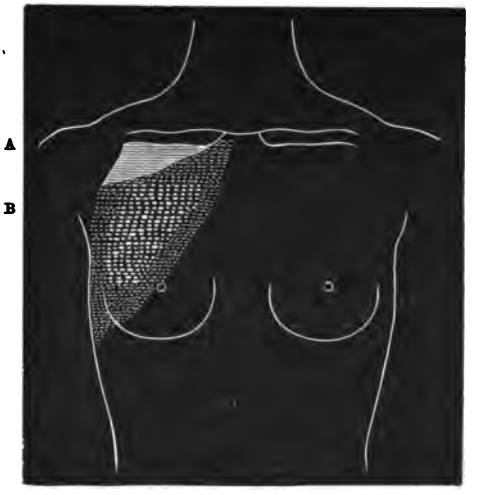

A. Dulness not constant at first. B. Large and small crepitations.

FIG. 10.

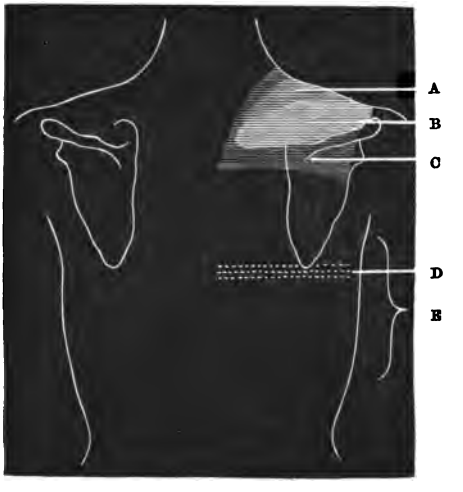

A to C. Dulness with bronchophony. B. Amphoric breathing. D. Zone of crepitation. E. Region of pleural friction.

8th, reached 101° on the 9th, and on the 12th was 104°, when the expectoration is noted as offensive, and the patient complained of pain in the right side from front to back. There were no signs of lung or pleural inflammation on auscultation at this date. Next day the temperature had fallen to 101·2°, but again rose to 103·2°, falling on the 14th to 101°, and rising suddenly to 104·6°, when the expectoration is still noted as offensive, and there was also observed a fine crepitation at the right apex posteriorly, below the spine of the scapula. The temperature then fell on the 14th to 100·6° and on the 15th to 99·2°, but rose on the same evening to 103°, when the offensive expectoration is noted as being less. There was some crepitation still at the right apex posteriorly, but the respiratory murmur had distinctly diminished in the same position. The evidence now clearly pointed to an abscess on the posterior aspect of the right lung apex, which periodically discharged through the lung, and I suggested to the relatives of the patient the advisability of operative interference as soon as the accessibility of the abscess was manifest.

On February 16 Dr. Broadbent was good enough to see the case with me, and detected, in addition to dulness at the right apex posteriorly, a sense of resistance on pressure in the supra-scapular region. He agreed that the evidence pointed to abscess, and surmised that the abscess was extra-pulmonary and had burst into the lung. Operative interference at this date was taken into consideration, but postponed on account of some uncertainty as to the precise localisation of the abscess.

The temperature gradually fell to 99·2° on the 19th, and in the interval the physical signs recorded are—some pleuritic friction on the right side, large râles at the right base posteriorly, and bronchial breathing becoming amphoric in character at the right posterior apex. There was no accumulation of fluid in the pleural cavity. The left lung was normal. The temperature then fluctuated until the 23rd, when it rose to a higher level, when the recurrence of the offensive expectoration is also noted, and instant relief therewith of a tenderness detected the day before in the supra-scapular region. The patient now complained of pain on coughing, in the right breast, and there was some pleuritic friction on this side.

On the 28th of February I have the following note of the patient's condition:—pulse 144; respiration 24; temp. 103·2°;

dulness to point of scapula posteriorly; bronchophony, breathing almost cavernous in the supra-scapular region; dulness less marked laterally than posteriorly at the same level; some crepitation below the point of the scapula; base of the lung posteriorly clear; anteriorly bronchophony at the right apex, and a fine crepitation to the level of the fifth rib; pain on pressure to the right of the scapula.

It was now quite clear that the patient was either to be allowed to die without interference, or that a surgical operation, already delayed, perhaps, too long, should take place at once. I asked Mr. Bryant to see the case with me with this object, which he did, and agreed to operate next day. This he accordingly did on March 1st, 1891.

The patient having been anæsthetised by Dr. Ostlere, an incision was made passing from above downwards and slightly inwards towards the spine from the level of the first to that of the fifth dorsal spinous process, at a distance of 1½ inches

FIG. 11.

Showing site of the operation wound.

from the middle line of the vertebral column. The skin and superficial fascia, in which there was a considerable deposit of fat, having been cut through, the deep fascia and first layer of muscle (trapezius) were divided. Vessels having been twisted and the wound sponged, the divided muscle was

pushed aside towards and from the spine, and the oblique fibres and tendinous glisten of the rhomboid was displayed. This was next divided, vessels twisted, and parts pushed aside as before by the finger and with a blunt flat bone elevator. The finger could now feel the transverse processes of the vertebræ, the angle of the ribs, and the posterior portion of the intercostal spaces. Finding that more room was now desirable, Mr. Bryant divided the tissues at right angles to, and from about the centre of the first incision, outwards towards the scapula, and down to the bottom of the wound. After arresting bleeding and sponging the wound, two intercostal spaces (the second and third) could now be seen, and Mr. Bryant elected to pierce the lower of these. A director was pushed through obliquely outwards and forwards. There was some venous oozing, and presently a few shreds of pus. The opening was enlarged by separating the blades of a dressing forceps passed through it, when more pus escaped. Altogether a good teaspoonful was evacuated, but no more. The opening was gently enlarged by passing the point of the finger through the intercostal space. It could be felt to enter a space or cavity. The blood in the intercostal opening was seen to be influenced by the respiratory movements, but whether exclusively by pulmonary or costal movement could not be positively affirmed. A drainage tube was passed just sufficiently through the orifice to be caught, the wound stitched, and dusted with iodol and boric acid in equal parts, and covered with corrosive sublimate wool.

Until the 9th of March the patient's condition had on the whole improved; the chest signs remained much the same; discharge escaped through the tube and from the surface of the wound. The latter became somewhat tense, and the stitches had to be removed; there was some erythema of neighbouring skin, and it was noted that air escaped through the tube on expiration and on coughing. On March 4 the temperature ranged from 99·2° to 100°, the pulse averaged 130, and the respiration 24. The cough was chiefly troublesome when the patient was turned on to the left side, and then the expectoration also flowed up, as she expressed it, "like a stream," and was most offensive. It was greenish and purulent in character. The back was stained blue from the corrosive wool; the wound looked dry and inactive; there was no interstitial emphysema, but air and pus jerked out of the tube on coughing. The physical signs in the chest were as follows: anteriorly, from the apex to the fifth or sixth rib,

small crepitation; resonance much the same as that of the left side, which was normal; pleural friction below the breast and laterally. Posteriorly, dulness on percussion down to the point of the scapula. Respiration decidedly diminished in the suprascapular region, and bronchophonic over the blade of the scapula; the base of the right lung was clear and without pleural friction.

Next day there was a dusky discoloration round the site of the two lowest stitches, but the incision, except where it gave exit to the drainage tube, had, in great part, healed by first intention. Air and pus jerked through the tube as before on coughing; expectoration which escaped when the patient changed her position was most offensive.

From the evening of the 6th of March until 2 P.M. on the 9th the temperature varied from normal, and even sub-normal (97·2°), to 99°, the pulse from 114 to 122, and the respirations from 24 to 36. The patient was conscious, and while the situation was naturally very grave, her condition was such as to justify some hope of recovery if the abscess could be satisfactorily drained. At 5.20 P.M. on the 9th, however, the temperature suddenly rose to 101·6°, and she had her first decided and unmistakable rigor; at 6.20 the temperature was 102·4°, and the patient passed into a condition of stupor, with rapidly failing circulation, from which she never rallied. At 4.30 P.M. on the 10th the rectal temperature was 97·8°, and the patient died the same night. The wound, which had apparently united, gradually opened, and at the time of her death was an unhealthy gaping sore. There was no *post-mortem* examination of the body. The extent, precise situation, and origin of the diseased conditions can therefore only be conjectured. The clinical history of the case, however, contains much which may contribute to a sufficiently satisfactory explanation of its chief features. The first question which presents itself is, "Did the abscess arise in a small infarct which had reached the periphery of the lung by way of the pulmonary artery, and thus cause suppuration, communicating at once with the cavity of a limiting pleuritis, and with the bronchial tubes? or, did it originate in a limited extra-pulmonary suppuration in the cellular or glandular tissue of the posterior mediastinum, and burst into the lung?" There is a good deal to be said for both views, and even now, although inclined to favour a pulmonary thrombotic origin, I cannot say I feel convinced in my own mind on the subject.

Previous to her accouchement on December 4, 1890, the patient evinced no evidence of illness, except a slight cough, to which neither she nor others attached importance. The accouchement itself was normal, and the puerperium free from any clinical complications. The weather was very cold at the time, and the patient remained in her room for a longer time than was absolutely necessary from her condition. A fortnight after the birth of her child she felt as well as possible under the circumstances. About that time the cough, to which little importance was attached as it was not very troublesome and was unattended by constitutional disturbance, became worse, and by the end of the month was very troublesome, until, as I have stated, on the 1st of January, 1891, it was accompanied by an offensive exhalation, at first perceptible only to the patient, and later to others also. All this would be compatible with the transportation and infarction of a small uterine or other thrombus in an apparently aseptic case. On the other hand, the concealed reservoir of dental nastiness to which I have referred cannot be lost sight of, nor the possibility of glandular or other infection from this source. One would, however, have expected, had this been the cause, that some implication, however slight, of the intervening absorbent track would at one time or another have shown itself. There was absolutely no such implication. These considerations render it more probable to my mind that the former theory is correct, unless one assumes the existence of a pre-existing small limited empyema or abscess at the apex of the right lung posteriorly, of which no one had any suspicion, and which gave rise to no symptoms, unless the cough I have mentioned was due to it. There was no history of previous disease which could have had such a consequence.

A small infarction, on the other hand, which could conceivably be derived either from a small thrombus from veins implicated in the peri-odontal inflammation, or from the uterine sinuses, could have produced cough without its being possible to localise the causal mischief, and could also have given rise to an areola of inflammation with limiting adhesion of the pleura in its neighbourhood, suppuration and erosion into a small extrapulmonary cavity, and escape along the bronchial tubes; that the double communication existed, was proved by auscultation, the character of the expectoration, the evacuation of pus, although in very small quantities on operation, the issue of air and pus through the drainage-tube on expiration and on coughing, and the identity in odour between

the foul expectoration and the offensive discharge through the surgical wound. The comparatively limited implication of lung was, moreover, shown in the first instance by a corresponding quietude in breathing, and later, when physical signs became more manifest, the rate of respiration corresponded rather with the general constitutional disturbance than with a serious involvement of lung tissue.

A third possibility which occurred to me at first in presence of the fœtid expectoration, and the occasional presence of large crepitation in the bronchi, was that septic matter had entered the bronchial tubes from the foul secretions of the mouth. Dr. Hilton Fagge quotes Volkmann, as suggesting that septic matters may find their way into the lung, and cause gangrene by dropping from the Eustachian tube into the pharynx in cases of otorrhœa (*Pract. of Med.*, vol. i, p. 909). It is, however, more probable that the mischief was due to a peripheral pulmonary embolism possible sources of which existed in this patient both in the mouth and in the uterus. But, the excessive rarity of the former source, and the comparative frequency of the latter indicate rather the organs of generation than those of mastication as the *fons et origo mali.*

The alternative is a small unsuspected apex empyema or simple abscess in the posterior mediastinum. The cough the patient had previous to accouchment was occasional not constant, and in view of the subsequent history of the case, not incompatible with a throat irritation due to her foul mouth. It is, therefore, only as a remote possibility that I should feel disposed to associate this with the subsequent development of the case.

An abscess due to pulmonary thrombosis, may, moreover, have few local signs. Langenbeck has recorded one such case (*Journ. f. Kinderkr.*, xxxvi, 75 to 89. 1861), in which an abscess of the right lung due to transportation of a thrombus from the superior longitudinal sinus of the dura mater was visible through the pleura, and caused constant and distressing cough. The abscess cavity in this case was only the size of a chestnut and gave no diagnostic signs on auscultation or percussion, and was only detected post mortem. Again, had the original disease been extrapulmonary in the case I have related, it is probable that before the well-marked signs pointing to local disease had developed, there would have been some indication of a limited pneumothorax, such as the amphoric breathing which appeared later. There was none

such, and the passage which ultimately allowed air to escape through the wound only became sufficient for this purpose some days after the operation.

Dr. Peacock has recorded a case (*Transactions of the Pathological Society*, xix, p. 243) in which an hepatic abscess dis-

FIG. 12.

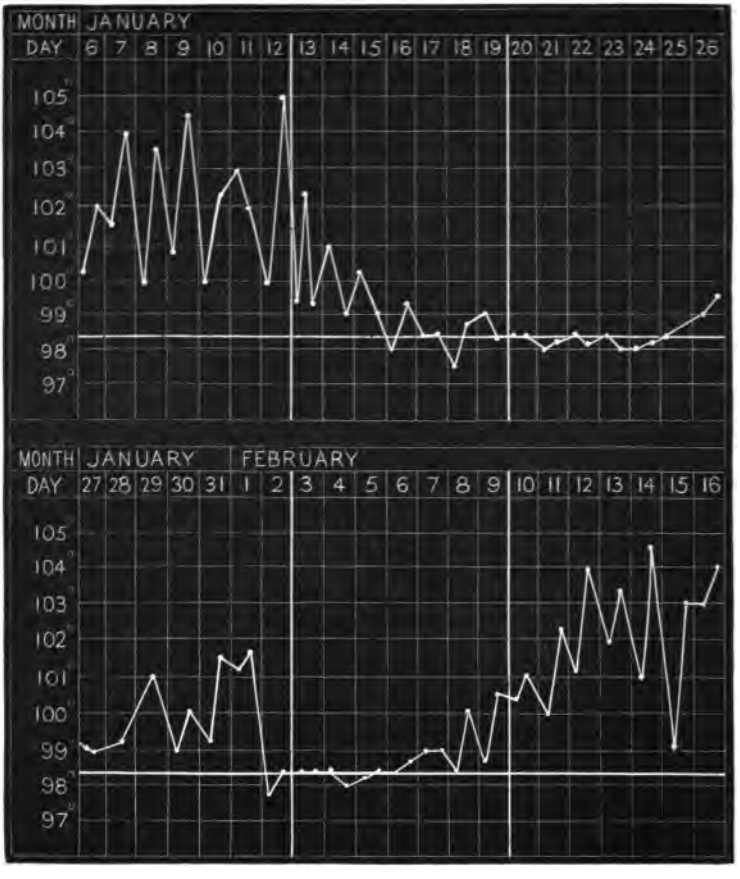

charged through the lungs, and in which there was a limited area tympanitic on percussion. This spot was marked, he says, by "a somewhat amphoric sound."

The thickness of the suprascapular region may have obscured a tympanitic note on percussion in my case, but it

did not prevent the detection of the amphoric breathing, which established itself later, and indicated an air-containing cavity. A similar physical sign led to the successful exploration and treatment of a very interesting case of pulmonary abscess related by Dr. Herbert P. Hawkins in the *Transactions of the Clinical Society,* vol. xxiv.

Dr. R. W. Burnet also exhibited a specimen which is recorded in the *Transactions of the Pathological Society* (vol. xxxiii, p. 191), in which an abscess cavity two inches in length communicated on the one hand with the bronchi of the right lung near its base, and on the other with the œsophagus. There was also carcinoma of the œsophagus and cardiac end of the stomach. There is no record of the pulmonary clinical history. The bronchi are, however, stated to have been full of offensive purulent matter.

Treatment was directed towards maintaining strength, reducing fever, and disinfecting the lung and mouth. Antipyrine seemed to have an influence in temporarily reducing fever, and inhalations of oil of eucalyptus were employed to deodorise and disinfect the nauseating expectoration.

The temperature charts were carefully kept throughout the illness, and I have appended a fragment of special interest as showing the relief of symptoms on the escape of matter in the earlier stage of the illness, and the very gradual but steady rise of temperature which marked the reaccumulation of the abscess, and preceded the great febrile movement which denoted constitutional infection. Had it been possible at this stage to drain the abscess effectually it is permissible to think that the issue of the case might have been different.

Recording defeat is never a grateful task, but the study of failure may be useful in organising future success; and it is in the hope that the history of this case may prove so, that I have ventured to relate it.

XXXIX.—*A case of Excision of the Cæcum, in which the two ends of the divided Bowel were successfully united by a continuous silk suture.* By W. Bruce Clarke. *Read May* 12, 1893.

AMONGST the many questions that are exercising the minds of surgeons at the present time, none perhaps is more important, than the determination of what is the best method of uniting two divided portions of bowel. It is unnecessary to repeat the various plans, from Senn's plates downwards, which have been advocated for the purpose, but the following case seems worthy of record, inasmuch as the simplest of all plans, viz. a continuous suture, was employed and was attended with an excellent result. The boy is present here to-night together with the preparation comprising his cæcum and adjacent portions of his large and small intestine which were removed at the operation.

R. H., æt. 4, was admitted into St. Bartholomew's Hospital on April 1, 1892, suffering from a right inguinal hernia. He was sent up to me from Cardiff with the following history.

He had a hernia at birth, and the sac could never be completely emptied of its contents. At two years of age he was operated on at Cardiff, but it was found to be impossible to return the intestine into the abdomen, and the wound was therefore closed. A good recovery resulted, but the hernia was *in statu quo.*

Present condition.—There is a large hernia on the right side about the size of an orange. It is partly resonant to percussion, and only partially reducible. Over the upper part of the swelling there is a puckered cicatrix at the seat of the former operation wound.

April 7, 1892.—The patient was placed under chloroform and an incision made about two inches in length in the direction of the old cicatrix. The tissues were much matted together. The incision was gradually extended in depth, but no sac was reached, and eventually an opening was made into the intestine. Finding that it was impossible to reach the sac in this situation, the incision was carried further upwards in the direction of the inguinal canal, and the peritoneal cavity opened higher up. On inserting the finger into the

cavity, the hernia was found to consist of the cæcum and vermiform appendix with about two inches of small and of large intestine. There appeared to be no hernial sac in the first part of the swelling at all, the cæcum being firmly adherent to the scrotum and testicle. Behind the cæcum, however, and towards the back of the scrotum there was a well-formed peritoneal sac communicating with the general peritoneal cavity by a wide mouth.

It was perfectly evident that any attempt to dissect out the hernia from the scrotum, and return it into the abdominal cavity would be all but impossible; and dangerous as well on account of the hole made into the intestine early in the operation, whilst merely to close up the wound left the child in precisely the same condition as he was before the operation. Such being the case I decided to cut across the small and large intestines where they entered the sac, a proceeding which would involve but little handling of the parts, and could be rapidly accomplished. The child had already been some time under the anæsthetic, and it was therefore advisable to finish the operation as soon as one reasonably could.

Mr. Bowlby, who was assisting me, held the ends of the small and large intestine where they entered the sac whilst I divided them with a pair of scissors. The only Senn's plates which were at hand were so large and appeared so ill-suited to effect the junction of such small intestines, that I decided to unite them simply by suture.

A V-shaped piece of the mesentery by which both pieces of intestine were attached to the abdominal wall was excised, and the edges rapidly united by a continuous silk suture, which at the same time arrested all hæmorrhage. The free edges of the peritoneal and muscular coats of the cut ends of intestine were then united also by a continuous suture, the stitches being placed rather further apart in the large intestine than in the small, so as to make the two ends fit accurately together. As soon as this row of stitches was completed, a second row of continuous stitches was made to encircle the large and small intestines about an eighth of an inch further from their two cut ends. By this means the small intestine was invaginated into the large for a short distance.

The encircling rows of stitches were not in the strictest sense of the term a continuous suture, because they were fastened off three times in each case so as to prevent the dragging on the stitches in one part of the circumference of the bowel, making them loose in another portion and thus

encouraging leakage. The peritoneum, which had been protected by a sponge, was not in any way soiled, so that the opening into the abdominal cavity was speedily closed by three or four sutures.

On examining the contents of the hernial sac, it was at once evident that they were so closely adherent to the testicle that no attempt could be made to separate them. The whole contents of the sac, together with a portion of the scrotal wall, were therefore removed *en masse*. The spermatic cord was very tense, and seemed to be dragging the contents of the hernial sac up towards the abdomen. It was securely ligatured before division, and no sooner was it severed than it disappeared up under the peritoneum out of sight. The edges of the scrotum were brought together with a continuous suture, and the wound dressed with cyanide gauze.

The operation had lasted over an hour,* and the patient was much exhausted. A few teaspoonfuls of milk and brandy were administered at once, and $\frac{1}{12}$ grain of morphia, so as to ensure absolute quiet. As soon as the effect of the chloroform had begun to pass off the patient exhibited signs of great restlessness, and the pulse was very rapid and could scarcely be counted. Another $\frac{1}{12}$ grain of morphia was administered, and also a few teaspoonfuls of milk and brandy, and directions were given to the house surgeon, Mr. Thomas, to administer morphia in sufficient quantity to ensure absolute quiet on the part of the patient.

April 8.—On the next day there is a note in the afternoon stating that during the twenty-four hours which had elapsed since the operation seven doses of morphia had been administered, $\frac{1}{12}$ grain on each occasion. Up to 8 A.M. the child had been very restless, but had slept from 11 A.M. to 3 P.M. There had been no vomiting. Five ounces of milk with a little lime water and three drachms of brandy had been taken by mouth.

After this time the boy went on uninterruptedly well. On the third day he took fifteen ounces of milk and lime water, and passed flatus abundantly.

April 12, *i. e.* five days after the operation, the wound was dressed, and found to be completely healed. All stitches were removed.

* The time was taken up in finding out the exact condition which had to be dealt with. The actual intestinal suture, when once it was determined on, including the closure of the wound, did not occupy more than a quarter of an hour.

April 13 and 14.—There was some tenesmus and restlessness on account of a motion which would not come away, and some morphia was administered to ensure quiet. At last (April 14) the motion passed, and all tenesmus disappeared.

April 18.—Said he felt hungry, and had some solid food in the shape of soaked biscuits for the first time.

April 25.—Had minced fish to eat, and got up for the first time.

May 12.—Went home to Cardiff. There was no trace of hernia or bulging at the seat of operation.

Since writing the above I have had the pleasure of reading a case published by Mr. Treves in the *Lancet* for March 11, 1893, p. 521, in which a somewhat similar plan of uniting the bowel was adopted after the removal of an epitheliomatous growth from the sigmoid flexure, and with perfect success. I am glad to find myself in agreement with so distinguished a surgeon in recommending a simple method of intestinal suture instead of the somewhat complicated plans which have hitherto found most favour.

XL.—*Case of Pseudo-bulbar Paralysis, probably due to a lesion in each cerebral hemisphere.* By G. Newton Pitt. *Read May* 12, 1893. (*The patient had been exhibited as a 'living specimen.'*)

J. C., æt. 51, labourer's foreman, married, has four healthy children. His wife died of alcoholism six months ago, and he is said to have been intemperate. A year ago he consulted Dr. Nichols for some ulceration of his right leg following an injury. There is a pigmented, depressed scar on the front of the leg above the ankle.

He was in perfect health until last Christmas when he had an attack of slight right hemiplegia affecting his face and arm, with some difficulty in distinct articulation, but no aphasia. The right side of the face was markedly paralysed and this has persisted. He has not been able since then to close his right eye, except momentarily. The mouth was drawn to the left. For about two weeks he was unable to use his right hand, but could move the shoulder and elbow-joints. For three weeks he could not write, and for two weeks he could neither feed nor dress himself, after this he regained the use of his hand. The inside of his mouth felt as if it were swollen. He was able to protrude his tongue. Last April he had an attack of pleurisy. There is no history of syphilis. He was under treatment for a month.

Since then he has been to work regularly; and with the exception of some facial paresis and difficulty in mastication he had recovered completely.

On February 25 he went to work as usual. At 9.30 A.M. he felt very giddy and noticed some numbness about his left hand and face. He found he was speechless and could not utter a sound. He did not lose consciousness. He went home and found his speech suddenly returned to him unimpaired. He was able to describe his attack fully. During the day he lost his speech five times, and after each occasion except the last it suddenly, after an interval, returned, and, for a time he was able to talk freely and correctly. Since 5 P.M. on February 25 he has been unable to utter any sound, and with each loss of speech he has been quite unable to swallow. If he takes fluid into his mouth he is unable to

pass it into the pharynx, but on one or two occasions it has set up a sudden explosive cough.

During the day he felt well except for the symptoms to be described. Numbness with paresis of the left upper extremity, paralysis of voluntary movement of the muscles on both sides of the face, immobility of the tongue, inability to open or close his mouth more than half an inch except when he yawns, absolute speechlessness, and inability to swallow.

His condition remained unchanged until on February 27 at 10 P.M. when I saw him, sixty hours after the onset of his attack, during which time he had not been able to swallow anything. He walked into the ward from the gate of the hospital and came under the care of Dr. Goodhart, to whose kindness I am indebted for permission to publish the case.

He is of a ruddy complexion, well developed, and looks healthy. His face is expressionless, and the normal facial lines are absent. He is quite unable to raise or move his lips, to whistle, to wrinkle his forehead, or to move any facial muscles, in fact, except to close his eyelids momentarily, but he cannot shut his eyes tightly. A sudden movement in front of his face causes him to wink slightly. When told to laugh he is unable to move his face, but he can smile when amused. The skin of his face and limbs is hyperæmic and perspires readily. The conjunctivæ are congested.

There is no diplopia and no paralysis of his ocular muscles, but when told to follow an object he does so, imperfectly and slowly; when one eyelid is closed he is unable to move the other. His eyelids are closed in sleep.

The pupils are of medium size, and react to light and accommodation.

The optic discs are hyperæmic, but otherwise normal. Sensation over the head is normal.

His mouth remains open a quarter of an inch, and he can open the lower jaw as much more. Even with a gag, however, it is found that there is considerable resistance to further opening. He cannot close his teeth, and his masseters and temporals can only contract feebly. He cannot move his jaw sideways with his pterygoids. His mouth and breath are foul. The right cheek, since Christmas, has been liable to be bitten; his gums are congested and ulcerating slightly round the teeth, and there are unhealthy irritable ulcers on the lips, &c.

His tongue lies motionless in his mouth, and he is quite unable to move it, but when an attempt was made to pass an

œsophageal tube through the mouth the tongue moved. The muscle is not atrophied, nor is there fibrillar twitching.

It is not possible to see the palate, but it probably does not move, as he snores whenever he squeezes firmly with his hand, or on any other exertion.

He is able to breathe in and out freely, and there is no dyspnœa or respiratory obstruction. He cannot cough voluntarily, but when a nasal tube passed into the larynx he coughed, and when saliva or liquid reaches his larynx he coughs. The cough-reflex is therefore present. He can emit no sound. When he attempts to phonate or swallow, the larynx and hyoid do not move.

Since the onset of his attack on February 25 he has been unable to swallow anything. If he takes liquid into his mouth it either does not pass into the pharynx, or if it does it sets up a cough and is at once expelled. On admission his thirst was so intense that, powerful man as he was, he had cried at home in consequence.

He is able to move all his limbs, but the grasp of both hands is feeble—R. 86 lbs., L. 60 lbs. The knee-jerks are brisk, the left being the more marked. No difficulty with regard to micturition. No anæsthesia, but when the left hand is rubbed it gives him an abnormal and painful sensation. Sensibility to touch and taste is retained in the tongue. No wasting nor fibrillar twitchings of any muscles. His vision is good.

Chest emphysematous. The diaphragm and the thoracic muscles move normally.

His hearing is good. He is able to write perfectly, and is very intelligent. When a hand is brought down suddenly in front of his eyes he sometimes winks, and this reflex is more vigorous than when the ordinary winking takes place. The hyoid bone remains motionless when he is told to attempt to swallow, but moves at once when fluid has collected in the pharynx.

His walk is normal; he is not ataxic, and has no rigidity. He can turn his head in all directions quite normally.

When told to take a deep breath it sometimes happens that the epigastrium is sucked in, owing to the diaphragm not contracting simultaneously with the intercostals, but after two or three deep inspirations they work together.

The urine is of a sp. gr. 1020 and contains albumen, but is free from sugar.

His muscular sense is normal. The saliva runs from his

mouth slightly, and the lower lip is slightly pendulous. There is some sub-conjunctival œdema. The left knee-jerk is brisker than the right, there is no clonus. The electrical reactions of the facial muscles are normal.

The liver and spleen are enlarged.

There has been numbness over the left hand up to the wrist since February 25, 1893.

Since he has been in the hospital his condition has remained unchanged. He is fed three times a day with a nasal tube, and has been taking biniodide of mercury.

At first he was fed with an œsophageal tube, but opening the mouth with a gag gave him so much pain it was necessary to feed him instead through the nose. The ulcerative stomatitis was treated with chlorate of potash, permanganate of potash, and boric lotions, and gradually cleared up.

March 7.—Normal weight 14 st. 3 lbs., weight in February 12 st. 3 lbs., present weight 9 st. 3 lbs.

April 7.—He is now fed with œsophageal tube without difficulty, and passes the tube himself.

April 10.—An attempt was made to look at his larynx, but the violent reflex contractions of the tongue when it was pulled even slightly quite prevented this.

April 14.—Electrical examination of muscles: levator-labii superioris, occipito frontalis, orbicularis palpebrarum reacted normally to faradism and galvanism; the zygomatici did not react to faradism, but reacted normally to galvanism; the buccinators acted neither to faradism nor galvanism. He has vomited once while in the hospital.

The urine generally contains ¼—1 part per 1000 of albumen, the urea varies from 2 to 2·5 per cent., and the sp. gr. from 1011 to 1020; uric acid crystals readily deposit; the amount varies from two to four pints.

April 26.—The patient feeds himself with a tube, he went home to-day. He is able to walk about, but he is still without any voluntary power in the facial, masticatory, pharyngeal, and laryngeal muscles, although the reflex movements remain unimpaired. There is no fibrillar tremor, and no wasting. The saliva does not run so much from his mouth, which is always open; he possibly swallows slightly better, and can open his mouth rather wider.

I am indebted to Mr. W. H. Jewell for the notes of this patient while in the hospital.

Since Dr. Hughlings Jackson drew attention in this country in 1869 to the possibility of acute glosso-labio-laryn-

geal paralysis being due to two distinct lesions, one in each cerebral hemisphere, several such cases have been recorded. He particularly insisted that if a patient who has had an attack of hemiplegia be afterwards affected with paralysis, in which difficulty of swallowing is a marked feature, it is most probable that there is a second lesion in the opposite hemisphere.

Among others, a case of Dr. Jackson's was published by Dr. Taylor, in the *Lancet* for December 10, 1892.

Dr. Ross also contributed an admirable paper on "Pseudo-Bulbar Paralysis" in *Brain*, vol. v, p. 145.

An elaborate paper, by Boulay, in *Gaz. des Hôpitaux*, July, 1891, is condensed in *Brain*, vol. xiv, p. 352, by Mr. R. Atkinson.

To these papers, especially the last, I am indebted for my knowledge of the literature of the subject.

Over thirty-three cases of pseudo-bulbar paralysis have been published, and in twenty-five there has been a post-mortem examination; in most cases bilateral lesions were found, and frequently they were symmetrical. In five cases, however, one of the hemispheres was found to be normal.

The lesions may be in the cortex, as in a case of Dr. Barlow's, in which there was softening in the second and third frontal convolutions on both sides. Usually in such cases the pseudo-bulbar symptoms have been incomplete.

In the majority of cases the lesions have been in the basal ganglia, and it is remarkable how frequently the outer third of the lenticular nucleus has been involved, and not infrequently the two lesions have been limited to this part.

The lesions are usually patches of softening or of hæmorrhage, in half the cases the cerebral vessels were atheromatous, and half the patients have been above the age of sixty.

In three cases published by Otto lesions have been found in the medulla as well as in the hemispheres, but in others minute search has shown the medulla to have been normal.

The typical symptoms of a pseudo-bulbar paralysis, as distinct from a progressive bulbar paralysis, are an attack of hemiplegia, with more or less difficulty in articulation, followed after a longer or shorter interval (often months) by an attack of hemiplegia upon the opposite side, with which is associated great difficulty in swallowing, in articulating, and in moving the lips and tongue voluntarily. Saliva runs from the mouth. The patient understands what is said, but his speech is very indistinct and embarrassed. There is, however, no

fibrillar twitching, no atrophy, no one-sided sensory disturbance, no great pyrexia, no circulatory or respiratory disturbances. The patients are not aphasic. The onset is sudden, and the paralysis of the various muscles is practically simultaneous, and does not progress. The masticatory muscles are affected at the outset of the illness, and not only in the last stage.

Now that attention has been drawn to the main symptoms the diagnosis of these cases is often feasible. In the present case it is to be noted that the first attack last Christmas was one of slight difficulty of articulation, with paresis of the right arm and face, the latter alone persisting.

Two months later there was an acute attack of paresis of the left arm and face, due to such a small lesion that the patient never lost consciousness; yet he at once became absolutely unable to swallow, to move his tongue or lips, or to utter a sound. The fibres to these regions had already been cut off from the left cortex, and a corresponding lesion on the opposite side led to complete paralysis of these groups of muscles. All these movements, it should be noted, are normally bilateral movements, and as such are innervated from either side of the brain; it has been established that such movements suffer but little with a lesion on one side of the brain, but very severely with a bilateral lesion.

Since the affection of consciousness was so slight the lesions must be small, and hence probably near to where the corresponding fibres are packed closely together, which is at the genu of the internal capsule.

It should particularly be noted that the patient cannot cough, except when the larynx is irritated, nor move his tongue nor soft palate, except when they are irritated; he cannot move his facial muscles, but when amused he smiles; he cannot close his eyelids voluntarily, but he can wink. In other words, the reflex actions are well marked, while the voluntary are in abeyance; a most conclusive argument for supposing that the lesions lie between the cortex and the nuclei in the pons and medulla.

The case is especially remarkable because the paralysis is more complete and marked than in any of the cases previously recorded.

The movements of the jaw are almost abolished; in none of the other cases was the paralysis of the larynx, of the tongue, and of the upper part of the face complete.

The patient has chronic Bright's disease. It may reason-

ably be concluded that the symptoms are due to two small lesions secondary to atheromatous arteries, two small patches either of softening or hæmorrhages, in the region of the genu of the internal capsule, one on each side of the brain. There is no evidence to lead us to suspect that the pons and medulla are anything but normal.

The prognosis in these cases is uncertain. If they survive the acute attacks, they are liable to further ones which need not occur for some months and may prove fatal. Otherwise, they may die from the associated chronic Bright's disease or fungating endocarditis, or from septic pneumonia due to the pharyngeal paralysis.

For the further clinical history and the pathological report of this case see page 250.

XLI.—*Intestinal Obstruction from Gall-stone; operation.* By Robert Nairn. *Read May* 12, 1893. (*Introduced by the President.*)

L. C., female, 75, fat but healthy-looking. First seen September 28, 1892. Vomiting; bowels not open for twenty-four hours. Has taken castor oil, which was rejected. Pulse good. Temperature normal. Tongue very foul. Vomited matter dark green. Slight pain on pressure in right iliac region. No tympanites. No blood ever passed by bowel. States she has had similar "bilious attacks." No symptoms and no history pointing to gall-stones.

Ordered a simple enema and a mixture of bismuth and hydrocyanic acid and given a draught of Tr. Opii ℥xxv.

September 29.—Enema said to have acted slightly. Vomiting less. No pain. Some flatus passed.

October 1.—Stercoraceous vomiting.

October 3.—Seen by Sir Dyce Duckworth, who recommended operation if the obstruction was not relieved by the following day.

October 4.—Chloroform. Abdomen opened by median incision. Cæcum normal. Some hardened fæces in ascending colon. Latter could not be followed into transverse portion on account of adhesions under the liver. Descending colon empty.

Small intestine collapsed, followed upwards. A calculus was found blocking the jejunum with dilated intestine above it. An attempt was made to press the calculus downwards, but this was impossible. It was then moved up about 2 inches and the intestine opened after tying above and below with elastic bands. The calculus, which was almost spherical, measured 3 inches in circumference.

The intestine was closed with fine silk (Lembert's) sutures after thoroughly washing with warm boracic lotion. A continuous suture was put over the Lembert's.

The intestine was then examined upwards and was found to be adherent in the region of the gall-bladder.

The sutured part was finally examined, abdomen douched with warm boracic lotion, and dried with Gamgee "sponges."

Abdominal incision sutured with wire and continuous silk.

The operation lasted one hour and twenty minutes. The patient's condition seemed good. Pulse good, and extremities warm. She said she felt quite comfortable after she was in bed.

Went on well for nine and a half hours, then she became suddenly cold with feeble pulse, and died in half an hour.

No post-mortem examination.

I wish to add that the case was under the care of Mr. A. C. Brock.

XLII.—*Case of Colitis with Ulceration treated by Inguinal Colotomy and local treatment of the ulcerated surfaces, with subsequent closure of the artificial anus.* By Mayo Robson. *Read May* 26, 1893.

THE following case, which failed to yield to careful medical treatment, and to various forms of surgical treatment applied *per anum*, would seem to me to be most accurately described as one of Colitis and Proctitis with ulceration, and like other cases described in text-books and in the journals, the cause was as obscure as the treatment was difficult. As all the ordinary forms of medical treatment failed to relieve and as treatment *per anum* proved useless or worse, I decided to open the colon, and through the artificial anus to regularly wash out the ulcerated mucous canal, thus hoping to cure the ulceration, and to close the fæcal fistula when the disease was cured.

The following notes of the case were furnished by my house surgeon, Mr. Basil Hall, M.B., C.M.Cantab.

E. W., æt. 37, a domestic servant and single, gave the history of having been in good health up to March, 1890, when without apparent cause, she began to suffer from pain, bleeding, and a mucous discharge from the anus on defæcation, which was too frequently repeated.

In May she was admitted to the Leeds Infirmary, when examination of the rectum by the speculum revealed a granular condition with several ulcerated spots, and under an anæsthetic the insertion of a Fergusson's vaginal speculum showed the condition to prevail as high up the bowel as exploration could be effected. The anus was dilated and nitric acid applied to the granular surface. This did not give much relief and the bleeding still continued. The amount of blood lost varied from one drachm to two ounces on different days.

Under the use of large hammamelis injections and the administration of ipecacuanha and hammamelis internally, she obtained a little relief and was sent to a convalescent home. In September, 1890, she returned to the Infirmary as the amount of blood lost was increasing. The discharge was sometimes bright red in colour, sometimes brownish,

contained blood-cells both red and white, and a quantity of mucus.

Her general health was suffering, and she showed signs of anæmia.

The anus was again dilated and the bleeding ulcers, as many as could be seen through a vaginal speculum, were lightly touched with the actual cautery, after which boracic acid injections were used thrice daily. This gave some little relief. In October the discharge became more purulent, but still contained blood.

In November she was discharged feeling a little better, but still passing blood with the motion.

After this she was treated medically both in the infirmary and by physicians unconnected with the hospital, but although opium, astringents, and ipecacuanha in large doses were tried internally, and various astringent and emmolient injections were employed, she returned after seven months in an anæmic condition and in a state of mental and physical depression. The pain over the sigmoid flexure made me certain that the disease had extended, and the passage of "casts" of the large bowel with mucus and blood clearly pointed to the need of other remedial measures.

On June 28, 1891, the first stage of inguinal colotomy was performed, the bowel being opened four days later. On opening the bowel the mucous membrane was found to be in a sloughy ulcerated condition, and was worse than examination by the rectum would have led one to suppose.

In the middle of July, as simple rest to the bowel showed no sign of affording relief, the bowel was irrigated daily with alum lotion, from the anus to the colotomy opening and *vice versâ*. This, however, gave very little relief, and in August fibrinous casts were still being passed *per anum*.

In September, after other astringent injections had been tried, the rectum and colon were syringed out with half an ounce of hammamelis to a pint of water daily. The discharge was very offensive and contained large thick membranous casts of the rectum, some of the casts forming tubes two inches in length.

Towards the end of September boracic acid solution, ½ oz. to a pint of water was used, the irrigations being carried out freely night and morning.

In October the "casts" were fewer in number and the discharge was not only less in amount but sweeter, and did not contain blood.

November 1.—The report states: "Still a little discharge of pus and mucus, but no casts."

November 16.—General condition much improved. Very little discharge. Made an out-patient.

December 1.—As the rectum and colon appeared to be healthy and all abnormal discharge had disappeared, she was again admitted into hospital and the fæcal fistula was closed by a plastic operation on December 3rd.

The wound healed by first intention except a minute fistula just admitting a probe, and this ultimately closed after being touched with the actual cautery.

In February the patient reported herself as quite well, except for constipation.

In March I had a letter from Dr. Coombs, of Bedford, to say that he had seen the patient and that she appeared to be, and reported herself, quite well.

It will be seen that the course pursued was fully justified by events, and the patient was apparently cured of a disease which would otherwise, in all probability, have ended as similar ones have done, in death from exhaustion, if not from some intercurrent complication as hæmorrhage or peritonitis.

It would seem to me feasible and advisable to treat other chronic ulcerations of the bowel in a similar way after the failure of all ordinary medical treatment.

Fortunately in this case inguinal colotomy, an operation attended with practically no risk, enabled me to reach the disease, but if the affection in another case extended higher, I should not hesitate to open the bowel in any part of its course in order to adopt local treatment.

XLIII.—*Two cases of Chronic Albuminuria, one of* twenty-five *years and the other of* forty-three *years' duration; remarks on chronic albuminuria.* By Francis Hawkins, M.B. *Read May* 26, 1893.

X. Y. Z., a gentleman æt. 49, married, was brought to me in January (1893) for an opinion as to the advisability of applying for a life assurance policy. The reason assigned for seeking such opinion was that albumen had been known to be present in the urine for the past twenty-five years, and that while a previous proposal had been accepted by one or more offices, it had been rejected by many.

Family history.—Beyond the fact that his father, who had good health, died suddenly, at the age of 56, there is nothing important to note.

Personal history.—So far as he knows, he has never had scarlet fever and, with the exception of measles, has never been ill. There has never been any swelling under the eyes. The sight has always been good, and there has been no desire to micturate during the night. He has always lived a country life, and hunted four or five times a week, being now and having been for some years past master of the hounds. Twenty-five years ago when making application for life insurance, albumen being found in the urine his proposal was rejected. A few years later he placed himself under the care of the late Sir William Gull, who enjoined strict regimen as to diet; and I may here add that although this gentleman has been very abstemious as to his food and was at one time a total abstainer, the urine has, on every occasion of an examination, been found to contain albumen.

Examination of the patient.—He is of medium height, spare and wiry. The muscles are well developed. Skin slightly rough, and in parts somewhat scaly. The brachial arteries pulsate slightly.

Heart.—Apex beat is displaced to the nipple line, the sounds at the base being accentuated, those at the apex normal.

The pulse is regular, and there is no marked tension.

Before giving the results of my examination of the urine, it should be stated that the day previous to consulting me

was spent in hunting; the covert was broken early and a long run enjoyed. This implies severe muscular exercise. In the evening a champagne dinner was indulged in.

Urine.—It was clear, and of a dark amber colour; specific gravity 1025. With heat a dense white precipitate was thrown down, which on the addition of cold nitric acid, increased. On standing twenty-four hours one third of the urine consisted of this white precipitate (albumen).

Microscopically.—Coloured and colourless uric acid crystals were seen.

Being much interested in this case I asked my friend Mr. Berridge, the late Actuary at the Equity and Law Life Assurance Society, if he could by any means obtain for me the reports sent in to the various offices for which proposals had been made—this he kindly undertook to do, and succeeded in sending me eight reports, and I am, therefore, enabled to place these before the Society.

The earliest report was made in 1872, when the urine was said to be dense with albumen and had a specific gravity of 1020. One year later (1873) there was only a slight opalescence on boiling, and three years later (1876) a trace of albumen was found; the specific gravity being still 1020. Seven years after this (1883) there was a large amount of albumen and microscopical examination showed hyaline tube casts. One year after this (1884) the urine again contained a small quantity of albumen—*one twelfth*—and its specific gravity was 1024. Three years later (1887) a still smaller quantity was found—*one fortieth*—the specific gravity being 1020. The year following (1888) a trace only was discovered. Four years later (1892) the urine was examined twice, on one occasion albumen being large in amount and on the other small.

Then we come to the examination I have read to you as having been made by myself (1893). This gentleman is still enjoying good health and following his usual occupation, and a point of interest is that he does not easily become indisposed—hard riding and vigorous exercise having, so far as subjective phenomena are concerned, no effect upon him.

Interesting as this case is I am enabled to place before this Society, through the courtesy of Mr. Russell Dodd, notes of a case of even more interest so far as *duration of albuminuria is concerned,* such having constantly existed for *forty-three* years.

The subject of this interesting condition—a member of our own profession in a lucrative West End practice—feeling indisposed, in 1849 consulted the famous Dr. Bright, who, examining the urine, found albumen, and gave as his opinion that the patient could not live for more than two years. In consequence of this the practice was given up and a life in the country selected.

Urine.—The urine is said to have contained at all times when examined one third albumen; this has been so without a doubt since 1874, from which time Mr. Russell Dodd had the patient under observation. The specific gravity was usually 1012, and nightly micturition was necessary for certainly eighteen years. In 1887, in addition to the albumen, sugar—5 per cent., as reported by Mr. Squire—was found in the urine; nine months later only a trace of sugar was discovered, and subsequently none at all.

Diarrhœa was for many years an occasional symptom.

Heart.—The pulse was frequently intermittent. The heart at times irregular. There was some hypertrophy, but the sounds, beyond being accentuated at the base, were said to be normal.

Treatment.—For ten years the patient was dieted, but since then has taken anything he wished for. For the diarrhœa calomel, gr. ij and brandy were administered. When sugar was observed in the urine chipped toast and meat were given and farinaceous food forbidden.

Death.—This gentleman died from cerebral hæmorrhage, aged 88, in the year 1892, forty-three years after being told by Dr. Bright that he had renal disease, and that early death was inevitable. The day previous to his death he took carriage exercise.

Remarks.—These two cases illustrate the fact that life may be of the ordinary duration in those who have chronic albuminuria, and also that they may enjoy, in fair health, as long a life as those not thus affected. Such facts make one ask:—Can we by any means forecast when those having chronic albuminuria may possibly die early, and thus have few, if any, prospects of life, or when they may live as long as, and perhaps longer, than those in good health.

With the endeavour to formulate some lines of thought as guides whereby observed facts may enable us to form our judgment, I will examine first as to

Family history.—It may be remembered that the father of the gentleman whose case I have recorded died suddenly

at the age of 56. His health had been, and was, good up to the time of his death, and it may be suggested, I think, that death was due to cerebral hæmorrhage, consequent upon interstitial nephritis, and if this be so may I suggest that the son, who had never been ill and never had scarlet fever, inherits a tendency to chronic albuminuria, consequent upon interstitial nephritis, the presence of which I think clinical evidence indicates. In looking over my notes of albuminuric cases I find that in two the father died from renal disease. The health is good in both cases, one I have watched for eight years had for a long time albumen, but in a specimen examined some few days since none was to be detected.

The late Dr. Moxon* cites one case of the mother dying from albuminuria and a son suffering from such.

Dr. Dickinson,† writing on granular kidney, gives the history of some members of an ancient house who inherit this complaint. In one case albumen was found at the age of nine, and was persistent certainly till the patient was twenty-one years old.

Then there is the fact that albumen may exist in several members of the same family. I have in my notes only one such instance, but the late Dr. Moxon records eighteen, and regards the duration of life as good. These facts show that in what I will term hereditary or congenital albuminuria the individual life history may be good.

I will next consider the histories as to antecedent or associated disease.

Scarlet Fever is well known as being a fruitful source of albuminuria, but only a few cases have been recorded when chronic albuminuria has existed for several years after such. Dr. (now Sir George)‡ Johnstone, recording in the *British Medical Journal* several instances of intermittent and latent albuminuria, mentions the case of a gentleman who had scarlet fever followed by dropsy in 1836, albumen being first discovered in 1841, and on every subsequent occasion of examination. This gentleman died in 1866, forty-seven years of age, and twenty-five years after albumen was first discovered.

Prof. Grainger Stewart§ cites a case of greater interest. A lady, who had scarlet fever between the age of eight and

* *Guy's Hospital Reports*, 1878.
† *Diseases of the Kidney*, vol. ii.
‡ *British Medical Journal*, 1889.
§ *Lectures on Important Symptoms*: ii. Albuminuria, 1888.

ten, followed by persistent albuminuria, enjoyed good health and married when twenty-two, had a family of six children with no bad symptom at the confinements, died from dropsy, with uræmia, between the age of forty-five and fifty, having had persistent albuminuria for thirty years.

Then *Ague* has been recognised as a cause of or in association with chronic albuminuria during the last few years—two cases where such was the only antecedent illness have been under my own observation—one, aged thirty-six, died within a year after seeing me; the other, aged fifty-six, who first saw me five years ago, still enjoys good health, his urine is always albuminous and of low specific gravity. Dr. Dickinson cites a case of a gentleman who had albuminuria, probably due to ague, and who was under observation sixteen years, the urine was always of a low specific gravity.

Gout.—Dr. Ralfe mentions incidentally in a paper read before the Medical Society of London a case of albuminuria with gout, seen by the late Dr. Murchison in 1874—who is still living—thus making the duration of life certainly possible for nineteen years.

Syphilis.—One case, a man aged sixty-six, who sees me occasionally, and has done so for the past five years, always has albumen in his urine, and yet he enjoys fairly good health.

Rheumatism (not fever).—Chronic albuminuria with rheumatism as the only antecedent illness seems to be capable of many years' duration. I have only seen one such case and certainly for the past five years this gentleman has enjoyed good health, notwithstanding the fact that on one occasion he had hæmaturia, which, however, was unknown to himself, and was only found accidentally in urine under examination.

I have myself never met with a case of persistent albuminuria with a history of a previous definite attack of acute nephritis from *cold*, neither have I been enabled to find in literature any case or expression of any such opinion.

Having thus shown that so far as heredity and associated diseases are concerned, the prognosis may be good, I will inquire as to symptoms due to the disease which may develop during its course. And firstly, as to albumen itself, apparently from the two cases recorded the amount is of no importance nor is the presence of hyaline tube casts.

Then bronchitis may be intermittent or recurrent and not necessarily cause death. Hæmoptysis also may occur, as I

have shown in a case read before this Society,* when it recurred for over a year previous to death.

Œdema of the extremities, although by no means of common occurrence, may also be intermittent or recurrent. Cerebral hæmorrhage as indicated by hemiplegia may also occur and not cause death. I have once seen such in association with Cheyne Stokes' respiration and yet recovery took place.

Hæmaturia may also occur; but I need not go further for probably such cases are better known to members of this Society than to myself. It seems to me that we must go further before we can find a basis for prognosis, and I would for a moment ask attention to the ages at death of people dying with interstitial nephritis, and I select this form of kidney disease because all cases of chronic albuminuria which have been examined by me seem to indicate this lesion. The† youngest age at which I have found a case recorded is nine years. Then in the *Pendlebury Hospital Reports* I find one case at eleven years and nine months. And Dr. Dickinson cites two cases aged respectively twelve and fourteen; the latter died from cerebral hæmorrhage. In 106 cases recorded in the *Middlesex Hospital Reports* (published), I find 2 died at nineteen; 13 between twenty and thirty; 13 between thirty and forty; 16 between forty and fifty; 33 between fifty and sixty; 23 between sixty and seventy; 4 at seventy-one; 2 at seventy-two, and one at eighty. These facts help us in a measure to estimate the capacity for life so far as age is concerned in the cases now under review.

This inquiry is, of course, imperfect, for I have not been able to find the antecedents of these cases or the duration of albuminuria. Another point of interest is the mode of death and the associated or causal lesions. Now, in 106 cases, twenty died from cerebral hæmorrhage, and it is of extreme interest here to notice that in cases so dying both kidneys were diseased; œdema of the extremities was not recorded in one single instance, and œdema of the lungs in two only, thus showing that all was going on well until the fatal rupture of a vessel occurred. The remaining cases died from what I will term "œdema," that is to say there was œdema and congestion of the lungs in all cases, and in most hydrothorax with œdema of extremities in some. In a few instances only one kidney was diseased. To my mind these facts are most important, for knowing that such lesions led to death, can we

* *Clin. Soc. Trans.*, vol. xxv.

† Gull and Sutton, Royal Medical and Chirurgical Society.

with reason say when the condition or conditions—say œdema or cerebral hæmorrhage—are likely to occur (now it is true that such may occur as we have seen, and yet not cause death).

In cases dying from both causes, there was this common factor—hypertrophy of the heart and arterial sclerosis with, in some few, atheroma. Now, the most common cause of death, viz. œdema, I think may be explained by the fact that the auriculo-ventricular orifices become dilated and so allow of regurgitation, and hence we ought in such cases to find a murmur at the mitral area, but—as a matter of fact—such is not always present (whether this be due to the conditions of the heart and vessels need not now be inquired into), but in cases where it is absent, it would appear that we have no basis for evidence or indication that œdema may or will occur.

Have we evidence that cerebral hæmorrhage may occur? Now, it will be remembered that in all these cases both kidneys were diseased, and then the disease (interstitial nephritis), was further advanced in each case, and I think it probable that in such cases the fibrous ring around the auriculo-ventricular orifices becomes, as the arteries, sclerosed, and so prevents dilatation of the orifice; hence œdema does not occur, and here I think, in some cases we may have indications of a probable danger ahead by the alteration in quality of the sounds at the apex; this I will merely now term a clang tint. I have observed it in more than one instance preceding a fatal result; and one case impressed me much, a gentleman aged 36, who had had ague, consulted me, believing himself to be in good health, but required advice about a different matter.

His heart was hypertrophied and the vessels sclerosed; the urine was of low specific gravity and contained albumen. At the apex there was what I have termed the clang tint. I wrote to the gentleman sending me the case an unfavorable prognosis, having previously observed that when such a condition of the first sound of the apex was associated with albuminuria danger was to be anticipated.

This opinion was vetoed, and the case being regarded by another in a different light, advice was given on lines desired by the patient; within eight months of my seeing him he died from cerebral hæmorrhage associated with purpura.

I would thus say that the symptoms arising during the life history of an albuminuric are not in themselves of great value in prognosis, but that the condition of the cardio-vascular system is of value and that the quality of the sounds at the apex is of still greater importance.

LIVING SPECIMENS

DESCRIBED BY CARD.

*** Published in accordance with the Regulation relating to the exhibition of living specimens at the meetings of the Society, viz. that "each case shall be accompanied by a card containing a brief description of the points it illustrates, such card to be retained by the Secretary for publication or not in the *Transactions* at the discretion of the Council."

I.—*A case of Macrocheilia successfully treated by Electrolysis.* By W. Arbuthnot Lane, M.S. *Exhibited October* 28, 1892.

W. W., æt. 44, three years ago fell heavily against a table, striking his mouth. About five months afterwards the lower lip became slightly swollen, and nearly three months later it swelled up enormously during a single night, forming a hard, brawny, indurated, projecting mass. Later the upper lip became similarly affected. Both lips at intervals became acutely inflamed and very painful, each inflammatory attack on its subsidence leaving the parts larger and more brawny than before. He was treated by various doctors, and for six months he attended at St. Bartholomew's Hospital without deriving any benefit, the condition continuing to progress, and the adjacent portions of the cheek becoming thickened and hardened.

In October, 1891, he came under my care, when I found that both lips were enormously thickened and prominent, giving him a very objectionable appearance, besides very great pain and discomfort. The lips felt very hard and

brawny, and the adjacent portions of the cheeks were much thicker than they should be. It was quite obvious that any method of excision of portions of the thickened lips could be of no service whatever to him; and as medicinal treatment had been unsuccessful, I determined to see what electrolysis would do for this condition. This treatment was adopted on several occasions, each application causing a marked diminution in the size and prominence of his lips. Since electrolysis was commenced he has had no recurrence of the inflammatory attacks which caused him so much pain, discomfort, and deformity. At the present moment the upper lip has returned to its normal size and condition. The lower one appears to me to be slightly thicker than it should be, but he assures me that it is not more bulky than it used to be before the onset of his symptoms.

Both lips now feel soft and natural, and the fulness of the cheeks is hardly if at all perceptible. I believe that this is the first case which has been treated by electrolysis, which is apparently infinitely more appropriate than the clumsy and very inefficient method of excision of portions of the hypertrophied lip.

I am applying the same method to the somewhat similar lymphatic hypertrophies met with in infancy with great benefit.

II.—*A case of Fracture of Patella treated by Barker's method: bony union.* By Herbert W. Page. *Exhibited October* 28, 1892.

H., A coalheaver æt. 33, broke his left patella by falling down steps on May 6, 1892. Fragments were an inch apart. On May 18, an ice-bag having been applied in the meantime, the fragments were brought into close apposition by silk subcutaneous suture according to Barker's method. The leg was kept on a splint for three weeks, and the patient was discharged from St. Mary's Hospital on June 25. He is now at his work as before the accident, he can flex his knee to a right angle, and there is unquestionably bony union, the line of fracture being barely perceptible.

III.—*A case of Congenital Deficiency of Chest Wall.* By JOHN ABERCROMBIE, M.D. *Exhibited October 28, 1892.*

ALBERT B., æt. 2 months, was brought to the Hospital for Sick Children, Great Ormond Street, on October 24 of this year, with congenital defects of his chest wall and left hand. He is the third child, and was born at the full term; of the others one is dead, but neither of them presented any congenital defect, nor is there any malformation in either parent. The mother has no theory as to the causation of the deformities, but on being questioned recalls that when about three months pregnant with this child she was frightened by a dog at a place of amusement, but she evidently had not thought much of this occurrence at the time or since. To the left of the sternum the second and third costal cartilages are missing, the corresponding ribs ending abruptly in a space about the size of a florin. The fourth rib, though in approximation to this cartilage, is not joined to it; the sternum presents a small notch about on a level with what would correspond to the third interspace. During inspiration this space becomes retracted, and during expiration it is bulged. The heart's impulse is very readily perceived in it, but the thymus cannot definitely be felt; the percussion note over it is impaired, and the breathing weak, and during expiration somewhat coarse. The first three fingers are webbed up to the terminal phalanx, and the last two to the middle of the second phalanx, and these are again partially webbed to the other fingers.

Some ten years ago I had a child under observation with a precisely similar deformity occurring on the right side of the thorax, and when the child died I made a post-mortem examination, and found that the space where the cartilages were deficient was filled in by a fairly tough membrane; the lung beneath showed areas of collapse and of emphysema. In the hospital museum there is a drawing of a child aged six with a similar deformity.

IV.—*A case of Sinus in left Loin communicating with an abscess cavity in the posterior mediastinum.* By WALTER G. SPENCER, M.S. *Exhibited October* 28, 1892.

MR. SPENCER exhibited a girl æt. 10, in whom he feared the speedy onset of amyloid disease as the result of long suppuration, and he raised the question whether any active measures should now be undertaken. A year ago an abscess appeared and burst without causing pain, or producing any angular curvature or stiffness in the spine.

When first seen there was a small opening in the left loin just above the crest of the ilium, from which pus came freely.

In August the sinus was incised and traced up through the erector spinæ muscle in front of the twelfth rib, which was cut across through its neck. No cavity was reached, but the sinus was probed for two inches. The lumbar spine and the left thorax appear quite normal. As a cause of the abscess it is supposed that either disease of the dorsal spine is limited, or tubercular glands in the posterior mediastinum have broken down. There is daily a profuse discharge, the child is growing paler, and has already a waxen look. But to expose the sinus further, the necks of other ribs would have to be cut across, and the operation would be a dangerous measure without offering much prospect of success.

Addendum, July, 1893.—A further operation was undertaken, the neck of the eleventh rib was divided and a cavity reached which was found to extend from the ninth rib to the iliac crest, behind the diaphragm and in front of the lumbar muscles. This was stuffed with iodoform gauze and healed soundly.

V.—*A case of Extensive Fracture of right upper Maxilla.* By STORER BENNETT. *Exhibited November* 25, 1892.

F. M., a shop assistant æt. 19, was admitted to the Middlesex Hospital under Mr. Henry Morris in the middle of last July, suffering from extensive fracture of the right

upper maxilla, the result of an explosion of a portable fire-engine a few days previously.

The right upper jaw was torn from the attachment to its fellow and the parts above, and dislocated downwards and across the middle line to the left side. The outer wall of the antrum was torn away, and with the lateral canine and first bicuspid had been removed before I saw him. Two lower teeth were broken, the only injury which had occurred to the inferior maxilla.

When the patient came under my care a vulcanite splint was made to cover the palate, and held in position by fine tinned-iron wires, passing through holes in the splint and around the necks of the teeth. Numerous holes were drilled in the palatine portion of the splint, to allow of free irrigation, and to prevent collection of discharge.

The splint reduced the lateral dislocation, and it was left for the pressure of mastication to reduce the downward one.

The patient is still wearing the splint, and the parts have been restored to their normal position, the union seeming to be very firm.

VI.—*A case of Rhythmical Rocking Movements in a child.* By W. B. Hadden, M.D. *Exhibited November* 25, 1892.

THE patient was a female child, æt. 3 years and 9 months. When standing or sitting she swayed the body from side to side, but there were no movements on lying down. When she walked the body was moved in the way mentioned, and the weight was brought to bear alternately on each foot. When spoken to she could control the movements for a time, though she soon relapsed. The movements were worse when she was observed, but they would occur when she was alone.

Another child of the family, æt. 16 months, had lately taken to imitating the patient, and some of the neighbours' children had also been noticed to copy the movements.

The patient was a very intelligent child. There was a small infiltrated central ulcer on each cornea, which from the history appears to have existed eighteen months. It was thought that the movements became aggravated when the

eyes were worse. The swaying of the body, however, came on long before the affection of the eyes. The account was that when the child was twelve months old she used to sit in her chair and move from side to side, as though keeping time, when the piano was played. At first she only did this when she heard music, but later on it became a habit. She had a good ear for music, and sang in tune better than most children. I propose, when she is free from whooping-cough, to admit the child into the hospital, and treat her by prolonged rest in bed.

VII.—*A case of Rhythmical Movements of the lower Limbs in a child.* By W. B. HADDEN, M.D. *Exhibited November* 25, 1892.

THE patient was an intelligent female child, æt. 1 year and 9 months, who had been affected for five months when sitting, but not on lying down, standing, or walking. There were rhythmical movements, nearly constant, consisting in alternate flexion and extension of the lower part of the spine, combined with flexion and extension at the hips and knees. No cause was ascertained.

VIII.—*A case of Loose Body in the Elbow-joint, probably the separated capitellar epiphysis of the humerus.* By L. A. DUNN. *Exhibited November* 25, 1892.

WM. T., æt. 7 years, came under notice two years ago, having fallen down at school and injured his left elbow. The limb had been placed upon an angular splint, and when first seen some few days after the accident the joint was so swollen that the exact nature of the injury could not be determined. On the subsidence of the swelling a mass was discovered in the joint, which was moveable independently of the

bones, and was then considered to be the capitellar epiphysis of the humerus which had been separated by the injury.

The patient was kept under observation, and was exhibited at a meeting of the Clinical Society on November 25, 1892.

There is now a mass of bone situated between the head of the radius and the lower extremity of the humerus. It is somewhat disc-shaped, and measures 1¼ inches in diameter and ½ inch in depth, quite moveable apart from both humerus and radius, although more nearly connected with the latter. On a superficial examination it might be mistaken for a greatly expanded head of the radius, but upon careful manipulation the head of the radius can be felt to rotate quite naturally upon its inferior aspect, although it is widely overlapped by, and somewhat dwarfed by contrast with the mass.

On examining the lower end of the humerus, the internal epicondyle is found to hold the normal position to the olecranon process of the ulna, but on the outer side a prominence which appears to be the external epicondyle is about one third of an inch above its proper position.

As to the nature of the mass, I think that the original diagnosis of separated capitellar epiphysis is correct, since the mass has continued to grow, and not only so, but has taken on an independent irregular growth, as it certainly is now a good deal larger and different in shape from the corresponding portion of the other humerus. Perhaps this has been occasioned by the absence of the controlling influence of the parent bone.

Again, both radii are exactly the same length, and the radius rotates smoothly upon the mass, whereas when this is approximated to the lower end of the humerus, and moved to and fro, a sense of crepitus is produced; and further, the separation of the capitellar epiphysis would have checked the growth of the outer part of the lower end of the humerus, and thus the unduly high position of the external epicondyle would be accounted for.

As all the movements of the normal elbow can be perfectly performed no surgical interference is contemplated.

IX.—*A case of Myxœdema, treated with raw thyroid glands and fresh thyroid extract, in which severe constitutional symptoms developed under treatment.*

By W. PASTEUR, M.D. *Exhibited January* 27, 1893.

SARAH R., æt. 56, married; no children, but has miscarried four times.

The present illness dates from a severe fall from a window

FIG. 13.

Portrait of Sarah R. before treatment.

seventeen years ago. She was treated at the London Hospital for her injuries. Her head was shaved and she states that the hair never grew properly after that. She has never felt well since this accident. On two subsequent occasions she

was treated at St. Bartholomew's Hospital for "affections of the throat," but was not permanently cured. She was in Westminster Hospital three or four years ago with well-marked myxœdema.

She was admitted to the Middlesex Hospital on October 12, presenting very typically the symptoms and aspect of advanced myxœdema. The characteristic alterations of expression, speech, gait, skin, sensation, &c., were unusually well marked. She weighed 8 st. 13½ lbs. During the first twelve

FIG. 14.



Portrait of Sarah R. after treatment.

days before treatment was begun she passed on an average 47 oz. of clear, pale, non-albuminous* urine daily, containing

* The urine contained traces of albumen on several occasions during treatment.

290—300 grains of urea (estimated daily by Squibb's apparatus). Her general condition was fair. She slept well, was not disturbed by dreams, and had a fair appetite. She was, however, liable to attacks of faintness on over-exertion. She was seized in this way on the 23rd after chapel. She fainted again after being put to bed, and became rigid for a while as the syncope passed off.

The pulse was generally slow—about 60—it was not appreciably altered during the syncopal attacks.

The thyroid feeding was begun on October 24, when she took one lobe of a very small gland in a bread and butter sandwich.

On October 27 a whole gland—of average size—was taken in a similar way, and again on November 1 and November 4.

The patient objected strongly to these sandwiches, and could only be induced to eat them by much coaxing.

During the first eighteen days (October 24—November 11) after treatment was begun, the average daily quantity of urine passed* was 42 oz., *i. e.* some 5 oz. less per diem than before treatment. The average daily excretion of urea for the same period (calculated from sixteen observations) was 376 grains, or about 80 grains more than before treatment.

The fifth thyroid sandwich was taken on November 27, but owing to the recurrence of toxic symptoms (*vide infra*) the remedial agent was subsequently administered in the form of fresh extract suspended in infusion of cloves, on December 5, 9, 13, and 16.†

After the 4th of November the effects of treatment on the excretion of urine and urea became less marked. The average daily excretion of urea was below rather than above 300 grains, and was observed to fall much lower still towards the end of December, when the patient began to regain weight, and a very marked coincident general improvement in her condition was taking place.

The general results of treatment in this case correspond so closely with those already observed and recorded in others that they may be dismissed in a few words. Within eighteen

* These figures are only roughly approximate, as there was more or less incontinence of urine until December 12. The disappearance of this symptom was coincident with the amelioration in the mental condition of the patient.

† To prepare the extract a perfectly fresh gland was cut up into small pieces, and the more fluid portions pressed through a very fine wire sieve, after the addition of 30 drops of glycerine. From 80 to 100 drops of extract were thus obtained. The dose usually given was 25 drops. A fresh extract was prepared each time.

days—after only two and a half glands had been taken—there was a marked improvement in the looks and general bearing of the patient, and her speech was already described as "almost normal." Within three weeks the very rough skin on the backs of the hands and forearms had become soft and smooth, and within five weeks there was profuse desquamation of the skin of the hands and feet in large scales, and branny desquamation in other parts of the body. The growth of new hair was observed at the end of four weeks.

The temperature was modified by treatment in the usual way. The pattern of the chart became decidedly irregular—though without any large excursions, and the readings were on an average from 1° to 2° Fahrenheit higher than before treatment.

The pulse rate was also markedly affected, rising from 60 (before treatment) to about 100 and even higher.

There was a rapid loss of weight from 9 st. to 6 st. 5½ lbs., and it is worthy of note that the wasting continued at the rate of about ½ lb. a day for fourteen days after the cessation of treatment.

This rapid, and for some time uncontrollable, wasting is one of the constitutional symptoms to which I would draw attention. It was probably the direct result of the intolerance of stomach which supervened after taking four or five thyroid sandwiches. On two or three occasions the thyroid sandwich caused sickness and rather alarming heart failure, so much so that this method of administering the remedy was soon abandoned.

Another symptom of which the patient frequently complained was severe lumbar pain, and radiating pains in the upper dorsal spine and along the left arm principally. The first attack of this kind occurred after the second dose and passed off in about twenty-four hours. After the fourth dose, on November 4, the pains were more acute, radiating round from the back to the præcordia and along the left arm. She looked decidedly ill and had much difficulty in taking any food. In the course of the following day there were pains in the legs—left chiefly—and some tenderness about the ankle-joint. The attack was at the time thought to be rheumatic, or possibly influenza. The treatment was suspended temporarily and the patient gradually regained her usual health, although she continued to waste.

On November 27 another sandwich was given; she was sick almost directly and fainted. Within an hour she com-

plained of severe pain in the back, and her respiration became shallow and sighing. She was ill and depressed next day. The temperature rose to 100·4° within six hours of the onset. She recovered in the course of three or four days, but the pulse remained weak for some time. After this the freshly-prepared extract was substituted for the sandwiches. Five doses only were given—between December 5 and December 16. They were not followed by constitutional symptoms. Her general condition, however, remained very unsatisfactory during December, and she continued to lose weight and take nourishment badly until Christmas Day. After this she gradually regained weight and strength, and by the 11th January was able to sit up for a couple of hours.

We must conclude from the above that doses of the raw gland, which may be taken with impunity by some patients, may cause alarming symptoms in others. The history of this patient, taken in conjunction with the marked effects of the "poison" on the circulation—feebleness of heart's action, sighing respiration, &c.—suggest a flabby or possibly fatty state of the heart as a predisposing cause of the attacks.

It must be added, however, that in spite of the unsatisfactory condition of the patient during the treatment the results as regards the myxœdema compare favorably with other cases. It is worthy of mention that only *nine* doses of thyroid gland or extract were taken from first to last.

After leaving the hospital Sarah R., remained absent three months against advice, and when seen again had somewhat relapsed in every respect. She was given thyroid tabloids to take—one or two daily—and it is interesting to note that even with this minimal dose she again complained of feeling sick and faint and unable to eat.

X.—*A case of Myxœdema in a Male, treated by dried thyroid extract given by the mouth.* By Arthur T. Davies, M.D. *Exhibited January* 27, 1893.

J. M., æt. 45, married, clerk, noticed about five or six years ago that he began to have difficulty in walking, and that his legs ached on exertion; at the same time all his

movements began to get slower, and he observed that his face, and especially the eyelids and hands, became swollen, and that he felt awkward in his feet; speech also became slower about the same time, and he began to complain of chilliness, so that he was obliged to wear a great coat in summer; he has also noticed loss of power in the lower jaw; this, together with the looseness of teeth which took place in 1891, caused him much difficulty in eating. He suffered much from vertigo, and occasional inco-ordination of the legs, and for the past two or three years has complained of great dryness of the skin. During the same period he has noticed an increase in the bulk of his body. He states that his intellect is not altered, that his memory remains good, and that he is easy tempered, but that he has a great dislike to noise and crowds. His gums have bled profusely at times. His body was formerly very hairy, it is now devoid of hairs.

The patient presented on November 10, 1893, the aspect of hebetude, with a "full-moon" face, eyelids swollen, in a pearly œdematous condition, and raised with difficulty; there was present the characteristic high flush on the cheeks, the lemon-tinted aspect of forehead with few wrinkles, scanty hair on vertex. Eyebrows arched and hairs deficient, thickening of lips and of mucous membrane of mouth; tongue not altered. The teeth and gums are normal, speech slow and deliberate; voice montonous, skin of hands and feet very dry; thyroid not felt; patellar reflexes normal. Urine contained a slight trace of albumen. Temp. 97·2°. Weight, 10st. 6¾lbs. Complained of weakness; difficulty of exertion; giddiness, so that he always tries to keep close to the walls or railings. The man has been treated throughout as an out-patient at the Metropolitan Hospital. I began on December 5, 1892, to treat him with powders made from the thyroid gland by Mr. White of St. Thomas's Hospital, at the suggestion of Dr. Hector Mackenzie. I gave him a powder every other day at first, and then each day up to the present time. There has been a steady improvement. The œdematous condition masking the features has almost disappeared, so that the expression is much more natural; the eyes are more open, and the eyelids are more easily raised; the speech is more rapid and a feeling of warmth is felt throughout the body (the weather during treatment having been intensely cold); the skin of the hands is more supple and moist; he is more active and the temperature has become normal. The weight is now 9st. 8½lbs. as against 10st. 6¾lbs., so that he has lost nearly one

stone in about eight weeks. The patient also tells me that he is obliged to take in his truss by four or five holes (there is a right inguinal hernia) and this points to a decrease in his girth. His friends have remarked on the great alteration in his appearance. The powders have been taken once a day in beef tea, with no bad symptoms whatever.

XI.—*A case of Myxœdema treated by giving the dried thyroid extract by the mouth.* By Arthur T. Davies, M.D. *Exhibited January* 27, 1893.

Ada B., æt. 47, single, I exhibited at this Society on February 25, 1887, and her condition was then fully described. She has been constantly under my observation during the past six years, and I have noticed a gradual increase of her symptoms, with corresponding increase of the coarseness of her features and bodily bulk. I began giving her the dried thyroid extract in beef tea on November 17, 1892; she was ordered to take it each day. Her weight was then 14st. 11lbs. There has been a rapid improvement. Her face has become much more natural, having nearly lost the puffy, œdematous condition and characteristic flush; her eyelids are more easily opened, she can talk more easily, and breathe with greater comfort, as she feels as if a load had been taken off her chest. She can now sing and read aloud, which she has been unable to do for nine years, and, in spite of the intense cold, she has felt much warmer. Her hands have become smaller, and the skin much more supple and moist, and she feels very much more active and better. Her weight has fallen from 14st. 11lbs. on November 17, 1892. to 10st. 6¾lbs. at the present time, a difference of over four stone in ten weeks. She tells me that her friends hardly recognise her now. She has been treated as an out-patient throughout, but has been instructed to lie down for one hour after taking the powder.

XII.—*A case of Myxœdema, treated with the fried thyroids of sheep.* By JAMES CALVERT, M.D. *Exhibited January* 27, 1893.

E. L., æt. 49. Noticed twelve years ago that her hands, arms, feet, legs, and face were swelling, that her speech and movements were becoming slow.

Her memory has been failing during the last two years. She came to at my out-patient room in December, 1892, presenting all the usual characteristics of a well-marked case of myxœdema. Her weight was 11 st. 9 lbs. She was told to come to the hospital three times a week, and to eat on each visit half a fried thyroid.

No special instructions were given to the sister of the ward as to the cooking of the thyroids; she was simply told to fry them in such a manner as to be quite palatable to the patient.

She began her treatment on December 5, and continued it until January 19, except on three occasions, when headache and nausea prevented her appearance.

On January 19 she again complained of nausea, and the thyroids were discontinued until the 25th.

During these six weeks of thyroid treatment she has steadily improved, and she herself is very conscious of the improvement; her face is markedly less puffy, her speech and movement are more vigorous, her skin is no longer harsh and dry, and her weight taken on the 16th January was 10 st. 2 lbs.

Thus it appears that, in the treatment of myxœdema, the thyroids may be fried sufficiently to make them quite agreeable to the patient without destroying their usefulness.

XIII.—*Extroversion of Meckel's diverticulum.* By WILLIAM H. BATTLE. *Exhibited February* 24, 1893.

THE patient, a female child aged 1½ years, was under care at the Royal Free Hospital. She was a fairly well-nourished child, presenting a pear-shaped tumour at the umbilicus, which had been noticed since birth, but had since

increased somewhat in size. This tumour, about 1½ inches long, was covered with red, smooth mucous membrane, which readily bled on manipulation, and was joined to the skin at the umbilicus with a definite line. The free end of the projection was about the size of a cherry, the narrowest part that of half a cherry. At the extremity was an opening through which a probe could be passed a distance of 2 inches. There was slight, thin discharge with rather feculent odour from this opening, and some eczema of the skin near. The bowels acted normally. The size of the protrusion could be reduced only slightly by pressure; it increased when the child cried, and became more erect.

The subsequent history of this case is as follows:

On the 4th of April the child was placed under chloroform and, after careful cleansing of the projection and surrounding parts, the central canal was closed with a plug of cotton wool. An incision was made in the middle line for about 1½ inches from the base of the projection into the peritoneal cavity, and, after a piece of sponge had been placed inside to absorb any fluid that might escape, this incision was made to encircle the base of the projection outside its attachment, which was thus freed from everything but the portion of intestine from which it sprung.

The intestine and diverticulum drawn out of the abdomen were placed on sponges, the diverticulum divided about ¼ inch from the bowel, and the stump closed by invagination and the insertion of Lembert's sutures of silk. One or two small arteries required ligature in the divided diverticulum.

The wound was cleansed, closed with interrupted sutures, and dressed with antiseptic gauze, &c. The same evening the child had a temperature of over 101°; next day scarlet fever developed, she was transferred to the hospital at Haverstock Hill, where she died on the 13th April.

Dr. G. Mitchell Winter has courteously supplied me with the following notes:—"She had right-sided cellulitis, angina and convulsions this morning; apparently the abdominal condition had nothing to do with the death." At the post-mortem the abdominal wound was quite healed; there was a track of suppuration along one stitch. Peritoneum quite healthy, no adhesions; no abnormal injection of vessels. Wound healed on viewing from inside. Peritoneum of bowel where diverticulum had been removed apparently quite healthy. The distance of the site of the diverticulum for the ileo-cæcal valve was 10 inches.

The part removed consisted of the everted diverticulum, the serous surfaces in apposition outside the abdomen being irregularly but firmly adherent.

XIV.—*Dermatological case for diagnosis.* By Dr. A. H. Weiss Clemow, M.D. *Exhibited April* 28, 1893.

THE patient was a lady, 34 years of age, who presented an eruption of numerous discrete elevated papules, varying in size from a split pea to a farthing, distributed over both flexor and extensor surfaces of the hands and forearms, and feet and legs as far as the knee. Their first appearance was noted when travelling in Switzerland twelve years ago, and they were then thought to be due to insect bites. Since then they have gradually increased in number till the present time.

The papules are at first small and reddened; a vesicle usually forms in a few hours, and bursts, and this process may be repeated again and again. They are intensely irritable, especially in warm weather or in heated rooms. With time the induration, elevation and redness become intensified. The appearance of fresh papules on one limb is immediately followed by a similar development in the corresponding situation upon its fellow.

The eruption is always worse after nervous shock of any kind, over fatigue, or worry, and the patient, who is of a rheumatic constitution, thinks that acids and acid wines aggravate the irritation.

XV.—*Syphilitic Stenosis of Larynx treated by excision of one vocal cord.* By Ewen C. Stabb. *Exhibited April* 28, 1893.

W. M., æt. 37. Contracted syphilis nine years ago. Two years ago tracheotomy was performed at the Central London Throat Hospital for increasing dyspnœa, and since then the outer tube has never been removed.

Admitted to St. Thomas's Hospital, December 25, 1892, suffering from attacks of urgent dyspnœa for two days, and any attempt to remove tube brought on an attack. Chloroform was given and the tube removed. It showed considerable thinning and absorption, one portion being quite detached. A new tube was introduced, and, during the next few weeks, repeated attempts were made to dispense with it, but with no good result. Examinations of the larynx, kindly made by Dr. Semon, showed that the right cord was fixed in the cadaveric position, while the left moved only slightly.

February 10.—Chloroform given through Hahn's tube and thyrotomy performed. The alæ of the cartilage being held apart, all the cicatricial tissue in the right side of the larynx (representing both true and false cords) was removed with scissors and forceps. A large piece of necrosed cricoid was discovered and removed. Thyroid cartilage and wound sutured. Hahn's tube removed in twenty-four hours, and tracheotomy wound allowed to close. Fed for first twenty-four hours with nasal tube. Voice gradually returned and soon became as good as before operation. Left hospital well March 18.

I am much indebted to Mr. Clutton for kindly allowing me to treat this case, and bring it before the Clinical Society.

XVI.—*Case of Partial Excision of Larynx for Myxochondroma: patient wears an artificial larynx without reed and speaks well.* By J. W. Bond. *Exhibited April* 28, 1893.

PATIENT, a man of 48, in January, 1889, had adductor paresis of right vocal cord. In August, 1891, stertorous breathing came on. A mass of hard growth was seen in larynx, and external to right arytænoid. An operation was refused. In February, 1892, tracheotomy had to be hastily performed. Growth increased after this, patient lost weight, and by September, 1892, larynx was completely obstructed, so that the patient was voiceless; his health generally was failing. On September 30, 1892, the growth was removed at Golden Square Throat Hospital. It was found to measure 1¾ inches obliquely from before back, and the same from above down, and weighed 11½ drachms. It sprang from the

anterior surface of posterior part of cricoid cartilage, which was greatly enlarged and distended. The arytænoids, the cartilages of Wrisberg and Santorini, and part of the thyroid cartilages were all removed, also the true cords and most of the mucous membrane of the larynx. Patient made a rapid recovery, could eat solid food on the ninth day, and now speaks well with an artificial larynx without reed.

XVII.—*Rheumatic Inflammation of sheaths of tendons and of finger-joints.* By F. R. Walters, M.D. *Exhibited April* 28, 1893.

Male, æt. 34, butcher, under Dr. Redfern of Croydon. Had a severe attack of influenza at end of November, 1892, complicated in December with double pleurisy with effusion. There was at this time much delirium and prostration.

December 13.—Delirium gone, pleurisy gradually subsiding. Some thickening about hands, to which attention was called on January 26, 1893. This thickening involved finger-joints and palmar fascia or sheaths of flexor tendons of hand, causing inability to use hands, but no pain except on manipulation.

Treated by Drs. Redfern and Richardson of Croydon, at first with Pot. Iod., Bellad., and Lobelia; then (December 11) with Digitalis and "Bromidia;" then (March 24) with Pot. Iod. and Lin. Pot. Iod. c̄ Sapone; this improved the condition of hands.

Present condition.—Rheumatic nodules about finger-joints, thickening of left ulna near olecranon, and of right olecranon. A "ganglion" at back of each wrist. Palmar fascia irregularly thickened and indurated in each hand, limiting movements of fingers.

Pleural fluid reabsorbed. Respiratory condition good. Heart apex displaced outwards and downwards with harsh and reduplicated first sound at apex.

XVIII.—*Case of total Ablation of Scapula for Sarcoma. Patient shown thirty-one days after operation.* By C. H. Golding-Bird. *Exhibited April* 28, 1893.

ELIZA J., æt. 14, came under my care in Guy's Hospital on March 21, 1893. She presented a deformed appearance from the presence of a large globular tumour, occupying the site of the left scapula. The tumour was the size of an average cocoa-nut; the only normal part of the scapula that could be made out being the spine, and that only partially. It was clearly a sarcoma of the scapula; the skin was free over it, but the tumour could be felt round the axillary border of the scapula on its ventral surface. It extended upwards and forwards to the clavicle, to the outer third of which it was fixed.

The shoulder-joint movements were free, passively, in all directions, but actively they were only possible directly forwards and backwards; abduction was lost; the deltoid muscle was very wasted, and also the other muscles of the upper arm. The forearm was well nourished, and all its movements were perfect.

The whole history of tumour-growth, as also of slight scapular pain and increasing loss of shoulder power, was but two months; the week the girl was under observation there was a manifest increase in the size of the tumour.

I operated on March 28, making a T incision, the vertical part being over the middle of the growth, the horizontal being parallel with the upper border of the scapula. The skin flaps being rapidly reflected, a bluish and elastic tumour appeared; it was incised to confirm the diagnosis, and at once plugged with sponge to restrain the severe hæmorrhage. The growth was then removed; it had so perfectly taken the place of the scapula that the latter was hardly recognisable.

The spinal border was first freed, then the upper, and lastly the axillary; very little blood was lost, the vessels at the various borders being secured as soon as seen. The chief loss of blood was from the incision made into the growth itself. The shoulder-joint was opened by incising the capsule all round; the interior was healthy, but the growth being right up to the neck of the scapula, the glenoid cavity was

removed; the coracoid process, infiltrated also, broke off and was removed separately; the outer third of the clavicle, also involved in the growth, was removed.

Toward the end of the operation the child was faint; hot water was freely poured over the whole raw surface, the pulse and respiration at once improved, and oozing ceased. Iodoform was freely dusted over the surfaces, and the skin-flaps accurately adjusted; no drainage-tube was used.

Primary union occurred; on April 12 (the fifteenth day) the patient got up, and when I examined her on the twenty-fourth day after the operation the condition was as seen to-night (thirty-first day).

When dressed there is no deformity, the shoulder being kept up by the trapezius attached to the remainder of the clavicle. The natural upper edge of the trapezius is maintained, and is symmetrical with that on the right side. There is perfectly smooth movement of the head of the humerus, and, passively, the arm can be put anywhere; slight abduction of the arm (increasing with the recovery of the deltoid, which now is nearly the size of that on the right side) and good forward and backward movement can be actively produced. The child can use the arm for all ordinary purposes quite vigorously, and but for the inability to elevate it (except passively) she is hardly at all disabled.

XIX.—*A case of Nævus involving the whole of the right side.* By J. Fletcher Little, M.B. *Exhibited November* 25, 1892.

E. I., æt. 15, a patient at North London Hospital for Consumption. She is the fifth child of healthy parents; her father is very neurotic. Two brothers died in infancy, one from hydrocephalus. One brother, aged twenty-three, alive, suffers from cough. Four sisters alive; one, aged nineteen, has phthisis; one died, aged sixteen, from phthisis.

Mother states that she had a severe mental shock during pregnancy. Patient was a very "delicate" child till about

the age of ten. Patient was born with a diffuse nævus extending over nearly whole of right side of body, over right side of scalp and face, especially over right ear, right chest,

FIG. 15.

right arm, right side of abdomen, and back of right leg; none noticed on left side of body. During infancy nævus disappeared gradually from face and ear. About the age of

DESCRIPTION OF PLATE III,

To illustrate Dr. Fletcher Little's Case of Nævus.

The nævus is unilateral except over the sternum, where it slightly transgresses the middle line. It covers the right side of the neck and trunk and the right upper and lower extremities. For the greater part of its extent it is capillary. In the right axilla and over the right pectoral it is cavernous in character. The hypertrophy of the parts is shown by the accompanying table of measurements.

E. Burgess, fect

Danielsson & Co., lith.

seven the neck cleared, and improvement has been regular but slow since.

The nævus has not caused her much discomfort, except that during the winter the right side becomes numb and a "tingling" sensation is noticed. Patient is right-handed, and has not noticed any "paresis" of right side. Tactile sensation good over right side, but heat sensation seemed rather deficient. No catamenia. Right retinal vessels rather larger than on left side, but not to any marked degree; vision in right eye is good.

Since she first applied for treatment, 1892, there has been some improvement. Colour better and less blueness of patches.

At the end of May, 1893, noticed "stinging" sensations over outer surface and front of right hip and thigh. A few days later surface congested, and a "vesicular eruption" appeared of the nature of herpes. Pains in right lumbar region. Vesicles suppurated and scabs formed over them, which are now gradually loosening. Since this attack the nævus over the right thigh has faded.

Present condition.—Patient is a healthy, well-formed girl, good colour, brown hair; skin of parts not affected clear and elastic; bright and cheerful; neurotic temperament, but no hysteria.

Nævus now extends over right mammary region from clavicle to below nipple; is of a well-marked, dull red colour, blue on exposure; below nipple the colour fades, but still set colour to iliac crest; large tortuous veins run from nipple to axilla. In the axilla the colour is rather more marked, and the patches extend over the back, encroaching slightly over line of spines of vertebræ to left. On the right shoulder and upper arm the colour is well marked, fading about elbow, but better marked on wrist and back of hand, especially on radial side. Thigh and hip only slightly discoloured now, rather more colour in the lower leg and foot.

Urine normal.

Chest: Lungs and heart normal.

Measurements taken by Mr. Smale, House Surgeon.

Chest.—Level of axilla	Expiration	13 in.	Both sides.
	Respiration	14 in.	
		Right.	Left.
Arm.—Acromion to external condyle		11½ in.	11 in.
External condyle to styloid process of radius		9	8

	Right.		Left.
Arm.—Circumference at shoulder . . .	13 in.	...	13 in.
„ at axillary level . . .	9¾	...	8¾
„ above elbow . . .	7	...	7
„ below „ . . .	8	...	7½
„ at wrist . . .	5½	...	5½
From styloid process of radius to end of thumb .	4¾	...	4¾
„ „ „ to tip of middle finger	6¾	...	6¼

Circumference of hips round iliac crests equal.

Leg.—Length from iliac spine to external malleolus .	32 in.	...	30 in.
Circumference of thigh at gluteal level .	19	...	19
„ „ above patella .	11	...	11
„ of leg below tibial tubercle .	10½	...	10½
„ „ at ankle . . .	6¾	...	6¾
„ round heel . . .	11	...	11
„ round metatarso-phalangeal joint .	7½	...	7½

VALEDICTORY ADDRESS

DELIVERED AT THE

CLINICAL SOCIETY OF LONDON

BY

SIR DYCE DUCKWORTH, M.D., LL.D.,

MAY 26TH, 1893.

GENTLEMEN,—Before I formally declare this session closed, I beg leave to address to you a few remarks from this chair which I occupy to-night for the last time. Owing to the altered date of our annual meeting, I have had the honour of presiding over the fortunes of this Society for some months longer than any of my predecessors.

In reviewing very briefly the term during which I have been in office, I think I may safely affirm that the Society has continued to fulfil its purpose, and has shown signs of vigorous life. The attendances of members have been large, the contributions both of living specimens (as we call them) and of papers have been numerous, and in many instances of high importance.

In my opening address I ventured to denounce the modern tendency to pursue novelties in treatment too assiduously, and to let go the hold of well-approved methods. I had for my text at that time, the unseemly excitement which was rife in respect of Koch's vaunted method for the treatment of tuberculosis. That is but twenty-eight months ago, and I will ask you to-night what value you now attach to that method, and whether my remarks on the occasion referred to have, or have not, been justified by our experiences in that brief period.

My term of office has been signalized by the continued presence of influenza amongst us in an epidemic that has proved sadly disastrous, but which at last shows signs of passing away. We have noted many and varied features of this scourge, both in its course and in its sequelæ.

We have withstood in these happy islands an advancing wave of Asiatic cholera, which wrought sore havoc on the European continent, and which threatened us in several of our seaports. The enlightened and promptly applied methods of our public health department, in defiance of effete and discredited quarantine regulations, have been so far successful as to render us hopeful of again withstanding this plague, should it reappear, as it may, in the ensuing summer or autumn.

We have issued, as you are aware, the results of our committee's labours on the important question of the incubation periods of certain infectious diseases, and have thus sent forth to the medical world a volume which will not fail to confer renown on this Society for all time. The work of this committee extended over fourteen years, a period none too long for such an inquiry, if it was to be, as it indeed required to be, worthy of this Society, and its results dependable for daily reference. I may again refer to the special services rendered to this committee by its secretary and editor, Dr. Dawson Williams.

We have had the satisfaction to note further, during my tenure of office, that a means of combating that strange malady which was first and fully brought to our knowledge in this Society—myxœdema, has been introduced, which, so far as we have experience of it, encourages us to hope that a certain and quite remarkable alleviation of its symptoms is possible, and that, perchance, the progress of the disorder may be effectually stayed. This is surely a very fitting sequel to the earlier clinical studies of this malady encouraged by this Society; and the efficacy of this new therapeutic method may perhaps justify us in anticipating that future discoveries await us in respect of the treatment of some other diseases by measures somewhat akin to that so ably promoted by Dr. George Murray and other members of this Society.

I should like to add, lastly, that I have had reason to observe that some of our younger members are too chary of taking part in our discussions and debates. It is always becoming to be modest, but it is often stupid to be silent, and it is a common fault now-a-days to try and agree with every-

body, to have too little courage of one's convictions, and to be afraid to speak out. We need a little more friendly friction. This would be good for us, and I make bold to urge it.

You have elected to-night as my successor one whom we all respect and acknowledge as a master of the surgical art, one whose modesty, rectitude, and fearlessness are only equalled by his skill and kindness of heart. Mr. Hulke will, I feel sure, add lustre to the post he comes to fill.

It only remains for me to thank the Council, the Secretaries, and the members of this Society for their uniform courtesy and support during my tenure of office. My last wish is that this admirable Society may in the future, as it has done in the past, carry out the high ideal conceived for it a quarter of a century ago by its founders.

Gentlemen, I now declare this twenty-sixth session closed, and bid you all most cordially farewell.

Appendix to Dr. NEWTON PITT'S *Paper on Pseudo-Bulbar Paralysis, giving the post-mortem appearances.*

BY April 7 the patient had so far recovered some power of swallowing that he was able to take a little minced meat. He generally fed himself with an œsophageal tube.

April 10.—An attempt was made to see the larynx, but the mouth could only be partially opened, and when the tongue was held it contracted reflexly. The soft palate hung down, and it was not found possible to see the vocal cords.

On the 26th he went home, and took an œsophageal tube with which to feed himself. He improved slowly, and was able to feed himself with care with thickened food without the use of a tube. When thirsty he was obliged to use it.

May 23.—Within the last fortnight the patient had developed ascites, which had rapidly increased in quantity. The liver and spleen were still large and indurated. He was able to open his mouth an inch. He was able to give a single voluntary cough, which he could not do previously. He was readmitted under the care of Dr. Perry.

On May 27 Dr. Felix Semon kindly saw the patient, who succeeded in saying "Ah," which was the first sound, beyond a cough or grunt, he had uttered. The vocal cords moved normally.

On the night of May 30 the patient awoke with urgent dyspnœa. This soon passed off. On June 6 thirteen pints of fluid were drawn off from the abdomen. On the 21st twenty-one pints more were drawn off. He gradually became more feeble, and died, chiefly from his abdominal condition, on the 25th.

Although attempts were made to get him to talk, the only sound he could utter, beyond a grunt and a cough, was "Ah."

The inspection was made by Dr. Fawcett.

Lungs œdematous.

Liver, 73 oz. There were well-organised thrombi in some of the hepatic veins. Extremely tough. The anterior two thirds was nutmegged. There was a great excess of fibrous tissue in the portal areas, and two of the portal veins were thrombosed. The remaining portion was pale, tough, but not nutmegged. The surface was smooth and not granular.

Spleen, 29 oz., greatly enlarged and densely fibroid.

Kidneys, 12 oz., normal.

Brain: The arteries at the base of the brain were very atheromatous. There were numerous patches of fibroid thickening upon several of the larger branches of the middle and anterior cerebral and of the basilar arteries. The surface of the brain was free from any softening, ochreous deposit, or hæmorrhage. The meninges over the vertex were somewhat thickened and opaque.

The sulci in the following regions were wider than normal, and the adjacent convolutions correspondingly small:—On the left side the sulcus in front of the anterior cerebral convolution, the fissure of Rolando, and the upper part of the superior temporal fissure; on the right side the fissure of Rolando at its upper part. The upper part of the central convolutions and the posterior part of the second frontal were rather wasted. Everywhere the wasting was slight, not secondary to any softening, and would not have caused any definite symptoms.

The third frontal convolutions and the island of Reil on both sides were perfectly normal.

As the weather was very hot, and bodies were decomposing rapidly, the brain was hardened in spirit, and horizontal sections were cut a few days later, showing the following lesions. The only changes were areas riddled with small cavities due to old softening, and in places the perivascular spaces were dilated.

A. A section 1¼ inches from the vertex, passing along the upper surface of the corpus callosum, showed a patch of old softening over an area half an inch across. There were several small cavities, but no large one. The centre of the spot was 2¾ inches from the anterior extremity, and 1 inch to the right of the middle line.

B. A section a quarter of an inch lower showed on the right side three small cavities over an area three eighths by a quarter of an inch in the inner and posterior part of the

lenticular nucleus, and just extending into the internal capsule. This was rather posterior to the patch in section A, but continuous with it in the white matter. The perivascular spaces both posterior and external to this region were much dilated. On the left side there was a collection of small cavities, each about an eighth of an inch across, over an area half an inch by three eighths, lying chiefly in the internal capsule between the optic thalamus and the posterior extremity of the lenticular nucleus. The perivascular spaces external to the lenticular nucleus were much dilated.

C. A section along the upper edge of the middle commissure showed a group of cavities, over an area three eighths of an inch antero-posteriorly by one eighth wide, at the inner and posterior part of the left lenticular nucleus. There was a small slit due to old softening at the posterior part of the right lenticular nucleus, with dilatation of the perivascular spaces in the outer part of the nucleus.

D. A section through the white commissure showed at the level of the lamina terminalis, from before backwards, great dilatation of the perivascular spaces in the lenticular nucleus on the right side throughout, and on the left in the outer part.

The cerebral lesions, therefore, consisted of two patches of softening, that on the right side extending above the lenticular nucleus, and below lying in its inner and posterior part, extending into the middle of the posterior limb of the internal capsule.

On the left side the patch occupied the middle of the posterior limb of the internal capsule, and below extended into the posterior part of the lenticular nucleus.

The pons and medulla appeared to be quite normal, and were hardened in Müller's fluid. No descending degenerations were visible. There has not yet been time to complete the microscopical examination.

At Christmas the patient had an attack of right hemiplegia, by which the face was permanently paralysed, the arm for some weeks, and the leg hardly at all. He did not lose his consciousness, nor did he have any fits or muscular twitching. The lesion was therefore obviously a small one, and did not involve the cortex. The only places where the fibres for the face, arm, and leg run close to one another are in the lenticular nucleus, the posterior limb of the internal capsule, or lower down in the crus or pons. There were no symptoms pointing to either of the latter. Hence the len-

ticular nucleus or its neighbourhood was the probable site of the lesion. The second attack, affecting the left side of the body, was similar. Hence during the life of the patient it was pretty obvious that there were symmetrical lesions in or near the lenticular nucleus.

As the paralysis of the face and tongue persisted I rather expected that the lesion would be found involving the internal capsule at the anterior extremity of its posterior limb. This was, however, quite normal, and the part of the capsule affected was at the middle of this limb. The double lesion in the lenticular nuclei agrees with what has been found in other cases of this nature.

As Messrs. Horsley and Semon pointed out in 1889, a unilateral cerebral lesion does not produce any laryngeal paralysis, but they were able to produce a bilateral paralysis of the abductors of the vocal cords by a symmetrical cortical lesion on each side of the brain.

In the present instance the softening on the left side of the brain did not produce any aphasia, and the aphonia only arose as the softening took place on the right side, and intermitted several times on the day of onset. In each instance the power of speech returned unimpaired for a short time.

There can be no question that for many weeks the patient was unable to utter a sound. Unfortunately, during the same period, he was able to open his mouth so slightly that we could not see his larynx.

Possibly an attempt after he went home might have been successful. When he had returned he had improved so far that he could open his mouth an inch, and he could utter the sound "Ah," and Dr. Semon saw the vocal cords moving.

The case is therefore defective, owing to the absence of an observation of the vocal cords during the early period. There is no doubt in my own mind that the case corroborates the view put forward by Horsley and Semon as the result of their experiments.

INDEX.

PAGE

Abdominal aorta, thrombus in (W. H. Brown) 1

——— section, in case of perforating gastric ulcer (W. Lee Dickinson, M.B., and Warrington Haward) 179

ABERCROMBIE (John, M.D.), case of congenital deficiency of chest-wall 225

Ablation (total) of scapula for sarcoma (C. H. Golding-Bird) . 242

Abscess beneath the diaphragm in connection with perforating gastric ulcer (F. G. Penrose, M.D., and W. Lee Dickinson, M.B.) 72

——— (pulmonary) communicating with posterior mediastinum (A. Morison, M.D.) 189

Abscesses, psoas, fatal through renal complications (F. Lucas Benham, M.D.) 172

ACLAND (T. D., M.D.) and FISHER (C. H., M.D.), case of generalised vaccinia 114

Albuminuria, chronic, two cases of (Francis Hawkins, M.B.) . 216

ALLINGHAM (Herbert), gastro-enterostomy for cancer of pyloric end of stomach 158

——— intestinal obstruction of six weeks' duration; inguinal colotomy; removal of malignant growth from the inguinal incision; recovery 140

Aneurysm (traumatic) of external iliac artery (H. H. Clutton) . 7

Ankle-joint, two cases of complete erasion of (W Arbuthnot Lane) 15

Aorta, abdominal, thrombus in (W. H. Brown) 1

Aphasia, hemiplegia associated with, in typhoid fever (Francis Hawkins, M.B.) 50

Appendix, vermiform, uterine hæmatocele simulating acute inflammation of (Arthur E. Barker) 97

Artery, external iliac, traumatic aneurysm of (H. H. Clutton) . 7

PAGE

Balance-sheet xlvii

Barker (Arthur E.), subserous uterine hæmatocele, in a girl eleven years, simulating acute inflammation of the vermiform appendix; laparotomy; recovery 97

——— his method employed for treatment of case of fracture of patella (Herbert W. Page) 224

Battle (William H.), extroversion of Meckel's diverticulum . 237

Benham (F. Lucas, M.D.), case of psoas abscesses fatal through renal complications 172

Bennett (Storer), case of extensive fracture of right upper maxilla 226

Bond (J. W.), case of partial excision of larynx for myxochondroma; patient wears an artificial larynx without reed and speaks well 240

Bowels, hæmorrhage from, in typhoid fever (Francis Hawkins, M.B.) 50

Breast (cancerous), lymphatics, and glands, more effectual method of removal (W. Arbuthnot Lane) 85

Brown (W. H.), case of intestinal obstruction accompanied by thrombus in the abdominal aorta extending down the iliac vessels 1

Cæcum, case of excision of (W. Bruce Clarke) 200

Calvert (James, M.D.), a case of myxœdema treated with the fried thyroids of sheep 237

——— a case of subacute œdema of lung occurring above a diminishing pleural effusion 43

Cancer of pyloric end of stomach, gastro-enterostomy for (Herbert Allingham) 158

Carr (J. Walter, M.D.), case of double empyema; simultaneous drainage of the pleural cavities; recovery 29

Chest-wall, congenital deficiency of (John Abercrombie, M.D.) . 225

Cicatricial stricture of œsophagus (Frederic Eve) 11

Clarke (W. Bruce), case of excision of the cæcum, in which the two ends of the divided bowel were successfully united by a continuous silk suture 200

Clemow (A. H. Weiss, M.D.), dermatological case for diagnosis . 239

Clutton (H. H.), case of traumatic aneurysm of the external iliac artery in a boy six years of age 7

Colitis with ulceration, case of (A. W. Mayo Robson) 213

Colotomy, inguinal, for colitis with ulceration (A. W. Mayo Robson) 213

——— ——— for intestinal obstruction (Herbert Allingham) . 140

PAGE
Conjunctival membrane, uratic deposit in (T. D. Pryce) . . 70
Council, notice from v
——— officers and members during 1892 xvii
——— report of xlv
Cyst, pancreatic, case of (J. W. Hulke, F.R.S.) 36
Cystotomy (supra-pubic), vertical and transverse incision in (R. W. Parker) 88

Davies (Arthur T., M.D.), case of myxœdema in a male, treated by dried thyroid extract given by the mouth 234
——— case of myxœdema treated by giving the dried thyroid extract by the mouth 236
Day (Donald D.) [introduced by Howard Marsh], case of nephrolithotomy; large calculus 24
Dermatological case for diagnosis (A. H. Weiss Clemow, M.D.) . 239
Diaphragm, abscess beneath, in connection with perforating gastric ulcer (F. G. Penrose, M.D., and W. Lee Dickinson, M.B.) 72
Diaphragmatic hernia, case of (C. D. B. Hale, M.D., and J. F. Goodhart, M.D.) 105
Dickinson (W. Lee, M.B.) and Haward (Warrington), case of perforating gastric ulcer treated by abdominal section . . 179
——— and Penrose (F. G., M.D.), cases of abscess beneath the diaphragm in connection with perforating gastric ulcer . 72
Dislocation, dorsal, of head of femur, new operation for (W. Arbuthnot Lane) 118
Diverticulum (Meckel's), extroversion of (William H. Battle) . 237
Duckworth (Sir Dyce, M.D., LL.D.), case of inherited gout, with production of tophi at an early age 68
——— valedictory address 247
Dunn (L. A.), case of loose body in the elbow-joint, probably the separated capitellar epiphysis of the humerus . . . 228

Elbow-joint, loose body in (L. A. Dunn) 228
Electrolysis successful in case of macrocheilia (W. Arbuthnot Lane) 223
Empyema, double, case of (J. Walter Carr, M.D.) 29
Erasion (complete) of ankle-joint, two cases of (W. Arbuthnot Lane) 15
——— of hip-joint (C. B. Lockwood) 125
Eve (Frederic), case of cicatricial stricture of œsophagus; œsophagotomy for removal of impacted Symonds' tube; complete division of stricture; no recurrence two years after operation 11
Excision of cæcum (W. Bruce Clarke) 200

PAGE

Excision of head of femur (C. B. Lockwood) 125
——— (partial) of larynx for myxochondroma (J. W. Bond) . 240
——— of one vocal cord for syphilitic stenosis of larynx (Ewen C. Stabb) 239
Extroversion of Meckel's diverticulum (William H. Battle) . . 237

Femur, new operation for dorsal dislocation of head of (W. Arbuthnot Lane) 118
——— excision of head of (C. B. Lockwood) 125
Finger-joints, rheumatic inflammation of (F. R. Walters, M.D.) . 241
FISHER (C. H., M.D.) and ACLAND (T. D., M.D.), case of generalised vaccinia 114
FOX (T. Colcott, M.B.), two cases of generalised vaccinia . . 108
Fracture (extensive) of right upper maxilla (Storer Bennett) . 226
——— of patella, treated by Barker's method (Herbert W. Page) 224

Gall-stone, intestinal obstruction from (Robert Nairn) . . . 211
Gastric ulcer (perforating), cases of abscess beneath the diaphragm in connection with (F. G. Penrose, M.D., and W. Lee Dickinson, M.B.) 72
——— ——— ——— treated by abdominal section (W. Lee Dickinson, M.B., and Warrington Haward) 179
Gastro-enterostomy for cancer of pyloric end of stomach (Herbert Allingham) 158
Glands, lymphatics, and cancerous breast, more effectual method of removal (W. Arbuthnot Lane) 85
——— thyroid (fried), case of myxœdema treated with (James Calvert, M.D.) 237
——— ——— (raw), case of myxœdema treated with (W. Pasteur, M.D.) 230
GOLDING-BIRD (C. H.), case of total ablation of scapula for sarcoma; patient shown thirty-one days after operation . . 242
GOODHART (J. F., M.D.) and HALE (C. D. B., M.D.), case of diaphragmatic hernia in which death was caused by vomiting 105
Gout (inherited), case of (Sir Dyce Duckworth) 68

HADDEN (W. B., M.D.), case of rhythmical rocking movements in a child 227
——— case of rhythmical movements of the lower limbs in a child 228
Hæmatocele, uterine, simulating acute inflammation of vermiform appendix (Arthur E. Barker) 97
Hæmorrhage from the bowels in typhoid fever (Francis Hawkins, M.B.) 50

PAGE

HALE (C. D. B., M.D.) and GOODHART (J. F., M.D.), case of diaphragmatic hernia in which death was caused by vomiting . 105
HALL (F. de Havilland, M.D.), case of rhinolith 60
HANDFORD (H., M.D.), case of hyperplastic (obliterating) phlebitis or phlebo-sclerosis affecting the larger veins . . . 20
HAWARD (Warrington) and DICKINSON (W. Lee, M.B.), case of perforating gastric ulcer treated by abdominal section . . 179
HAWKINS (Francis, M.B.), two cases of chronic albuminuria, one of *twenty years'* and the other of *forty-three years'* duration; remarks on chronic albuminuria 216
——— case of hemiplegia in typhoid fever associated with aphasia; hæmorrhage from the bowels and purpura 50
HEATH (Christopher), on a bloodless method of removing the tongue 177
Hemiplegia associated with aphasia in typhoid fever (Francis Hawkins, M.B.) 50
Hereditary enlargement of spleen (Claude Wilson, M.D., and Douglas Stanley, M.B.) 163
Hernia (diaphragmatic), case of (C. D. B. Hale, M.D., and J. F. Goodhart, M.D.) 105
——— (ventral), conditions seen at operation for, five and a half years after laparotomy for tubercular peritonitis (R. Lawford Knaggs) 18
Hip-joint, erasion of (C. B. Lockwood) 125
——— surgery of (W. Arbuthnot Lane) 118
HULKE (J. W., F.R.S.), case of pancreatic cyst; exploratory laparotomy; enucleation impracticable; death from shock . 36
Hyperplastic (obliterating) phlebitis, or phlebo-sclerosis (H. Handford, M.D.) 20

Iliac artery (external), traumatic aneurysm of (H. H. Clutton) . 7
——— vessels, thrombus in abdominal aorta extending down (W. H. Brown) 1
Illustrations, list of xv
Inflammation (rheumatic) of sheaths of tendons and of finger-joints (F. R. Walters, M.D.) 241
Inguinal colotomy for colitis with ulceration (A. W. Mayo Robson) 213
——— ——— for intestinal obstruction (Herbert Allingham) . 140
Intestinal obstruction from gall-stone (Robert Nairn) . . . 211
——— ——— inguinal colotomy for (Herbert Allingham) . . 140
——— ——— accompanied by thrombus in abdominal aorta (W. H. Brown) 1

PAGE

Intestine (small), excision of cancerous stricture of (A. Roper, M.D., and W. Arbuthnot Lane) 40

Johnson (Raymond), lympho-sarcoma of tonsil; removal by external incision, with preliminary ligature of the external carotid artery 136

Knaggs (R. Lawford), the conditions seen at an operation for ventral hernia, five and a half years after laparotomy for tubercular peritonitis 18

Lane (W. Arbuthnot), case illustrating a more effectual method of removing a cancerous breast, lymphatics, and glands . 85

——— and Roper (Arthur, M.D.), excision of a cancerous stricture of the small intestines, from a case of complete obstruction of seventeen days' duration 40

——— cases illustrating a new operation for dorsal dislocation of the head of the femur and some points in the surgery of the hip-joint 118

——— two cases illustrative of an operation of complete erasion of the ankle-joint 15

——— case of macrocheilia successfully treated by electrolysis . 223

——— case of extensive nævus of the peritoneum 5

Laparotomy, exploratory, for pancreatic cyst (J. W. Hulke, F.R.S.) 36

——— for subserous uterine hæmatocele (Arthur E. Barker) . 97

Larynx, artificial (J. W. Bond) 240

——— partial excision of, for myxochondroma (J. W. Bond) . . 240

——— syphilitic stenosis of (Ewen C. Stabb) 239

Lead-poisoning cause of peripheral neuritis (W. Hale White, M.D.) 143

Ligament, broad, lipoma of (Frederick Treves) 101

Lipoma of broad ligament (Frederick Treves) 101

Little (J. Fletcher, M.B.), case of nævus involving the whole of the right side 243

Living specimens described by card . . . . . 223—246

Lockwood (Charles Barrett), sequel to a case of excision of the head of the femur and erasion of the hip-joint through the anterior incision, and with immediate and permanent closure of the wound 125

Loin, left, sinus in (Walter G. Spencer) 226

Loose body in the elbow-joint (L. A. Dunn) 228

Lung, subacute œdema of (James Calvert, M.D.) 43

Lymphatics, glands, and cancerous breast, more effectual method of removal (W. Arbuthnot Lane) 85

Lympho-sarcoma of tonsil (Raymond Johnson) 136

PAGE

Macrocheilia, case successfully treated by electrolysis (W. Arbuthnot Lane) 223
MAKINS (G. H.), note on the prognosis in cases of sacro-iliac disease 127
Malignant growth, cause of intestinal obstruction of six weeks' duration (Herbert Allingham) 140
Maxilla, right upper, extensive fracture in (Storer Bennett) . . 226
Meckel's diverticulum, extroversion of (William H. Battle) . . 237
Mediastinum, posterior, pulmonary abscess communicating with (A. Morison, M.D.) 189
——— ——— sinus in left loin communicating with abscess cavity in (Walter G. Spencer) 226
Members and officers of Council during 1892 xvii
——— of the Society xxi
——— honorary, of the Society xix
MORISON (Alexander, M.D.), case of pulmonary abscess communicating with the posterior mediastinum 189
Myxochondroma, partial excision of larynx for (J. W. Bond) . 240
Myxœdema treated with dried thyroid extract (Arthur T. Davies, M.D.) 234, 236
——— ——— ——— fresh thyroid extract (W. Pasteur, M.D.) . 230
——— ——— ——— fried thyroid glands (James Calvert, M.D.) 237
——— ——— ——— raw thyroid glands (W. Pasteur, M.D.) . 230

Nævus involving whole of right side (J. Fletcher Little, M.B.) . 243
——— of peritoneum, case of (W. Arbuthnot Lane) . . . 5
NAIRN (Robert) [introduced by the President], intestinal obstruction from gall-stone; operation 211
Nephrolithotomy, case of (Donald D. Day) 24
Neuritis, peripheral, two exceptional cases of (W. Hale White, M.D.) 143

Œdema (subacute) of lung (James Calvert, M.D.) 43
Œsophagotomy for removal of impacted Symonds' tube (Frederic Eve) 11
Œsophagus, cicatricial stricture of (Frederic Eve) . . . 11
Officers and members of Council during 1892 xvii

PAGE (Herbert W.), case of fracture of patella treated by Barker's method; bony union 224
Pancreatic cyst, case of (J. W. Hulke, F.R.S.) 36
Paralysis (pseudo-bulbar), case of (G. Newton Pitt, M.D.) . . 204
——— ——— post-mortem appearances (G. Newton Pitt, M.D.) . 250

PAGE

Paralysis (unilateral faucial) in two cases of peripheral neuritis, one septicæmic, the other caused by lead (W. Hale White, M.D.) 143

Parker (Robert William), on the relative merits of a vertical and of a transverse incision in supra-pubic cystotomy . . 88

Pasteur (W., M.D.), case of myxœdema, treated with raw thyroid glands and fresh thyroid extract, in which severe constitutional symptoms developed under treatment 230

Patella, fracture of, treated by Barker's method (Herbert W. Page) 224

Penrose (F. G., M.D.) and Dickinson (W. Lee, M.B.), cases of abscess beneath the diaphragm in connection with perforating gastric ulcer 72

Peripheral neuritis, two exceptional cases of (W. Hale White, M.D.) 143

Peritoneum, case of extensive nævus of (W. Arbuthnot Lane) . 5

Phlebitis (hyperplastic), or phlebo-sclerosis, affecting the larger veins (H. Handford, M.D.) 20

Phlebo-sclerosis, or hyperplastic phlebitis (H. Handford, M.D.) . 20

Pitt (G. Newton, M.D.), case of pseudo-bulbar paralysis, probably due to a lesion in each cerebral hemisphere (the patient had been exhibited as a "living specimen") 204

——— ——— ——— appendix (giving post-mortem appearances) 250

Presidents of the Society since its formation xviii

Prognosis in sacro-iliac disease (G. H. Makins) 127

Pryce (T. D.) [introduced by Sir Dyce Duckworth], case of uratic deposit in the conjunctival membrane 70

Psoas abscesses, fatal through renal complications (F. Lucas Benham, M.D.) 172

Pulmonary abscess communicating with posterior mediastinum (A. Morison, M.D.) 189

Purpura in typhoid fever (Francis Hawkins, M.B.) 50

Renal complications cause of death in case of psoas abscesses (F. Lucas Benham, M.D.) 172

Report of the Council xlv

Rheumatic inflammation of sheaths of tendons and of finger-joints (F. R. Walters, M.D.) 241

Rhinolith, case of (F. de Havilland Hall, M.D.) 60

Rhythmical rocking movements in a child (W. B. Hadden, M.D.) 227

——— movements of the lower limbs in a child (W. B. Hadden, M.D.) 228

PAGE

ROBSON (A. W. Mayo), case of colitis with ulceration treated by inguinal colotomy and local treatment of the ulcerated surfaces, with subsequent closure of the artificial anus . . 213
——— infusion (or transfusion) of normal saline solution in severe shock 154
ROPER (Arthur, M.D.) and LANE (W. Arbuthnot), excision of a cancerous stricture of the small intestine, from a case of complete obstruction of seventeen days' duration . . . 40
Rotation (axial) of wandering spleen (J. Bland Sutton) . . 46

Sacro-iliac disease, prognosis in (G. H. Makins) 127
Saline solution (normal), infusion or transfusion of, in severe shock (A. W. Mayo Robson) 154
Sarcoma, total ablation of scapula for (C. H. Golding-Bird) . . 242
Scapula, total ablation of, for sarcoma (C. H. Golding-Bird) . . 242
Septicæmia causing peripheral neuritis (W. Hale White, M.D.) . 143
Shock, severe, infusion or transfusion of normal saline solution in (A. W. Mayo Robson) 154
Sinus in left loin communicating with abscess cavity in posterior mediastinum (Walter G. Spencer) 226
Society, members xxi
——— ——— honorary xix
——— presidents since its formation xviii
SPENCER (Walter G.), case of sinus in left loin communicating with an abscess cavity in the posterior mediastinum . . 226
Spleen, hereditary enlargement of (Claude Wilson, M.D., and and Douglas Stanley, M.B.) 163
——— (wandering), axial rotation of (J. Bland Sutton) . . 46
Splenectomy, case of (J. Bland Sutton) 46
STABB (Ewen C.), syphilitic stenosis of larynx treated by excision of one vocal cord 239
STANLEY (Douglas, M.B.) and WILSON (Claude, M.D.), sequel to some cases showing hereditary enlargement of the spleen . 163
Stenosis (syphilitic) of larynx (Ewen C. Stabb) 239
Stomach (pyloric end), gastro-enterostomy for cancer of (Herbert Allingham) 158
Stricture (cancerous) of small intestine, excision of (A. Roper, M.D., and W. Arbuthnot Lane) 40
——— (cicatricial) of œsophagus (Frederic Eve) 11
Supra-pubic cystotomy, vertical and transverse incision in (R. W. Parker) 88
Surgery of hip-joint (W. Arbuthnot Lane) 118

PAGE

SUTTON (J. Bland), case of axial rotation of a wandering spleen; splenectomy; recovery 46
Symonds' tube (impacted), œsophagotomy for removal of (Frederic Eve) 11

Tendons, rheumatic inflammation of sheaths of (F. R. Walters, M.D.) 241
Thrombus in the abdominal aorta in case of intestinal obstruction (W. H. Brown) 1
Thyroid extract (dried) used to treat cases of myxœdema (Arthur T. Davies, M.D.) 234, 236
——— ——— (fresh) used to treat case of myxœdema (W. Pasteur, M.D.) 230
——— glands (fried) used to treat case of myxœdema (James Calvert, M.D.) 237
——— ——— (raw) used to treat case of myxœdema (W. Pasteur, M.D.) 230
Tongue, bloodless method of removing (Christopher Heath) . 177
Tonsil, lympho-sarcoma of (Raymond Johnson) 136
Tophi at an early age in case of inherited gout (Sir Dyce Duckworth) 68
Traumatic aneurysm of external iliac artery (H. H. Clutton) . 7
TREVES (Frederick), case of lipoma of broad ligament . . . 101
Typhoid fever, hæmorrhage from the bowels and purpura in (Francis Hawkins, M.B.) 50
——— ——— hemiplegia associated with aphasia in (Francis Hawkins, M.B.) 50

Ulcer (perforating gastric), cases of abscess beneath the diaphragm in connection with (F. G. Penrose, M.D., and W. Lee Dickinson, M.B.) 72
——— ——— ——— treated by abdominal section (W. Lee Dickinson, M.B., and Warrington Haward) 179
Uratic deposit in conjunctival membrane (T. D. Pryce) . . 70
Uterine hæmatocele simulating acute inflammation of vermiform appendix (Arthur E. Barker) 97

Vaccinia, generalised (T. Colcott Fox, M.B.) 108
——— ——— (T. D. Acland, M.D., and C. H. Fisher, M.D.) . 114
Valedictory address (Sir Dyce Duckworth, M.D., LL.D.) . . 247
Ventral hernia, conditions seen at operation for, five and a half years after laparotomy for tubercular peritonitis (R. Lawford Knaggs) 18

PAGE

Vermiform appendix, uterine hæmatocele simulating acute inflammation of (Arthur E. Barker) 97

Vocal cord, excision of, for syphilitic stenosis of larynx (Ewen C. Stabb) 239

Vomiting cause of death in case of diaphragmatic hernia (C .D. B. Hale, M.D., and J. F. Goodhart, M.D.) 105

WALTERS (F. R., M.D.), rheumatic inflammation of sheaths of tendons and of finger-joints 241

WHITE (W. Hale, M.D.), two exceptional cases of peripheral neuritis, one septicæmic, the other due to lead, and presenting unilateral faucial paralysis and other rare symptoms . . 143

WILSON (Claude, M.D.) and STANLEY (Douglas, M.B.), sequel to some cases showing hereditary enlargement of the spleen . 163

PRINTED BY ADLARD AND SON,
BARTHOLOMEW CLOSE, E.C., AND 20, HANOVER SQUARE, W.

41B
38+